Volume 95 Number 3 Jul-Sep 2025 ISSN: 0018-0092 | e-ISSN: 1868-8845

Official Journal of the Hellenic Surgical Society

Hellenic Journal of Surgery



www.hjs.gr

Hellenic Journal of Surgery

Official Journal of the Hellenic Surgical Society

Volume 95, Number 3, Jul-Sep 2025 ISSN: 0018-0092 | e-ISSN: 1868-8845

Editor - in - Chief

Nikolaos I. Nikiteas, *Athens, Greece*

Co - Editor

Dimitrios Dimitroulis, *Athens, Greece*

Associate Editors

Stylianos Kykalos, *Athens, Greece*
Nikolaos Machairas, *Athens, Greece*
Dimitrios Schizas, *Athens, Greece*
Gerasimos Tsourouflis, *Athens, Greece*

Managing Editor

Maximos Frountzas, *Athens, Greece*

Advisory Board

Stamatios Angelopoulos, *Thessaloniki, Greece*
Nikolaos Arkadopoulos, *Athens, Greece*
Eelco de Bree, *Heraklion, Greece*
Emmanouil Chrysos, *Heraklion, Greece*
Eleni I. Effraimidou, *Alexandroupolis, Greece*
Evangellos Felekouras, *Athens, Greece*
Ioannis Galanis, *Thessaloniki, Greece*
Georgios Glantzounis, *Ioannina, Greece*
Apostolos Kamparoudis, *Thessaloniki, Greece*
Anastasios Karayiannakis, *Alexandroupolis, Greece*
Isaak Kesisoglou, *Thessaloniki, Greece*
Christos Klonaris, *Athens, Greece*
Manousos Konstadoulakis, *Athens, Greece*
Konstantinos Koutsopoulos, *Rhodes Island, Greece*
Ioannis Maroulis, *Patras, Greece*
Evangellos Menenakos, *Athens, Greece*
Antonios Michalopoulos, *Thessaloniki, Greece*
Dionysios Mitropoulos, *Athens, Greece*
Michail Mitsis, *Ioannina, Greece*
Vassilios Papadopoulos, *Thessaloniki, Greece*
Basileios Papaziogas, *Thessaloniki, Greece*
Despoina N. Perrea, *Athens, Greece*
Emmanouil Pikoulis, *Athens, Greece*
Michail Pitiakoudis, *Alexandroupolis, Greece*
Alexandros Polychronidis, *Alexandroupolis, Greece*
Nikolaos Roukounakis, *Athens, Greece*
Spiros Stavrianos, *Athens, Greece*
Konstantinos Tepetes, *Larisa, Greece*
Dimitrios Theodorou, *Athens, Greece*
Konstantinos G. Toutouzas, *Athens, Greece*
Georgios Tsoulfas, *Thessaloniki, Greece*
Georgios Tzovaras, *Larisa, Greece*
Dimitrios Zacharoulis, *Larisa, Greece*
Georgios K. Zografos, *Athens, Greece*
Georgios N. Zografos, *Athens, Greece*

OWNER: HELLENIC SURGICAL SOCIETY, 1 Artis St., 115 23 Athens, Greece
SECRETARIAT: e-mail: editorialoffice@hjs.gr
PRODUCTION: TECHNOGRAMMA*med*, 380, Messogion Ave., 153 41 Athens - Greece, Tel.: +30 210 6000643, e-mail: info@technogramma.gr

Hellenic Journal of Surgery

Official Journal of the Hellenic Surgical Society

Volume 95, Number 3, Jul-Sep 2025 ISSN: 0018-0092 | e-ISSN: 1868-8845

Editorial Board

Konstantinos Alexiou, *Athens, Greece*
Fotios Archontovasilis, *Athens, Greece*
Nikolaos Charalampakis, *Athens, Greece*
Grigorios Chatzimavroudis, *Thessaloniki, Greece*
Dimitrios Damaskos, *Edinburgh, UK*
Dionysios Dellaportas, *Athens, Greece*
Vasileios Drakopoulos, *Athens, Greece*
Dimitrios Filippou, *Athens, Greece*
Zoe Garoufalia, *Florida, Miami, USA*
Maria Gazouli, *Athens, Greece*
Orestis Ioannidis, *Thessaloniki, Greece*
Christos Iordanou, *Piraeus, Greece*
Meletios Kanakis, *Athens, Greece*
Emmanouil Kapetanakis, *Athens, Greece*
Michail V. Karamouzis, *Athens, Greece*
Nikolaos Karydis, *Patras, Greece*
Athanasios Katsargyris, *Athens, Greece*
Aristotelis Kechagias, *Hämeenlinna, Finland*
Christos Kontovounisios, *London, UK*
Ioannis D. Kostakis, *London, UK*
Ioannis Koutelidakis, *Thessaloniki, Greece*
Sofoklis Lanitis, *Athens, Greece*
Konstantinos Lasithiotakis, *Heraklion, Greece*
Ioannis I. Lazaridis, *Zurich-Schlieren, Switzerland*
Andreas Lazaris, *Athens, Greece*
Georgios Lianos, *Ioannina, Greece*
Evaggelos Lolis, *Volos, Greece*
Orestis Lyros, *Leipzig, Germany*
Styliani Mantziari, *Lausanne, Switzerland*
Konstantinos Mavrantonis, *Athens, Greece*
Evangelos Messaris, *Boston, USA*
Adamantios Michalinos, *Nicosia, Cyprus*
Nikolaos V. Michalopoulos, *Athens, Greece*
Konstantinos S. Mylonas, *Athens, Greece*
Konstantinos Nastos, *Athens, Greece*
Dimitrios Ntourakis, *Nicosia, Cyprus*
Dimitrios Papaconstantinou, *Athens, Greece*
Nikolaos Ptohis, *Athens, Greece*
Dimitrios A. Raptis, *London, UK*
Ioannis Rouvelas, *Stockholm, Sweden*
Nikolaos Sikalias, *Kalamata, Greece*
Georgios C. Sotiropoulos, *Athens, Greece*
Paris P. Tekkis, *London, UK*
Georgios Theodoropoulos, *Athens, Greece*
Maria Tolia, *Heraklion, Greece*
Diamantis I. Tsilimigras, *Ohio, USA*
Theodoros Troupis, *Athens, Greece*
Alexandra Tsaroucha, *Alexandroupolis, Greece*
Michail Vailas, *Athens, Greece*
Kyriakos Vamvakidis, *Athens, Greece*
Chrysovalantis Vergadis, *Athens, Greece*

Hellenic Journal of Surgery

Official Journal of the Hellenic Surgical Society

Volume 95, Number 3, Jul-Sep 2025 ISSN: 0018-0092 | e-ISSN: 1868-8845

CONTENTS

Original Article

Single-Site Laparoscopic Tenckhoff Catheter Insertion: Description of a novel two-port technique using conventional equipment 107

Muthukumaran Rangarajan, Mangalakumar Veeraswamy, Durairaju Arun Kumar

Reviews

Indocyanine Green Fluorescence Imaging in Colorectal Surgery: Applications, Limitations, and Future Perspectives 114

Elissavet Anestiadou, Efstathios Kotidis, Orestis Ioannidis, Angeliki Cheva, Christiana Chatzianestiadou, Savvas Symeonidis, Stefanos Bitsianis, Thomai Gamali, Manousos-George-Pramateftakis, Ioannis Mantzoros, Vasileios Foutsitzis, Nikolaos Ouzounidis, Stamatios Angelopoulos

Regenerative Therapies in Oral and Maxillofacial Surgery: Current Clinical Evidence 127

Marina Gkelsini, Elissavet Anestiadou, Orestis Ioannidis

The Role of Physiotherapy in Enhanced Recovery After Surgery for Lung Cancer: A Narrative Review 140

Eleni Paskalidi, Stella Miraka, Georgia Kamparoudi, Pagona Kamparoudi, Dimitrios Lytras, Paris Iakovidis, Ilias Kallistratos

Perspectives

Building an Accountable Centre of Excellence for Complex Pelvic Oncology: Beyond Centralisation 145

Christos Kontovounisios

Adipokines and Clinical Outcomes in Upper Gastrointestinal Cancer: Protocol for a Prospective Cohort Study 152

Adam Mylonakis, Konstantinos G. Toutouzas, Dimitrios Theodorou, Dimitrios Schizas

Hellenic Journal of Surgery

Official Journal of the Hellenic Surgical Society

Volume 95, Number 3, Jul-Sep 2025 ISSN: 0018-0092 | e-ISSN: 1868-8845

CONTENTS

Case Reports

Appendiceal Endometriosis Presenting as Acute Appendicitis: Successful Management with Laparoscopic Appendectomy 157

Panayiotis Antoniou, Giorgos Skouroumouni, Athanasios Bounovas, Maria Emmanouela Kopaka, Nikolaos Nikitakis

Lipofuscin Pigmentation of the Gallbladder: A Rare Case Report and Literature Review 162

Dimitra Smerdi, Panagiotis Stratigos, Mpoltetsou Eumorfia, Panagiotis-Akindynos Petrozellis, Sotiris Megalemos, Katsaounis Dionusios, Rallis Georgios

Original Article

Hell J Surg. 2025 Jul-Sep;95(3):107–113
doi: 10.59869/25071

Single-Site Laparoscopic Tenckhoff Catheter Insertion: Description of a novel two-port technique using conventional equipment

Muthukumaran Rangarajan[1], Mangalakumar Veeraswamy[2], Durairaju Arun Kumar[3]

[1]MS, FRCS (Glasg), DipMIS (France), FACS (USA), Consultant Surgeon, Doctors Hospital Health System, Nassau, Bahamas
[2]MD, MRCP, FEBS, PhD, Consultant Nephrologist, Kovai Medical Centre, Coimbatore, India
[3]MD, FRCA, Consultant Anaesthesiologist, Kovai Medical Centre, Coimbatore, India

ABSTRACT

Background: Conventional laparoscopic peritoneal dialysis catheter insertion is well established. The existing reduced-port techniques of catheter insertion described in the literature have both benefits and disadvantages. Hoping to address all the shortcomings while still maintaining reduced ports, we describe a novel technique used for the successful peritoneal catheter insertion in a series of patients using two laparoscopic ports via a single site (umbilical). **Materials and Methods:** In this prospective study, we included 41 patients with end-stage renal failure requiring renal replacement therapy via peritoneal catheter in our tertiary care hospital from 2015 – 2020. Our technique involves inserting a peritoneal catheter using two laparoscopic ports (one 5-mm and one 10-mm) inserted via two small incisions within a single site (umbilicus). **Results:** Parameters like age, sex, operative time (46 minutes; range 34 – 58), hospital stay, pain score and long-term catheter survival (75-92%) were analysed. Early complications (<30 days) rate was 7% and included peritonitis, bowel perforation, bleeding, wound infection, leakage, blockage and late complications (>30 days) were 10% and included exit-site infection, tunnel infection, cuff protrusion, outflow failure, and dialysate leaks or port-site hernias were also analysed. Follow-up was 25-72 months. We compared our outcomes with the various techniques of reduced port surgery described in the existing literature. **Conclusion:** In our method, we performed adhesiolysis wherever necessary, catheter introduction under direct vision, accurate catheter placement, catheter fixation, catheter patency testing and omentopexy. This technique was also successfully applied to redo surgeries with good outcomes. Our technique accomplished PD catheter insertion without compromising the basic principles of PD catheter placement, with added benefits of less pain and superior cosmesis.

Key words: *Laparoscopy; reduced port; single site; Tenckhoff catheter; peritoneal dialysis*

INTRODUCTION

In 1968, Henry Tenckhoff developed the indwelling peritoneal catheter, which was inserted through an open surgical technique [1]. However, it was Popovich and Moncrief in 1976 that popularised peritoneal dialysis (PD) by developing the concept of a continuous ambulatory peritoneal dialysis (CAPD) [2]. In recent times, the introduction of the percutaneous and later the laparoscopic technique was a major improvement in the insertion of PD catheters [3,4]. Even though the three main techniques for PD catheter insertion are open surgical, percutane-

Corresponding author:
Dr. Muthukumaran Rangarajan, Doctors Hospital Health System
1 Collins Avenue, Nassau, Bahamas
Tel.: +1-242-302-3257, +1-242-806-2601
e-mail: rangy68@gmail.com

Submission: 07.07.2026, Acceptance: 09.09.2026

ous Seldinger and laparoscopic techniques, the ideal technique is still debated. Over the last two decades, the laparoscopic technique has become more popular, which not only allows accurate placement of the catheter but also the ability to perform adhesiolysis, catheter fixation and omentopexy. It also provides good cosmesis, less pain and shorter hospital stay compared to the open approaches [5,6]. More recently, laparoscopic reduced port techniques of PD catheter insertion have been reported [7-11]. Herewith, we describe another novel technique of a laparoscopic two-port single-site Tenckhoff catheter placement that promises superior cosmesis and less pain without compromising surgical principles and patient safety. A brief commentary on the published literature describing various modifications of reduced port surgery for PD catheter insertion is also included.

MATERIALS AND METHODS

In this study, we included 41 patients with end-stage renal failure requiring renal replacement therapy via peritoneal catheter in our tertiary care hospital from 2015 – 2020. These patients were primarily managed by a single nephrology unit headed by a consultant. We excluded patients who were unfit for general anaesthesia or those who had abdominal hernias. All the surgeries were performed by a single surgeon with a sound knowledge of laparoscopic single site/reduced port surgeries. Initial experience in this technique was obtained from the surgeon performing procedures with the gynaecology team for benign gynaecological conditions for over 10 years. The relevant paperwork, including Ethics Committee approvals, was completed and the patients were prepared for surgery.

Surgical technique

All the patients were given staphylococci eradication via nasal mupirocin application and also underwent bowel preparation the previous night. The single-site surgical technique was explained to them and the relevant consents were signed.

The patients were placed in the supine position and endotracheal intubation/general anaesthesia was induced. Prophylactic antibiotics (IV Vancomycin + Ceftriaxone) were administered in all patients as per our protocol. Pneumoperitoneum was achieved via a Veress needle, which was inserted through a 2-mm stab incision in the umbilicus. For redo surgery in the three patients, the Veress needle was placed in the upper-left quadrant of the abdomen (Palmer's point). After creating a pneumoperitoneum of 12 mmHg, a No. 11 scalpel was used to make a 1-cm incision at the cephalic end of the umbilicus to accommodate a 10-mm trocar. Another 5-mm trocar was placed via a 5-mm incision in the caudal end of the umbilicus (Figure 1). It should be noted that there is always a 3-mm skin bridge between the two trocars to prevent gas leakage. In some cases, due to an introverted or small-sized umbilicus, the two incisions may spill out of the confines of the umbilicus by 3 – 4 mm. In this technique, the 10-mm trocar for the 30-degree laparoscope was always placed in the cephalic end of the umbilicus and the 5-mm port for instruments was placed at the caudal end of the umbilicus. For optimum utilisation using this particular technique and port position, the telescope and instrument must be moved in tandem, and never independent of each other.

The patient was now placed in a Trendelenburg position and a diagnostic laparoscopy was performed with a 10-mm 30° scope. The 5-mm trocar was used to introduce instruments to achieve adhesiolysis if necessary, catheter placement, catheter fixation and omentopexy. A double-cuffed straight-tip Tenckhoff PD catheter was then introduced through a 2-mm stab incision in the midline about 4 cm caudal to the umbilicus under direct vision. The subcutaneous cuff lay just under the skin and the peritoneal cuff was placed at the entry point of the catheter into the peritoneal cavity, which was verified with the scope. After ensuring no torsion had occurred, the tip was placed in the true pelvis. The catheter was secured to the abdominal wall by a No. 1 silk thread using a cobbler needle. The distal cuff of the PD catheter should be outside the peritoneum in the preperitoneal space or between both the rectus sheaths. A 3-mm stab incision was made in the left lateral abdominal wall, taking care to

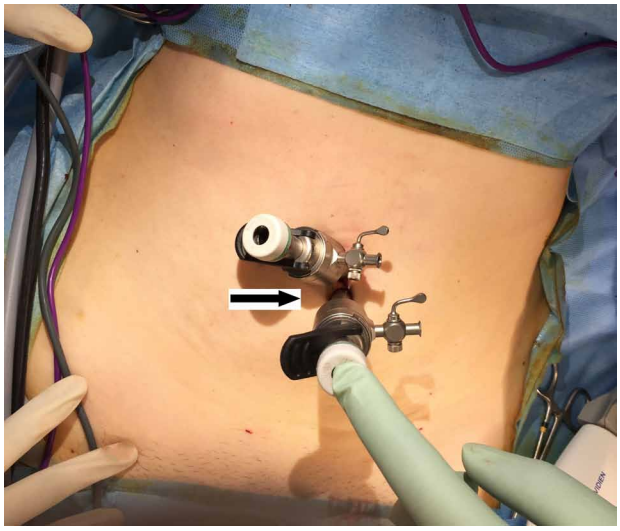

FIGURE 1. The two trocars placed within the umbilical area (arrow).

avoid damage to the inferior epigastric vessels. A blunt-tipped laparoscopic instrument was used to create the subcutaneous tunnel (Figure 2). The proximal cuff should lie in this tunnel. Next, the scope was directed to the left upper quadrant and the omentum was tethered to the anterior abdominal wall using the cobbler needle (Figure 3). Among the 41 patients, only two females required adhesiolysis because of a bowel adhesion from previous Caesarean section.

In the three redo patients with the catheter blockage:

i) the catheter was freed from the small bowel (Figure 4)
ii) the catheter was dissected out from the omentum (Figure 5)

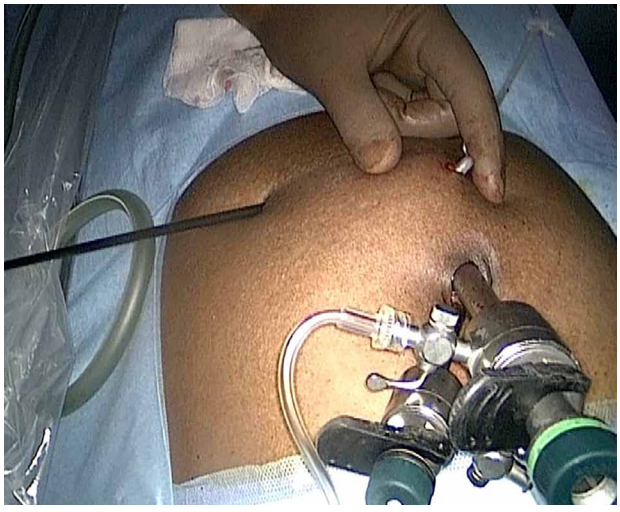

FIGURE 2. A blunt-tipped laparoscopic instrument creating a subcutaneous tunnel.

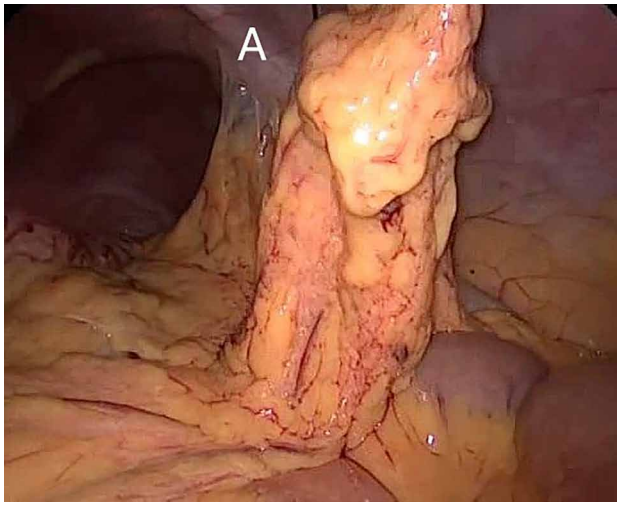

FIGURE 3. Omentum is tethered to the anterior abdominal wall (A – left costal margin), far away from the catheter tip.

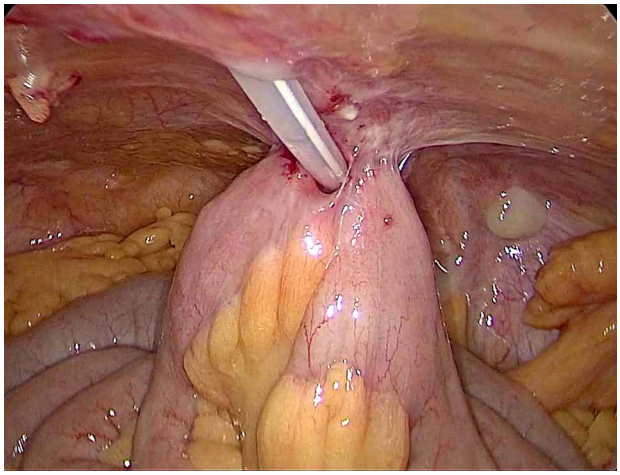

FIGURE 4. Small bowel adhesions being dissected from the catheter.

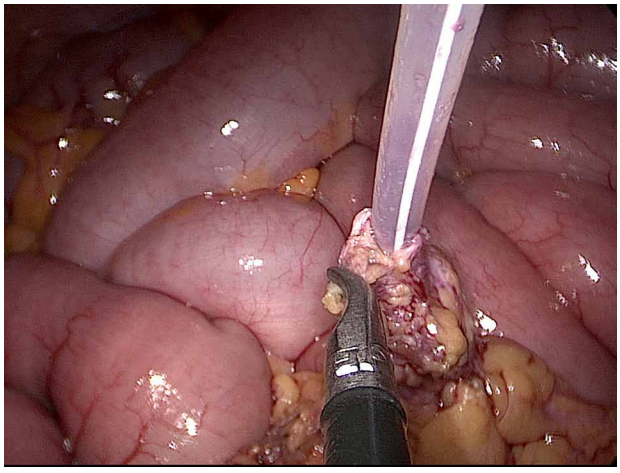

FIGURE 5. Omentum being cleared from the catheter tip.

iii) the catheter was then freed from the appendix epiploicae (Figure 6) and returned to the true pelvis.

In the one patient with catheter migration:

i) The catheter tip was relocated to the true pelvis and fixed to the abdominal wall with a No.1.0 silk.

The catheter patency was then tested with saline and the pneumoperitoneum was released, with the camera still in position to check the location of the catheter during desufflation. The trocars were removed and the rectus sheaths were closed with absorbable sutures. The two wounds were closed with skin glue (Figure 7). The application of the dialysis catheter two weeks after placement was defined as "early usage" and after two weeks as "late usage." We prescribed mild laxatives to all our patients to avoid constipation and thereby potential catheter blockage.

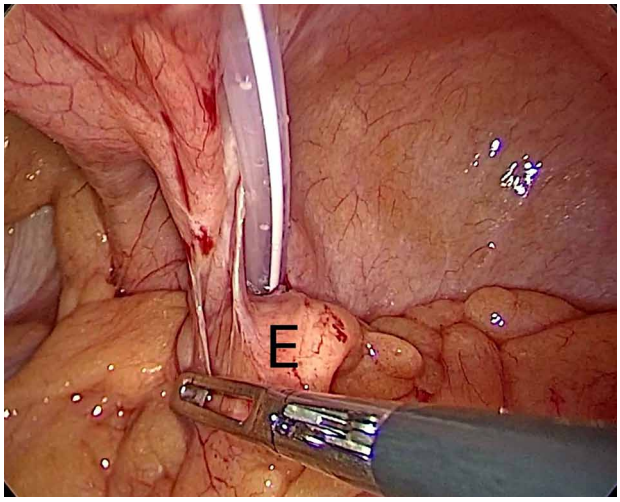

FIGURE 6. Catheter tip was freed from the appendix epiploicae (E).

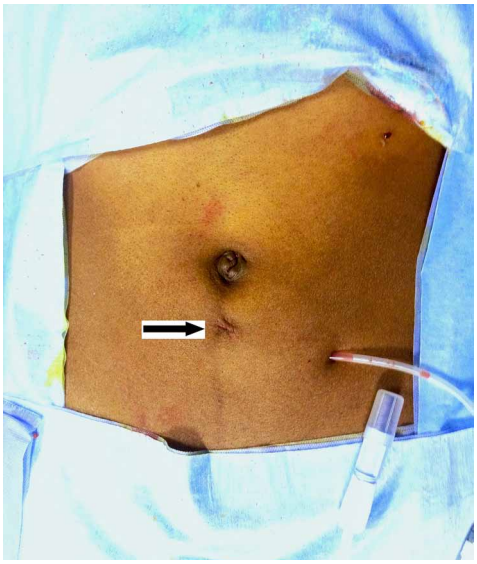

FIGURE 7. After procedure – incision sites within the umbilicus are barely visible; arrow points to the catheter tethered to the abdominal wall 2 inches inferior to the umbilicus.

RESULTS

In this prospective study, we analysed the data of the 41 patients that underwent insertion of a straight Tenckhoff peritoneal catheter from 2015 – 2020 using the novel two-port single site laparoscopic technique. We included 26 male patients (63%) and 15 female patients (37%). The average age was 56.5 years (range: 32 – 81 years) and average body mass index was 28.5 Kg/m^2 (range 23.2 – 33.5). The mean operative time was 46 minutes (range 34 – 58). There were no conversions to either the conventional multi-port or open approaches.

Pain assessment was done using **Numeric Rating Scale (NRS 11)**, where '0' indicates no pain, '5' denotes moderate pain and '10' indicates worst possible pain (Table 1). Pain was assessed during their hospital stay; one patient needed narcotics (oral hydromorphone 2.5mg thrice daily) while the others were managed with intravenous acetaminophen 4 g daily and celecoxib 400 mg twice daily. The mean follow-up period was 48.5 months (range: 25 – 72 months). Hospital stay was 24 hours in 38 patients and 48 hours in three patients. Start of dialysis for all patients after CAPD placement was two weeks, except for one female (five days) who needed an urgent start with low volume. Long-term catheter survival in our study was at 1, 2, 3, 4 and 5 years was 92%, 92%, 90%, 79% and 75%, respectively. Renal transplants were performed in 40% of patients 4-6 years after CAPD placement.

Early (<30 days) complications like peritonitis, bowel perforation, bleeding, wound infection, leakage, catheter blockage and late (>30 days) complications like exit-site infection, tunnel infection, cuff protrusion, outflow failure, and dialysate leaks or port-site hernias were analysed (Table 2). Three patients (7%) had early postoperative complications: two patients (5%) who had exit site infection, which was adequately treated with dressings and oral antibiotics for 10 days. One female patient had a dialysate leak from the exit site that was confirmed with a glucose test strip. This could be attributed to the urgent-start dialysis she underwent five days after CAPD placement. She was managed by a temporary suspension of dialysis and reducing the dialysate volume.

In our study, four patients (10%) presented with late complications (Table 2). They all required re-intervention and were performed using the same two-port single-site technique. There was one patient with a migrated catheter, the reason being the catheter was not anchored to the abdominal wall during the primary surgery. During the second procedure, the catheter tip was found to be engulfed by small bowel loops. The tip was then relocated to the true pelvis and fixed to the abdominal wall with a No. 1.0 silk. We had three patients with a blocked catheter:

TABLE 1. Numerical Rating Pain Scale.

Pain Score	0-3	4-6	7-9	10
Number of Patients (%)	31(76%)	9(22%)	1(2.4%)	0(0%)

TABLE 2. Postoperative Outcomes.

Early Complications: Number of Patients (%)	Late Complications: Number of Patients (%)
Dialysate leaks – 1 (2.4%)	Outflow failure (blocked catheter) – 3 (7%)
Exit site infection – 2 (5%)	Catheter migration – 1 (2.4%)
Peritonitis; Bowel perforation; Cuff protrusion; Blockage; Catheter migration; Bleeding – 0 (0%)	Exit-site infection; Dialysate leaks; Hernia; Catheter removal – 0 (0%)

one was due to sigmoid colon appendix epiploicae and the other two were due to omentum.

DISCUSSION

Based on the current evidence, it is safe to state that laparoscopic catheter placement is superior to the open method in terms of accurate placement, complication rate (especially peritonitis), catheter survival and pain [12-14]. Now that laparoscopy is well established, we set our sights on reduced-port PD catheter insertion, based on the experience gained with single-site surgery in other specialties. It must be appreciated that PD insertion using reduced number of ports translates into reduced port-related complications. Studies have shown that port-site complications include leakage (4-12%), abdominal wall haematoma or haemorrhage (5%) and port-site hernias (7%) [15-17]. Moreover, these complications contribute to almost 20% of the total mechanical complications that could potentially lead to catheter loss. Obviously, pain is also less with reduced-port surgery. Based on these facts, it is therefore pertinent to explore the option of a reduced-port or single-site surgery for PD insertion. The term 'reduced port' surgery denotes the utilisation of less than three ports, which is the minimum requirement for a standard laparoscopy. Serendipitously, a literature survey revealed no dearth of techniques and modifications of reduced-port laparoscopy for PD insertion since 2004. Our particular technique of PD insertion has not been previously reported.

Traditionally, the six cardinal principles of PD catheter insertion are described:

1. Adhesiolysis if necessary
2. Catheter introduction under direct vision to prevent bowel injury
3. Accurate catheter placement to prevent blockage
4. Catheter fixation to prevent migration
5. Catheter patency testing
6. Omentectomy or Omentopexy to prevent catheter blockage

Regardless of the technique of insertion, these 'six simple rules' must be adhered to. It is logical to conclude that any reduced port technique that adequately fulfils all these criteria would be ideal to emulate. We also reviewed published literature describing the various modifications of reduced-port surgery for PD catheter insertion and compared them with ours.

Harissis et al reported a one-port technique in 13 consecutive patients [18]. All their catheters were fixed in the abdominal cavity with no additional ports, but no omentopexy was described. Kao et al in their 2014 paper describe their technique of a single port PD insertion [19]. While this is certainly an ingenious approach, in our opinion, carries these drawbacks: omentopexy was not performed, the catheter tip position could not be visualised during desufflation, and redo procedures were not described – all of which were achieved using our technique.

Bıçakcı et al published an interesting paper, one of a very few comparing single port laparoscopic and open surgical access in children [20]. The catheter was not fixed in their method, though they used an optic bronchoscopy forceps to exteriorize the omentum and excised it extracorporeally. Ashegh et al reported a large series of 79 patients using a one-port laparoscopic PD catheter insertion in 2008 [21]. However, in their study the authors needed two extra ports to perform adhesiolysis. They fail to mention how omentopexy was performed with a single trocar. Yan et al describe a one-port technique but did not fix the catheter and did not perform omentopexy [22]. In our modification, even though we only use the two trocars through a single site, all the recommended steps of PD insertion can be performed with no difficulty – catheter introduction under direct vision to prevent bowel injury, adhesiolysis if necessary, accurate catheter placement to prevent blockage, catheter fixation to prevent migration and omentopexy to prevent blockage.

None of the reduced port techniques we reviewed describe their technique in redo surgeries. Our novel technique was used safely for redo procedures as well, with good outcomes. In the one patient who had the catheter trapped in the small bowel, the catheter was dislodged and replaced in the true pelvis. The patient who had his catheter blocked by the omentum was managed by disentangling and performing omentopexy. One patient whose catheter was obstructed by the appendix

epiploicae of the sigmoid colon was managed by fixing the appendix epiploicae to the lateral abdominal wall with a cobbler needle.

Ladd and Cao stressed on the importance of omentopexy in PD catheter insertion [23,24]. Omentectomy was performed in all patients in their study, though catheter survival rates were similar in both groups. We also believe omentopexy is enough to prevent complications due to catheter blocks by the omentum. In our series, omentopexy was not performed in the very first patient, who subsequently developed a catheter block. Thereafter, we started routinely adding an omentopexy for all patients resulting in zero incidence of blockage. More interestingly however, Cao et al also fix the sigmoid colon mesentery to the lateral abdominal wall to prevent it from blocking the catheter tip [24]. This was of special interest to us because we had one patient where the appendix epiploicae of the sigmoid colon obstructed the catheter outflow. This patient was treated successfully using our modified single-site technique. Ko et al also published a two-port technique, where one port is situated below the umbilicus and the other cleverly placed at the site of the PD catheter exit [25]. They performed adhesiolysis via an extra 3-mm port. However, they did not perform omentopexy or redo procedures with this technique. Even though our technique also involves two ports that are both located within the umbilicus, we could perform omentopexy and re-do procedures. It also allows the patient to have no visible scar.

Regarding the postoperative early and late complications, we compared our results with similar published reduced port techniques. We defined early and late complications using the 30-day mark, whereas other studies have used the six-week mark or six-month mark.

Pan et al reported a large study focusing on the outcomes of 263 patients that underwent a single-port laparoscopic placement [26]. Catheter occlusion was the most common early complications (<6 months) that occurred in 1.5% of patients. In our study, we had no leakage within four weeks. Late complications (> 6 months): catheter occlusion (1.9%), cuff extrusion (0.8%), catheter leakage (1.1%), catheter migration (1.1%), infection (2.3%) and hernia (1.5%). Late complications in our study were catheter block in 7% and catheter migration in 2.4% of patients. Catheter survival rate at 1, 2, 3, 4 and 5 years was 96%, 94%, 90%, 85% and 82%, respectively. Long-term catheter survival in our study was at 1, 2, 3, 4 and 5 years was 92%, 92%, 90%, 79% and 75% respectively.

Another paper by Milliken et al described a single-port laparoscopic insertion of peritoneal dialysis catheters along with partial omentectomy in children [27]. In this study, 45% catheters were used within four hours. Early complications included a minor leak that resolved within 24 h, one exit-site infection, one blockage due to a fibrin clot and one blockage after 2 weeks due to adhesions (not due to omentum). In our study, 0% of patients had blockage, 2.4% had early catheter leak and 5% had infection as early complications.

Liu et al have described a unique technique using a flexible endoscope to place and fix PD in pigs [28]. Here, a flexible endoscopic is used for extraperitoneal tunneling, which allows for minimally invasive single-incision PD catheter placement and fixation with endoscopic clips. It remains to be seen the reproducibility and cost-effectiveness of this technique, while human trials are awaited.

CONCLUSION

In conclusion, our new technique allows for 'no visible scar' surgery with minimal invasion yet accomplishing all the goals of adequate peritoneal catheter insertion. It may be effective in redo procedures as well. Our technique of two-port laparoscopic surgery via a single site for PD seems to be safe, reproducible, effective and cosmetically acceptable without compromising the relevant basic surgical principles. We hope that more surgeons will adopt this technique leading to larger studies that further validate the usefulness of this novel approach. Limitations of this study include a small, single-center, single-surgeon series, absence of a control group and possible learning curve effects. Future randomised trials comparing multiport laparoscopy versus single-site laparoscopy could be beneficial to determine a superior technique.

Approval by Ethics Committee: *Yes*

Conflict of Interest: *None declared*

Informed Consent: *Informed consent was obtained from all individual participants included*

REFERENCES

1. Tenckhoff H, Curtis FK. Experience with maintenance peritoneal dialysis in the home. Trans Am Soc Artif Intern Organs. 1970;16: 90–5.
2. Nolph KD. Remembering Robert Popovich, PhD. Perit Dial Int. 2012 Nov-Dec;32(6): 583–4.
3. Adamson AS, Kelleher JP, Snell ME, Hulme B. Laparoscopic placement of CAPD catheters: a review of one hundred procedures. Nephrol Dial Transplant. 1992;7(8):855–7.
4. Savader SJ, Geschwind JF, Lund GB, Scheel PJ. Percutaneous radiologic placement of peritoneal dialysis catheters: long-term results. J Vasc Interv Radiol. J Vasc Interv Radiol. 2000 Sep;11(8):965-70.
5. Soontrapornchai P, Simapatanapong T. Comparison of

open and laparoscopic secure placement of peritoneal dialysis catheters. Surg Endosc. 2005 Jan;19(1):137-9.
6. Cox TC, Blair LJ, Huntington CR, Prasad T, Kercher KW, Heniford BT, et al. Laparoscopic versus open peritoneal dialysis catheter placement. Surg Endosc. 2016 Mar;30(3):899-905.
7. García-Cruz E, Vera-Rivera M, Corral Molina JM, Mallafré-Sala JM, Alcaraz A. Laparoscopic placement of peritoneal dialysis catheter: description and results of a two-port technique. Nefrologia 2010;30(3):354-9.
8. Mir N. Two Port Laparoscopic Placement of Peritoneal Dialysis Catheter: Effective Technique. W J Lap Surg. 2012;5(3):146-9.
9. Losanoff JE, Basson MD, Gruber SA. One-port laparoscopic peritoneal dialysis catheter placement. Am J Surg. 2007 Aug;194(2):271-2.
10. Dalgic A, Ersoy E, Anderson ME, Lewis J, Engin A, D'Alessandro AM. A novel minimally invasive technique for insertion of peritoneal dialysis catheter. Surg Laparosc Endosc Percutan Tech. 2002 Aug;12(4):252-4.
11. Al-Hashemy AM, Seleem MI, Al-Ahmary AM, Bin-Mahfooz AA. A two-port laparoscopic placement of peritoneal dialysis catheter: A Preliminary Report. Saudi J Kidney Dis Transpl. 2004 Apr-Jun;15(2):144-8.
12. Chen Y, Shao Y, Xu J. The Survival and Complication Rates of Laparoscopic Versus Open Catheter Placement in Peritoneal Dialysis Patients: A Meta-Analysis. Surg Laparosc Endosc Percutan Tech. 2015 Oct;25(5):440-3.
13. Hagen SM, Lafranca JA, Steyerberg EW, Ijzermans JNM, Dor FJ. Laparoscopic versus open peritoneal dialysis catheter insertion: a meta-analysis. PLoS One [Internet]. 2013;8(2):e56351. Available from: https://pubmed.ncbi.nlm.nih.gov/23457554/
14. Jwo SC, Chen KS, Lee CC, Chen HY. Prospective randomized study for comparison of open surgery with laparoscopic-assisted placement of Tenckhoff peritoneal dialysis catheter–a single center experience and literature review. J Surg Res. 2010 Mar;159(1):489-96.
15. Strippoli GFM, Tong A, Johnson D, Schena FP, Craig JC. Catheter-related interventions to prevent peritonitis in peritoneal dialysis: a systematic review of randomized, controlled trials. J Am Soc Nephrol. 2004 Oct;15(10):2735-46.
16. Piraino B, Bailie GR, Bernardini J et al. ISPD Ad Hoc Advisory Committee. Peritoneal dialysis-related infections recommendations: 2005 update. Perit Dial Int. 2005 Mar-Apr;25(2):107-31.
17. Peppelenbosch A, van Kuijk WHM, Bouvy ND, van der Sande FM, Tordoir JHM. Peritoneal dialysis catheter placement technique and complications. NDT Plus. 2008 Oct;1(Suppl 4):iv23-iv28.
18. Harissis HV, Katsios CS, Koliousi EL, Ikonomou MG, Siamopoulos KC, Fatouros M, et al. A new simplified one port laparoscopic technique of peritoneal dialysis catheter placement with intra-abdominal fixation. Am J Surg. 2006 Jul;192(1):125-9.
19. Kao, CY, Chuang, JH, Lee, SY. A new simplified one-port laparoscopic technique for peritoneal dialysis catheter placement. Perit Dial Int. 2014 Jan-Feb;34(1):109–113.
20. Bıçakcı Ü, Genç G, Tander B, Günaydın M, Demirel D, Özkaya O, et al. Single port laparoscopic and open surgical accesses of chronic peritoneal dialysis in children: A single center experience over 12 years. J Minim Access Surg. 2016 Apr-Jun;12(2):162-6.
21. Ashegh H, Rezaii J, Esfandiari K, Tavakoli H, Abouzari M, Rashidi A. One-port laparoscopic technique for placement of Tenckhoff peritoneal dialysis catheters: report of 79 procedures. Perit Dial Int. 2008 Nov-Dec;28(6):622-5
22. Yan X, Zhu W, Jiang CM, Huang HF, Zhang M, Guo HQ. Clinical application of one-port laparoscopic placement of peritoneal dialysis catheters. Scand J Urol Nephrol. 2010 Nov;44(5):341-4
23. Ladd AP, Breckler FD, Novotny NM. Impact of primary omentectomy on longevity of peritoneal dialysis catheters in children. Am J Surg. 2011 Mar;201(3):401-5.
24. Cao W, Tu C, Jia T, Liu C, Zhang L, Zhao B, et al. Prophylactic laparoscopic omentopexy: a new technique for peritoneal dialysis catheter placement. Ren Fail. 2019 Mar;41(1):113–7.
25. Ko J, Ra W, Bae T, Lee T, Kim HH, Han HS. Two-port laparoscopic placement of a peritoneal dialysis catheter with abdominal wall fixation. Surg Today 2009;39(4):356–8.
26. Pan A, Poi MJ, Matos J, Jiang JS, Kfoury E, Echeverria A, et al. Long-term outcomes of single-port laparoscopic placement of peritoneal dialysis catheter. Vasc Endovascular Surg. 2016 Jul;50(5):343-8.
27. Milliken I, Fitzpatrick M, Subramaniam R. Single-port laparoscopic insertion of peritoneal dialysis catheters in children. J Pediatr Urol. 2006 Aug;2(4):308-11.
28. Liu YY, Diana M, Halvax P, Cho S, Légner A, Alzaga A, et al. Flexible endoscopic single-incision extraperitoneal implant and fixation of peritoneal dialysis catheter: proof of concept in the porcine model. Surg Endosc. 2015 Aug;29(8):2402-6.

Review

Hell J Surg. 2025 Jul-Sep;95(3):114–126
doi: 10.59869/25072

Indocyanine Green Fluorescence Imaging in Colorectal Surgery: Applications, Limitations, and Future Perspectives

Elissavet Anestiadou, Efstathios Kotidis, Orestis Ioannidis, Angeliki Cheva, Christiana Chatzianestiadou, Savvas Symeonidis, Stefanos Bitsianis, Thomai Gamali, Manousos-George-Pramateftakis, Ioannis Mantzoros, Vasileios Foutsitzis, Nikolaos Ouzounidis, Stamatios Angelopoulos

Fourth Department of Surgery, School of Medicine, Faculty of Health Sciences, Aristotle University of Thessaloniki, "G. Papanikolaou" General Hospital, Thessaloniki, Greece

ABSTRACT

Background: Indocyanine green (ICG) fluorescence imaging provides real-time perfusion assessment and anatomical guidance during colorectal surgery. Its most established application is anastomotic perfusion assessment, although its effect on anastomotic leakage remains inconsistent across randomised trials. **Aims:** To review the clinical applications, technical limitations, and future perspectives of ICG fluorescence imaging in colorectal surgery, with particular emphasis on randomised evidence concerning anastomotic leakage. **Methods:** A focused PubMed/MEDLINE search identified English-language publications available through July 2026. Reference lists were also examined. Priority was given to randomised trials, prospective studies, systematic reviews, and publications addressing technical and clinical applications. **Results:** ICG fluorescence imaging supports assessment of bowel and reconstructive-flap perfusion, ureteral visualisation, lymphatic mapping, lesion localisation, and detection of selected metastatic deposits. Randomised trials show mixed effects on anastomotic leakage, with potential benefit varying according to surgical setting and anastomotic location. Major limitations include subjective interpretation, heterogeneous administration and imaging protocols, device-dependent signals, and the absence of validated quantitative thresholds. **Conclusion:** ICG fluorescence imaging is a useful adjunct in colorectal surgery, but satisfactory fluorescence alone does not establish anastomotic safety or exclude the need for a diverting stoma in selected patients. Standardised protocols, quantitative measurements, and indication-specific validation are needed to improve clinical decision-making.

Key words: *Indocyanine green; fluorescence imaging; colorectal surgery; anastomotic leak; image-guided surgery*

Corresponding author:
Elissavet Anestiadou
Fourth Department of Surgery, School of Medicine,
Faculty of Health Sciences, Aristotle University of Thessaloniki
"G. Papanikolaou" General Hospital
Exochi, 57010 Thessaloniki, Greece
Tel.: +30 698 048 1017, e-mail: elissavetxatz@gmail.com
ORCID: 0000-0001-5650-7319

Submission: 28.07.2026, Acceptance: 15.10.2026

INTRODUCTION

Minimally invasive colorectal surgery has improved postoperative recovery and perioperative outcomes while progressively reducing the surgeon's reliance on direct palpation and unrestricted visual exposure of the surgical field. This transition has increased the need for technologies capable of providing physiological and anatomical information that cannot be obtained reliably under white-

light imaging alone [1]. Near-infrared fluorescence imaging with indocyanine green (ICG) addresses part of this need by offering real-time visualisation of tissue perfusion, lymphatic drainage, selected anatomical structures, and tumour-associated fluorescence without exposure to ionizing radiation [1,2].

Colorectal cancer screening contributes to cancer prevention through the detection and removal of precancerous lesions and facilitates diagnosis at an earlier stage. Healthcare professionals have an important role in identifying eligible individuals, explaining available screening options, and ensuring appropriate follow-up, including colonoscopy after a positive stool-based test [3]. Screening and intraoperative fluorescence imaging address different stages of the colorectal care pathway: screening supports prevention and early diagnosis, whereas ICG provides guidance during surgical treatment.

The most established application in colorectal surgery is fluorescence angiography for assessment of bowel perfusion before and after anastomosis. Anastomotic leakage remains one of the most consequential complications of colorectal resection, with an important effect on reoperation, permanent stoma formation, length of stay, quality of life, oncological outcome, and healthcare costs [4,5]. Perfusion is a strong determinant of anastomotic healing, and also, one of the few determinants that can be modified intraoperatively. Previous perfusion evaluation measures, including conventional assessment based on bowel colour, pulsatile mesenteric flow, marginal arterial bleeding, and the surgeon's overall impression, are inherently subjective and have limited predictive accuracy [6].

ICG is a water-soluble tricarbocyanine dye that binds with plasma proteins after intravenous administration and emits fluorescence in the near-infrared spectrum. Its short plasma half-life allows for repeated administration intraoperatively, while near-infrared light penetrates several millimeters into tissue and enables fluorescence visualisation through a limited layer of fat or connective tissue [1,7]. Such properties have also extended the use of indocyanine green to other indications such as identification of the ureter following intraureteral injection, lymphatic mapping, sentinel-node research, endoscopic localisation of colorectal lesions, detection of selected peritoneal or hepatic deposits, and the light-guided dissection technique.

Early observational studies and pooled analyses suggested a substantial reduction in anastomotic leakage after ICG fluorescence angiography [8-13]. However, recent randomised trials have reported less uniform results [14-19]. This discrepancy has shifted the clinical interest from whether ICG fluorescence can adequately estimate perfusion to when its application alters surgical decisions and leads to clinically important outcomes. This narrative review will explore the present application of ICG fluorescence imaging in the field of colorectal surgery, with particular focus on understanding the latest randomised data, technical limitations, and needs for standardisation and quantification. The principal clinical applications of ICG fluorescence imaging in colorectal surgery are summarised in Table 1. The routes and timing of ICG administration for the principal applications are summarised in Figure 1.

LITERATURE SEARCH STRATEGY

A focused literature search was performed in PubMed/MEDLINE for English-language publications available through July 2026. Search terms included combinations of "indocyanine green," "near-infrared fluorescence," "fluorescence angiography," "colorectal surgery," "anastomotic leakage," "bowel perfusion," "ureter," "lymphatic mapping," "sentinel lymph node," "tumour localisation," "peritoneal metastases," and "liver metastases." Reference lists of relevant reviews and major clinical studies were examined to identify additional publications, according to the snowball referencing method. Priority was given to randomised trials, prospective studies, systematic reviews, consensus-oriented publications, and original studies that described a technical or clinical application. Because the purpose was a broad clinical synthesis rather than estimation of a pooled treatment effect, narrative study selection and interpretation were performed.

COMPLICATIONS AFTER COLORECTAL SURGERY

Anastomotic Leakage

Anastomotic leakage (AL) represents failure of wall continuity at the site of a colorectal anastomosis, allowing communication between the intra- and extraluminal compartments. The International Study Group of Rectal Cancer proposed a clinically useful grading system: grade A leakage requires no active therapeutic intervention, grade B requires intervention without relaparotomy, and grade C requires reoperation [20]. Incidence is reported to be influenced by the level of the anastomosis, the definitions employed, and the level of postoperative surveillance; the lowest colorectal and coloanal anastomoses have the highest risk.

The clinical presentation ranges from an asymptomatic radiological finding to pelvic sepsis, diffuse peritonitis, multiorgan failure, and death. Diagnosis may occur after discharge, thus, studies confining the study period to the index admission can underestimate the true incidence [21]. Management depends on severity, anastomosis

TABLE 1. Principal applications of indocyanine green fluorescence imaging in colorectal surgery.

Application	Route/timing	Intended information	Main supporting evidence	Current limitation
Anastomotic perfusion	Intravenous; intraoperative	Arterial inflow and regional bowel enhancement	Multiple randomized trials and meta-analyses; benefit varies by surgical setting [12-19,36]	Subjective interpretation; no universal threshold
Pedicled omentum and reconstructive flaps	Intravenous; after mobilisation and before inset	Distal pedicle or flap enhancement	Small comparative observational studies and feasibility series [37,38]	Small, predominantly non-randomized series
Ileal pouch perfusion	Intravenous; before and after pouch construction or vascular ligation	Effect of lengthening maneuvers on pouch perfusion	Small observational and feasibility studies [39]	No validated time or intensity threshold
Ureteral visualisation	Retrograde intraureteral instillation	Repeated visualisation of ureteral course	Predominantly feasibility studies and observational series [41,42]	Requires cystoscopy; limited comparative outcome data
Lymphatic mapping	Submucosal or peritumoral injection	Lymphatic channels and fluorescent nodes	Feasibility and diagnostic-accuracy studies; systematic reviews [43-47]	Variable sensitivity; cannot replace standard lymphadenectomy
Lesion localisation	Endoscopic submucosal injection before surgery	Localisation of small/non-palpable lesions	Observational studies and technical series [48-50]	Time-dependent loss and injection-related spillage
Peritoneal metastasis detection	Intravenous, protocol-dependent	Additional superficial suspicious deposits	Small pilot and feasibility studies [51,52]	Non-specific uptake and limited penetration
Liver metastasis detection	Intravenous, usually preoperative	Superficial lesions and fluorescent tumour rim	Observational diagnostic studies and feasibility series [53-55]	Limited depth; background liver fluorescence
Transanal dissection guidance	Peritumoral or tissue-plane injection	Orientation and dissection-plane support	Technical reports and video descriptions [56]	Mainly technical evidence; operator-dependent

Note: Evidence categories describe the predominant study designs supporting each application and do not represent a formal GRADE assessment. The availability of randomised evidence does not imply uniform clinical benefit, and technical feasibility alone does not establish improved patient outcomes.

site, degree of contamination, and presence of a stoma. Antibiotics and image-guided drainage are generally adequate for a localised leak and collection, whereas generalised peritonitis or uncontrolled sepsis typically requires relaparotomy for source control.

Numerous causes have been associated with AL. Patient-related factors include malnutrition, obesity, smoking, diabetes, vascular disease, immunosuppression, and impaired functional reserve. Disease- and treatment-related factors include obstruction, sepsis, prior radiotherapy, advanced malignancy, and emergency surgery. Operative parameters include tension and inadequate perfusion at the anastomotic site, technical failure, multiple staple firings, blood loss, prolonged operating time, and a very low anastomosis [22]. No intraoperative imaging modality will be able to circumvent these interactions. In this regard, fluorescence angiography ought to be used as a perfusion-based risk assessment technique rather than an all-encompassing test of anastomotic integrity.

Anastomotic Bleeding

Postoperative anastomotic bleeding is often minor and self-limited, but persistent or substantial bleeding may require resuscitation and endoscopic treatment. Operative intervention is reserved for uncontrolled bleeding or cases unsuitable for endoscopic management; the approach depends on bleeding severity, haemodynamic status, and persistence [23,24]. ICG fluorescence assesses perfusion rather than haemostasis, and satisfactory enhancement does not exclude staple-line bleeding.

Anastomotic Stricture

Benign anastomotic stricture may develop following ischaemia, leakage, or pelvic inflammation. Endoscopic balloon dilatation is generally the initial treatment, with alternative endoscopic techniques or surgery considered for refractory cases [25]. Evidence that intraoperative ICG perfusion assessment prevents subsequent stricture remains limited.

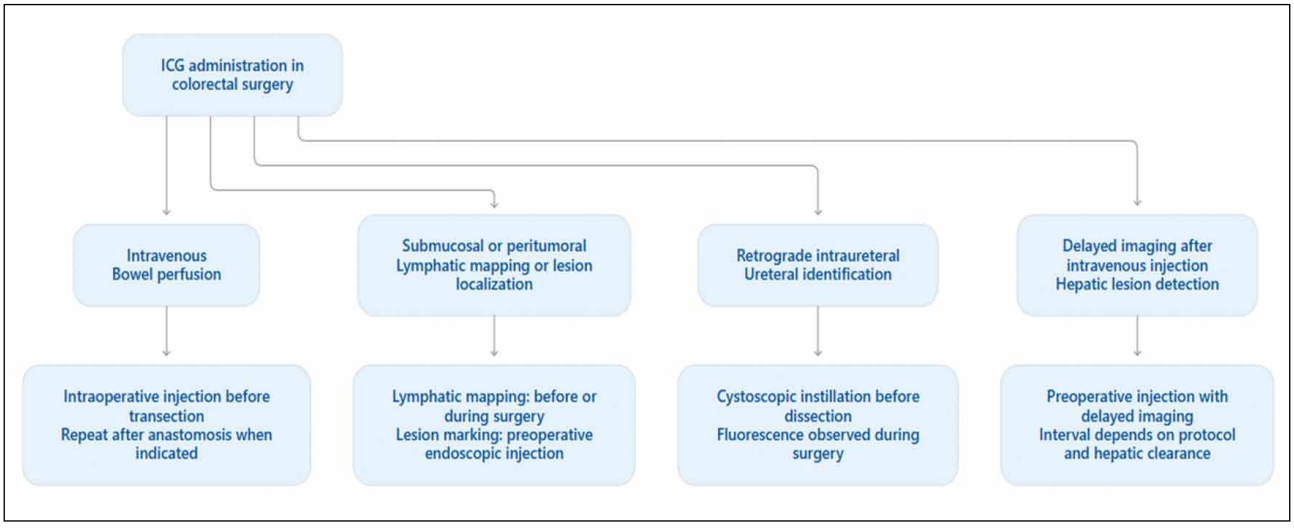

FIGURE 1. Routes and timing of indocyanine green administration for major colorectal applications. Intravenous ICG permits intraoperative assessment of bowel perfusion before transection and, when indicated, after anastomosis formation. Submucosal or peritumoral injection is used for lymphatic mapping or endoscopic lesion marking, with timing determined by the intended application. Retrograde intraureteral instillation enables ureteral visualisation during dissection. Hepatic lesion imaging uses preoperative intravenous administration followed by delayed intraoperative imaging to allow clearance from normal liver tissue. Dose, injection-to-imaging interval, and repeat administration vary between protocols; this schematic summarizes general approaches rather than a standardized regimen [1,2,42-45,48-50,53-55].

Surgical Site Infection

Surgical site infection (SSI) is among the most frequent complications after colorectal surgery and includes superficial incisional, deep incisional, and organ-space infections. It causes pain and wound-related morbidity, increases healthcare costs, and is associated with prolonged hospitalisation and readmission. Severe infections, particularly organ-space infections, may progress to sepsis and death [26]. In a prospective single-centre study of 133 patients undergoing elective colorectal cancer surgery, SSI occurred in 21.8% of patients. Higher rates were observed among older patients and those with obesity, diabetes, higher ASA class, or chronic steroid use [27].

Anastomotic leakage may cause intra-abdominal or pelvic infection, although organ-space SSI can also occur without anastomotic failure. Prevention requires a multimodal approach, including appropriate antimicrobial prophylaxis, skin preparation, maintenance of normothermia, glycaemic control, and combined mechanical bowel preparation and oral antibiotics for elective colorectal resection [26]. ICG fluorescence angiography provides information about bowel perfusion but does not assess bacterial contamination or mechanical anastomotic integrity. Satisfactory fluorescence therefore cannot exclude subsequent leakage or infection [1].

Butyrylcholinesterase (BChE), a liver-synthesised enzyme influenced by inflammation, nutritional status, and hepatic function, has been investigated as a potential marker of postoperative infectious complications. In a prospective single-center study of 402 patients undergoing colorectal surgery, lower BChE levels on postoperative days one and three were independently associated with SSI, but not with sepsis [28]. These findings suggest a possible role in postoperative risk assessment, although external validation and clinically useful thresholds are still needed. BChE remains an investigational adjunct to clinical assessment rather than an established predictor of anastomotic leakage.

Pathophysiology of Anastomotic Leakage

The process of anastomotic healing consists of a series of inflammatory, proliferative and remodelling phases. In the early days after surgery, collagen degradation surpasses collagen synthesis, while the structural strength of the anastomosis mainly relies on sutures or staples. Moreover, local hypoxia can interfere with the bacterial killing ability of oxidative mechanisms, the function of fibroblasts, angiogenesis, and collagen maturation, resulting in delayed tissue repair and increased susceptibility to infection [22,29].

Perfusion should not be regarded as a binary phenomenon. A bowel segment may receive sufficient arterial inflow to appear macroscopically viable while still exhibiting impaired microvascular distribution or venous drainage.

Systemic hypotension, vasopressor exposure, hypothermia, anaemia, tissue oedema, mesenteric traction, and excessive skeletonisation may further influence both the observed fluorescence pattern and the biological capacity for healing [6,22]. Nevertheless, perfusion represents only one component of anastomotic integrity. Mechanical tension, technical defects, distal obstruction, and local contamination remain equally important contributors to leakage. Contemporary understanding also recognises the interaction between local microbial activity, the inflammatory response, and patient-related susceptibility [30]. These overlapping mechanisms suggest that an apparently satisfactory fluorescence assessment cannot completely exclude subsequent anastomotic leakage [1,6,22].

ASSESSMENT OF COLORECTAL ANASTOMOTIC PERFUSION

The conventional assessment of bowel viability is based on a composite of serosal colour, peristalsis, bleeding from the transection margin, palpable or visible arterial pulsation, and overall surgeon impression. These findings are easily accessible but are influenced by ambient light, hypotension, vasoconstriction, mesenteric fat, pneumoperitoneum, and surgeon experience. Surgeons have shown variable performance when attempting to predict leakage based on clinical assessment alone [6].

A series of adjuncts have been proposed to assess colonic perfusion intraoperatively. Doppler ultrasonography assesses flow in larger vessels but provides limited information about distributed tissue perfusion. Laser Doppler flowmetry and laser speckle contrast imaging can characterise microvascular flow but may be sensitive to motion and distance. Tissue oximetry, visible-light spectroscopy, and hyperspectral imaging provide physiological information without necessarily requiring an injected fluorophore, although equipment availability and interpretation are still obstacles [31-33]. In addition, fluorescein with UV light has largely been superseded by ICG for visualisation of the biliary tree, as near-infrared visualisation has superior tissue penetration and is more readily adapted to current laparoscopic and robotic platforms [7,31,32].

ICG fluorescence angiography provides a practical compromise between physiological information and operative usability. The technique is rapid, repeatable, and produces an intuitive image of the distribution of dye. Its main limitation is that routine interpretation remains qualitative [1,34,35]. The fluorescence intensity is a function of not only perfusion but also of ICG dose, injection rate, cardiac output, distance and angle of the laparoscope, illumination, tissue thickness, system gain, and the time interval from injection. Therefore, a strongly visualised signal is not an absolute or device-independent measure of perfusion [1,34].

BASIC PRINCIPLES OF FLUORESCENCE IMAGING

Indocyanine Green

For decades, ICG has been used clinically in the evaluation of hepatic function, cardiac output measurement, and ophthalmic angiography. After intravenous administration, it binds rapidly to plasma proteins, remains predominantly in the intravascular space, and is cleared by the liver into bile without relevant renal excretion [7]. Its absorption and emission maxima are in the near-infrared range, approximately 780 and 820 nm, respectively. Tissue autofluorescence is relatively low in this spectrum, providing a favourable signal-to-background ratio.

The reported intravenous dose for assessment of bowel perfusion varies considerably in the literature. Fixed doses of 2.5-10 mg and weight-based regimens are both reported, with many protocols assessing fluorescence before resection, after construction of the anastomosis, or at both time points. Repeated ICG administration is allowed because of rapid plasma clearance, although residual background fluorescence and cumulative dose should be considered. ICG is generally well tolerated, but severe hypersensitivity reactions, including anaphylaxis, have been rarely reported and require immediate treatment. There is a need to check for any prior reaction to ICG or its derivatives, and to administer it with the anaesthetic team ready for any resuscitation effort [1,7,34].

Technical Equipment

A fluorescence imaging system requires an excitation light source, an optical filter that separates emitted fluorescence from reflected excitation light, a camera sensitive to near-infrared wavelengths, and a processor that displays the signal. Synchronous laparoscopic and robotic platforms permit switching between white-light, near-infrared, and overlay modes, while open systems are also available [1,7]. Changes in camera distance and angle will greatly affect intensity measurement. Quantitative procedures need to clearly state the type of system, type of imaging, distance, field stability, timing, and systemic factors involved. Without standardisation, thresholds obtained from one system are not transferrable to other systems [34].

Basic Principles of Fluorescence

When a fluorophore absorbs light at an appropriate wavelength, electrons move to a higher-energy state. As they return to baseline, energy is emitted as light of a

longer wavelength. The difference between excitation and emission wavelengths permits optical filtering and selective display of fluorescence. Signal intensity depends on fluorophore concentration, illumination, tissue absorption and scattering, detector sensitivity, and the geometry of image acquisition [1,7].

The near-infrared radiation passes through the tissue more effectively than visible light; however, it remains a surface-based method, and intraoperative factors such as heavy mesenteric fat, blood, tissue swelling, as well as an additional tissue layer may cause signal attenuation. It should be noted that the fluorescence imaging does not create images of the actual oxygenation or metabolism of cells but shows the pattern of blood containing ICG [1,7,34].

Principles of Fluorescence Angiography

Following intravenous administration, ICG appears first in arterial structures and subsequently within the capillary and venous phases. In bowel assessment, the surgeon observes the time to fluorescence, the direction and uniformity of enhancement, the position of the perfusion boundary, and the relationship of this boundary to the planned transection line. A poorly perfused segment may show delayed, weak, patchy, or absent enhancement, so the imaging sequence should be obtained before dividing a potentially questionable segment whenever possible [1,34]. After anastomosis, administration of a second dose can facilitate evaluation of the completed anastomosis, although interpretation may be complicated by background fluorescence from the first dose. If the fluorescence boundary lies proximal to the proposed transection, further resection to clearly perfused tissue can be considered. This decision must also account for tension, mesenteric reach, oncological margins, and the feasibility of reconstruction [1,34].

CLINICAL APPLICATIONS OF INDOCYANINE GREEN IN COLORECTAL SURGERY

Assessment of Anastomotic Perfusion

Initial clinical series demonstrated the feasibility of ICG fluorescence angiography and reported changes in the planned transection line in a meaningful minority of procedures [8-10]. The multicentee PILLAR II study reported a low leakage rate after left-sided colorectal resection and helped establish the technique in minimally invasive practice [11]. Subsequent observational studies and meta-analyses generally suggested lower AL rates with ICG fluorescence guidance, particularly in left-sided and rectal resections.

In contrast, the results obtained from randomised trials are inconsistent. In a multicentre study involving 240 participants, De Nardi et al. indicated that although there was alteration of resection levels by ICG injection in some of the participants, it did not bring about any statistically significant decrease in AL [14]. In addition, the single-center FLAG trial reported an overall effect that was reflected mainly in lower anastomoses [15]. The multicentre PILLAR III trial randomised 347 patients undergoing low anterior resection with an anastomosis within 10 cm of the anal verge. AL rates were similar with ICG and conventional assessment (9.0% versus 9.6%; P = 0.37). However, the trial was terminated early because of slow recruitment and did not reach its planned sample size, limiting the interpretation of its neutral findings [36]. Moreover, the EssentiAL trial, involving minimally invasive rectal cancer surgery, reported a reduction in AL from 11.8% in controls to 7.6% in the ICG group, representing an absolute difference of 4.2 percentage points [16]. Conversely, two large trials subsequently challenged routine, non-selective use. The phase III AVOID trial included 931 minimally invasive colorectal resections and found no significant reduction in clinically significant AL overall [17]. The ICG-COLORAL trial included 1,136 patients undergoing laparoscopic colorectal resection while excluding low anterior resection. AL occurred in 5.8% of the fluorescence group and 7.9% of the control group, with the difference not reaching statistical significance. A larger numerical effect was observed in left-sided procedures, whereas right-sided operations showed little difference [18]. In the European IntAct trial including rectal resections for oncological purposes, clinical AL occurred in approximately 10% of the ICG group and 15% of controls, but the primary comparison was not statistically significant and the observed effect appeared greater for less severe leaks than for leaks requiring major reintervention [19]. In conclusion, these studies do not imply the inefficacy of fluorescence visualisation. On the contrary, they demonstrate that while the physiological data provided by ICG are valuable, their influence does not result in the same degree of benefit in all cases of colorectal surgery. The risk of leakage is initially lower after most of the right-sided operations, providing little space for a visualising procedure to make an observable difference. The benefit is more likely to be achieved in those situations where the blood flow is uncertain and the consequences of its deficiency are serious, as in the case of low pelvic or selected left-sided anastomoses. Randomised trials still provide data on the relative decrease in AL [12,13].

An important interpretive challenge is the "change-of-plan" group, which includes intrinsically higher-risk patients whose transection line is revised because ICG fluorescence appears inadequate. AL within this sub-

group should not be interpreted as evidence that revision caused harm or that fluorescence failed; the counterfactual outcome without revision is unknown. Conversely, a low overall AL rate after fluorescence cannot prove causality in an uncontrolled cohort.

At present, ICG fluorescence angiography should complement and not replace intraoperative assessment of anastomosic tension, technical completeness, air-leak testing when appropriate, and the selective use of fecal diversion. Routine use is reasonable where equipment and expertise are available, but the strongest clinical rationale is for higher-risk left-sided and rectal reconstructions or when conventional assessment is uncertain. Quantitative outcomes of these randomised trials are summarised in Table 2; differences in surgical populations and leakage definitions should be considered when comparing their findings.

Additional Perfusion Applications

The same setting of near-infrared light can be utilised for different applications during colorectal procedures. The suggested approach is based on the pharmacokinetics of ICG, depending on the way it is administered. Intravenous administration of ICG corresponds to the blood and hepatobiliary transport, submucosa or tumour injection allows for its local accumulation and lymph transport, and intraureteral administration enables visualization of the ureteral cavity. It should be mentioned that these approaches are not interchangeable in technical terms and require certain protocols and interpretations. Garoufalia and Wexner also provide information about other perfusion-related applications of clinical importance besides traditional anastomosis evaluation [2]. During pedicled omentoplasty for chronic pelvic sepsis, fluorescence can identify distal omental segments that appear viable under white light but present compromised flow after mobilisation. In a comparative cohort, fluorescence-guided omentoplasty was associated with a lower rate of pelviperineal non-healing than conventional assessment (22% versus 42%), although the non-randomised design prevents a causal conclusion [37]. Furthermore, ICG fluorescence has also been investigated during gracilis muscle interposition and rectal advancement-flap procedures for complex perineal fistulas. In these procedures, viability of the distal flap is central to healing. Software-assisted analysis of gracilis perfusion has generated candidate objective indicators,

TABLE 2. Quantitative results of randomized trials evaluating ICG fluorescence angiography for prevention of anastomotic leakage.

Study	Surgical setting	Study population	AL with ICG	AL in controls	Reported effect estimate (95% CI)	P value
De Nardi et al., 2020 [14]	Laparoscopic left-sided colon and rectal resection	240 analysed	6/118 (5.1%)	11/122 (9.0%)	Not reported in the abstract	0.20
FLAG, 2020 [15]	Stapled colorectal anastomoses	377 analysed	17/187 (9.1%)	31/190 (16.3%)	Not reported in the abstract	0.04
PILLAR III, 2021 [36]	Low anterior resection with anastomosis within 10 cm of the anal verge	347 randomised: 178 ICG; 169 control	9.0%	9.6%	Adjusted OR 0.845 (0.375–1.905)	0.37 for group comparison; 0.34 for adjusted analysis
EssentiAL, 2023 [16]	Minimally invasive rectal cancer surgery	839 analysed	32/422 (7.6%)	49/417 (11.8%)	RR 0.645 (0.422–0.987)	0.041
AVOID, 2024 [17]	Minimally invasive colorectal surgery	931 analyzed	32/463 (6.9%)	42/468 (9.0%)	RR 0.77 (0.50–1.20)	0.24
ICG-COLORAL, 2025 [18]	Laparoscopic colorectal resection, excluding low anterior resection	1,136 analysed	33/567 (5.8%)	45/569 (7.9%)	OR 0.73 (0.48–1.13)	0.16
IntAct, 2025 [19]	Rectal cancer surgery	698 analysed; 766 randomised	36/343 (10.5%)	54/355 (15.2%)	Adjusted OR 0.667 (0.419–1.060)	0.087

AL, anastomotic leakage; ICG, indocyanine green; RR, relative risk; OR, odds ratio; CI, confidence interval. FLAG and EssentiAL report all-grade leakage, whereas AVOID and IntAct report clinically relevant leakage (grades B–C) within 90 days. Population sizes and effect estimates follow the respective study reports. PILLAR III was terminated early because of slow recruitment and did not achieve its planned sample size. Differences in surgical populations, leakage definitions, follow-up, and statistical analyses limit direct comparisons. Event counts are included where verified; PILLAR III rates are presented as reported.

while a small advancement-flap series reported that fluorescence findings frequently prompted revision of the proposed flap [2,38]. However, one should acknowledge that these findings are hypothesis-generating because the cohorts are small and lack controls.

Evaluation of ileal pouch-anal anastomosis (IPAA) is yet another area where perfusion and reach are in direct competition. The techniques employed during this procedure could involve the disruption of vascular arcades, thereby maintaining reach while risking the loss of inflow or venous return. It is possible to perform ICG fluorescence angiography both preoperatively and postoperatively in patients undergoing IPAA creation and vascular disruption. It was reported that the median time to onset of pouch fluorescence was 20 seconds pre-operatively and 25 seconds postoperatively; the latter showed delayed enhancement [39]. Collectively, these applications support a broader principle: fluorescence may be most useful when tissue has been mobilised on a pedicle and conventional inspection cannot reliably assess the distal microcirculation.

Ureteral Visualisation

Iatrogenic ureteral injury is an uncommon but serious complication in colorectal surgery. Risk increases in reoperative pelvic surgery, locally advanced malignancy, inflammatory disease, prior radiotherapy, obesity, and distorted anatomy. To limit this risk, preoperative placement of conventional prophylactic ureteral stents may assist identification by palpation or visualisation but does not consistently prevent injury and can add procedural time and urinary complications [40].

Because intravenously administered ICG is not excreted by the kidneys, ureteral fluorescence generally requires cystoscopy and retrograde intraureteral instillation. Small series have shown prolonged and clear visualisation during complex robotic colorectal operations [41,42]. Fluorescence with ICG enables recurrent identification without persistent dissection of the ureters, but the method still necessitates knowledge of anatomy. Cystoscopy requirements, risks associated with possible instrumentation, inconsistent application of the procedure, and lack of comparative studies confirming lower injury rates hinder regular use of ICG to identify ureters because renally excreted fluorophores offer a more efficient solution.

Lymphatic Mapping and Sentinel Lymph-Node Detection

Submucosal or peritumoral ICG injection can delineate lymphatic drainage and fluorescent nodes. The technique has been used to map drainage patterns, identify unexpected lymphatic basins, and guide the extent of mesocolic or lateral pelvic lymph-node dissection [43-45]. In colon cancer, fluorescence may reveal nodes outside the expected field basin and can assist ex vivo identification of small nodes in the specimen.

The sentinel-node concept is more difficult in colorectal cancer than in breast cancer or melanoma. Complex and tumour-altered lymphatic drainage, skip metastases, injection technique, and limited tissue penetration can reduce fluorescence accuracy. A meta-analysis reported encouraging sensitivity for node mapping but insufficient reliability to omit standard oncological lymphadenectomy [46]. More recent studies continue to emphasise methodological heterogeneity and limited evidence for oncological benefit [47]. Therefore, ICG lymphography may currently serve as an adjunct for navigation and research, not a replacement for complete mesocolic or total mesorectal excision according to oncological principles.

Endoscopic Marking of Colorectal Lesions

Accurate localisation of small or non-palpable lesions is essential during minimally invasive surgery. Conventional carbon-based tattooing is durable but may cause inflammatory staining, dye spillage, or difficulty distinguishing the exact operative target. To address these limitations, ICG can be injected endoscopically into the submucosa and visualised intraoperatively with near-infrared imaging [48,49].

The principal limitation of this technique is time-dependent signal loss. ICG marking is best suited to surgery performed within a defined interval after colonoscopy and marking, although reported visibility varies with concentration and injection technique. Recent clinical experience supports feasibility, including combination with lymphatic mapping [50]. Standardised injection in all quadrants of the lesion, avoidance of intraperitoneal spillage, and documentation of the relationship between the tattoo and the lesion remain necessary.

Detection of Peritoneal Metastases

After intravenous administration, ICG may accumulate in or around some tumour deposits through abnormal vascular permeability and impaired clearance. Pilot studies in colorectal peritoneal carcinomatosis demonstrated that near-infrared inspection can reveal lesions not readily visible under white light [51,52]. This particular use is most important during staging or debulking surgery when small deposits could influence the peritoneal cancer index and extent of debulking. But there is no consensus on the

sensitivity and specificity of this technique. Inflammatory reactions, fibrotic changes, previous treatments, mucinous morphology, depth of deposits, and nonspecific retention may lead to false results. Near-infrared light is not able to penetrate into deeply seated deposits. Therefore, ICG fluorescence should guide palpation or exploration and not alone decide on resectability.

Detection of Colorectal Liver Metastases

Tumours can disturb local biliary excretion and produce a fluorescent rim around metastases, particularly after administration one or more days before surgery. Intraoperative studies have shown that ICG fluorescence may detect small superficial colorectal liver metastases that are overlooked by inspection and, in some cases, by intraoperative ultrasonography [53-55]. However, efficacy of this technique is limited to lesions close to the hepatic surface because of restricted tissue penetration. In addition, benign or treatment-related abnormalities can fluoresce, and background liver signal depends on timing and hepatic function. To sum up, intraoperative ultrasonography remains indispensable for deep lesions and vascular relationships, while fluorescence is best used as a complementary surface survey and margin-orientation tool.

Fluorescence Guidance During Transanal Total Mesorectal Excision

Transanal total mesorectal excision was developed to address difficult distal pelvic dissection, but correct orientation during dissection in the unfamiliar bottom-up view can be challenging. Peritumoral or mesorectal ICG injection has been described as an adjunct for delineating tissue planes and facilitating rendezvous between abdominal and transanal teams [56]. Nevertheless, relevant evidence is mostly technical and observational. In addition, since transanal total mesorectal excision has oncological issues, fluorescence alone cannot substitute for proper training and quality assurance.

Educational Applications

Fluorescence imaging provides a visual demonstration of perfusion that can be reviewed by the operating team. In a study of surgical beginners, ICG angiography improved the ability to assess bowel perfusion and influenced intraoperative decision-making [57]. It may therefore help trainees connect mesenteric division and tissue handling with the resulting perfusion pattern.

Education must also address misinterpretation, since surgical trainees may overvalue a bright image, assume that fluorescence excludes leakage, or fail to recognize technical factors that alter signal intensity. Structured teaching should integrate fluorescence findings with anatomy, systemic physiology, anastomotic technique, and postoperative risk.

Limitations of Intraoperative Indocyanine Green

The principal limitation of ICG fluorescence imaging is the absence of a universally accepted definition of an adequate perfusion pattern. Most surgeons interpret fluorescence subjectively, and substantial interobserver variation has been documented [35]. Intensity in itself is an unreliable index since it depends on dose, dilution, time of administration, camera set-up, tissue depth, environmental variables, and proprietary image enhancement techniques. While time-related indices like the fluorescence slope, time to peak, and intensity ratios might be more meaningful, their cut-offs have not been validated yet.

Protocol inconsistency is quite high. Different studies vary in dose (fixed or weight-dependent), timing of dose relative to transection, number of doses, distance of imaging, criteria for a positive test, and the steps taken following an abnormal finding. In addition, the haemodynamic parameters are frequently inadequately reported. A recent systematic review of quantitative fluorescence tests found considerable differences in acquisition and analysis techniques, with a very few using real-time analysis [34].

It should be also taken in to consideration that ICG fluorescence assesses perfusion at the time of imaging. Thus, it is not able to detect a later thrombotic event, excessive postoperative tension, staple-line disruption, pelvic infection, or impaired healing from systemic disease. The technique may also create false reassurance and it is highlighted that a surgeon should not preserve a technically compromised or tensioned anastomosis solely because fluorescence appears satisfactory.

Adverse reactions after ICG injection are rare but potentially severe. ICG administration adds cost, and access to compatible equipment varies between institutions. Intraureteral and peritumoral applications introduce separate procedural and regulatory considerations. Finally, much of the broader application literature consists of small cohorts and feasibility studies, making clinical effectiveness and cost-effectiveness uncertain.

FUTURE PERSPECTIVES

Quantitative perfusion assessment requires a distinction between absolute fluorescence intensity and temporal or normalised measurements. Absolute intensity is strongly influenced by the imaging platform, camera

distance and angle, illumination, system settings, and ICG dose, making values difficult to compare across devices or acquisition protocols. Time-based parameters, such as time-to-fluorescence and time-to-peak, and normalised measures, such as intensity ratios, may facilitate comparison, but remain sensitive to acquisition methods and physiological conditions. The fluorescence slope combines temporal and intensity information and therefore also requires calibration and a clearly defined calculation method [34,58]. Although automated analysis and AI may help characterize perfusion patterns, accurate classification alone does not establish clinical usefulness [59]. The key requirement is a prospectively validated threshold, transferable across platforms or calibrated for a specific system, that guides an actionable surgical decision. Validation should establish whether threshold-guided management reduces clinically relevant anastomotic leakage compared with conventional assessment.

Deep learning is also being explored in the histopathological assessment of colorectal cancer. Studies have shown that these algorithms can distinguish tumour from non-neoplastic tissue and predict microsatellite instability from routine hematoxylin-and-eosin images [60,61]. These findings suggest a possible role in assisting pathologists with tissue classification and selecting cases for further molecular testing. However, performance may vary with staining methods, scanners, and patient populations, and prospective validation is needed before wider clinical use. Although separate from ICG fluorescence imaging, this research provides another example of how automated image analysis may support colorectal cancer care.

Recent evidence syntheses published after the completion of the major contemporary trials sharpen this risk-adapted interpretation. Mc Entee et al. found that ICG fluorescence frequently changes the planned transection point and is associated with lower AL rates, while also emphasizing that patients requiring a fluorescence-guided change are an intrinsically higher-risk subgroup [62]. Updated randomised-trial meta-analyses published in 2026, incorporating up to ten trials, reported reductions in overall or clinically significant AL mainly concentrated in left-sided and rectal resections, with no significant benefit after right-sided procedures [63,64]. Similarly, the 2025 SAGES evidence synthesis also reported lower colorectal AL and substantially more intraoperative changes in the transection point, but judged evidence for several other gastrointestinal applications to be limited or inconclusive [65]. These pooled findings strengthen the rationale for selective use of ICG while remaining compatible with the neutral primary findings of several individual trials.

Data supporting outcomes other than anastomotic examination and AL prevention are increasing but are still in early stage. One such study is a prospective study conducted in one center in 2026 involving 113 patients undergoing laparoscopic sigmoid and rectal cancer surgery. No statistically significant difference was observed in the AL incidence rate, but there were no anastomotic strictures after fluorescence examination as opposed to 11.4% in the control group [66]. Cross-specialty evidence also illustrates the wider potential of the platform. A 2026 systematic review of 17 studies in minimally invasive hernia surgery described feasible use for bowel and abdominal-wall perfusion, vascular and anatomical delineation, and lymphatic mapping, but the evidence consisted mainly of small observational reports with heterogeneous protocols [67]. Such findings support broader physiological and navigational applications of ICG while reinforcing the need for indication-specific validation.

Further research would have to refine the indications for fluorescence. Data indicate that the operative field and individual risks influence the effect that can be achieved. A single protocol for right colectomy, low anterior resection, redo pelvis surgery, and acute ischemic bowel disease would not work well. An individualised approach taking into account patient characteristics, anastomosis location, haemodynamic conditions, and quantitative imaging would yield better results than a blanket protocol. In addition, novel renal excreted fluorophores would allow for better visualisation of ureters, targeting tumours, and deeper penetration. Specificity could be improved with molecularly-targeted imaging agents directed at tumour receptors.

Last but not least, establishment of reporting standards is necessary. Studies should specify the device, dose, timing, number of injections, imaging distance, haemodynamic state, interpretation method, frequency and type of change in intraoperative plan, anastomotic level, diversion, and standardised AL grade.

CONCLUSIONS

ICG fluorescence imaging is a valuable tool in colorectal surgery. While most mature application is anastomotic perfusion assessment, numerous contemporary randomised trials show that clinical benefit is context-dependent rather than universal. The strongest rationale appears to be in left-sided and rectal reconstruction and in cases where conventional assessment is not adequate. Ureteral visualisation, lymphatic mapping, lesion localisation, and detection of selected metastatic deposits are promising but supported mainly by lower-level evidence.

In each and every instance, ICG fluorescence should be used as a supplement rather than a substitute for good

operative technique. The current shortcomings of ICG imaging lie more in the process of its interpretation than in the actual production of the image itself. In order to use fluorescence as an objective decision aid, standardised procedures and quantitative criteria must be defined.

Acknowledgements: *None.*

Artificial Intelligence Statement: *No generative artificial intelligence (AI) tools were used in the preparation, writing, editing, or scientific interpretation of this manuscript. All content was developed and critically reviewed by the authors.*

Funding: *This research received no external funding.*

Conflict of Interest: *The authors declare no conflict of interest.*

REFERENCES

1. Keller DS, Ishizawa T, Cohen R, Chand M. Indocyanine green fluorescence imaging in colorectal surgery: Overview, applications, and future directions. Lancet Gastroenterol Hepatol. 2017 Oct;2(10):757-66.
2. Garoufalia Z, Wexner SD. Indocyanine green fluorescence-guided surgery in colorectal surgery. J Clin Med. 2023 Jan;12(2):494.
3. US Preventive Services Task Force, Davidson KW, Barry MJ, Mangione CM, Cabana M, Caughey AB, Davis EM, et al. Screening for colorectal cancer: US Preventive Services Task Force recommendation statement. JAMA. 2021 May;325(19):1965-77.
4. Brown SR, Mathew R, Keding A, Marshall HC, Brown JM, Jayne DG. The impact of postoperative complications on long-term quality of life after curative colorectal cancer surgery. Ann Surg. 2014 May;259(5):916-23.
5. Hammond J, Lim S, Wan Y, Gao X, Patkar A. The burden of gastrointestinal anastomotic leaks: an evaluation of clinical and economic outcomes. J Gastrointest Surg. 2014 Jun;18(6):1176-85.
6. Karliczek A, Harlaar NJ, Zeebregts CJ, Wiggers T, Baas PC, van Dam GM. Surgeons lack predictive accuracy for anastomotic leakage in gastrointestinal surgery. Int J Colorectal Dis. 2009 May;24(5):569-76.
7. Alander JT, Kaartinen I, Laakso A, Patila T, Spillmann T, Tuchin VV, et al. A review of indocyanine green fluorescent imaging in surgery. Int J Biomed Imaging [Internet]. 2012; 2012:940585. Available from: https://onlinelibrary.wiley.com/doi/epdf/10.1155/2012/940585
8. Kudszus S, Roesel C, Schachtrupp A, Hoer JJ. Intraoperative laser fluorescence angiography in colorectal surgery: a noninvasive analysis to reduce the rate of anastomotic leakage. Langenbecks Arch Surg. 2010 Nov;395(8):1025-30.
9. Boni L, David G, Dionigi G, Rausei S, Cassinotti E, Fingerhut A. Indocyanine green-enhanced fluorescence to assess bowel perfusion during laparoscopic colorectal resection. Surg Endosc. 2016 Jul;30(7):2736-42.
10. Jafari MD, Lee KH, Halabi WJ, Mills SD, Carmichael JC, Stamos MJ, et al. The use of indocyanine green fluorescence to assess anastomotic perfusion during robotic-assisted laparoscopic rectal surgery. Surg Endosc 2013 Feb;27:3003-8.
11. Jafari MD, Wexner SD, Martz JE, McLemore EC, Margolin DA, Sherwinter DA, et al. Perfusion assessment in laparoscopic left-sided/anterior resection: a multi-institutional study. J Am Coll Surg 2015 Jan;220(1):82-92.e1.
12. Lucarini A, Guida AM, Orville M, Panis Y. Indocyanine green fluorescence angiography could reduce the risk of anastomotic leakage in rectal cancer surgery: A systematic review and meta-analysis of randomized controlled trials. Colorectal Dis. 2024 Mar;26(3):408-16.
13. Afridi A, Zulfiqar A, Sajjad F, Shahid I, Habib H, Saleem Y, et al. Efficacy and safety of indocyanine green fluorescence imaging in colorectal cancer: a systematic review and meta-analysis of randomized controlled trials. Int J Colorectal Dis. 2025 Sep;40(1):193.
14. De Nardi P, Elmore U, Maggi G, Maggiore R, Boni L, Cassinotti E, et al. Intraoperative angiography with indocyanine green to assess anastomosis perfusion in patients undergoing laparoscopic colorectal resection: Results of a multicenter randomized controlled trial. Surg Endosc. 2020 Jan;34(1):53-60.
15. Alekseev M, Rybakov E, Shelygin Y, Chernyshov S, Zarodnyuk I. A study investigating the perfusion of colorectal anastomoses using fluorescence angiography: results of the FLAG randomized trial. Colorectal Dis. 2020 Sep;22(9):1147-53.
16. Watanabe J, Takemasa I, Kotake M, Noura S, Kimura K, Suwa H, et al. Blood perfusion assessment by indocyanine green fluorescence imaging for minimally invasive rectal cancer surgery (EssentiAL trial): A randomized clinical trial. Ann Surg. 2023 Oct;278(4):e688-94.
17. Faber RA, Meijer RPJ, Droogh DHM, Jongbloed JJ, Bijlstra OD, Boersma F, et al. Indocyanine green near-infrared fluorescence bowel perfusion assessment to prevent anastomotic leakage in minimally invasive colorectal surgery (AVOID): a multicentre, randomised, controlled, phase 3 trial. Lancet Gastroenterol Hepatol. 2024 Oct;9(10):924-34
18. Rinne JKA, Huhta H, Pinta T, Turunen A, Mattila A, Tahkola K, et al. Indocyanine green fluorescence imaging in prevention of colorectal anastomotic leakage: A randomized clinical trial. JAMA Surg. 2025 May;160(5):486-93.
19. Jayne D, Croft J, Corrigan N, Quirke P, Cahill RA, Ainsworth G, et al. Intraoperative fluorescence angiography with indocyanine green to prevent anastomotic leak in rectal cancer surgery (IntAct): an unblinded randomised controlled trial. Lancet Gastroenterol Hepatol. 2025 Sep;10(9):806-17.
20. Rahbari NN, Weitz J, Hohenberger W, Heald RJ, Moran B, Ulrich A, et al. Definition and grading of anastomotic leakage following anterior resection of the rectum: A proposal by the International Study Group of Rectal Cancer. Surgery. 2010 Mar;147(3):339-51.
21. Hyman N, Manchester TL, Osler T, Burns B, Cataldo PA. Anastomotic leaks after intestinal anastomosis: it is later than you think. Ann Surg. 2007 Feb;245(2):254-8.
22. McDermott FD, Heeney A, Kelly ME, Steele RJ, Carlson GL, Winter DC. Systematic review of preoperative, intraoperative and postoperative risk factors for colorectal

anastomotic leaks. Br J Surg. 2015 Apr;102(5):462-79.
23. Perez RO, Sousa A, Bresciani C, Proscurshim I, Coser R, Kiss D, et al. Endoscopic management of postoperative stapled colorectal anastomosis hemorrhage. Tech Coloproctol. 2007 Mar;11(1):64-6.
24. Martinez-Serrano MA, Pares D, Pera M, Pascual M, Courtier R, Egea MJ, et al. Management of lower gastrointestinal bleeding after colorectal resection and stapled anastomosis. Tech Coloproctol. 2009 Mar;13(1):49-53.
25. Ridtitid W, Siripun A, Rerknimitr R. Stricture at colorectal anastomosis: to dilate or to incise. Endosc Int Open [Internet]. 2018; 6:E340-1. Available from: https://pmc.ncbi.nlm.nih.gov/articles/PMC5844386/
26. Shogan BD, Vogel JD, Davis BR, Keller DS, Ayscue JM, Goldstein LE, et al. The American Society of Colon and Rectal Surgeons Clinical Practice Guidelines for Preventing Surgical Site Infection. Dis Colon Rectum. 2024 Nov;67(11):1368-82.
27. Panos G, Mulita F, Akinosoglou K, Liolis E, Kaplanis C, Tchabashvili L, et al. Risk of surgical site infections after colorectal surgery and the most frequent pathogens isolated: a prospective single-centre observational study. Med Glas (Zenica). 2021 Aug;18(2):438-43.
28. Verras GI, Mulita F. Butyrylcholinesterase levels correlate with surgical site infection risk and severity after colorectal surgery: A prospective single-center study. Front Surg [Internet]. 2024 Aug;11:1379410. Available from: https://pubmed.ncbi.nlm.nih.gov/39229253/
29. Morgan RB, Shogan BD. The science of anastomotic healing. Semin Colon Rectal Surg [Internet]. 2022; 33:100879. Available from: https://www.sciencedirect.com/science/article/abs/pii/S1043148922000203?via%3Dihub
30. Shogan BD, Belogortseva N, Luong PM, Zaborin A, Lax S, Bethel C, et al. Collagen degradation and MMP9 activation by Enterococcus faecalis contribute to intestinal anastomotic leak. Sci Transl Med [Internet] 2015 May; 7 (286):286ra68. Available from: https://pubmed.ncbi.nlm.nih.gov/25947163/
31. Urbanavicius L, Pattyn P, Van de Putte D, Venskutonis D. How to assess intestinal viability during surgery: a review of techniques. World J Gastrointest Surg. 2011 May;3(5):59-69.
32. Bryski MG, Frenzel Sulyok LG, Kaplan L, Singhal S, Keating JJ. Techniques for intraoperative evaluation of bowel viability in mesenteric ischemia: A review. Am J Surg. 2020 Aug;220(2):309-15.
33. Jansen-Winkeln B, Germann I, Kohler H, Mehdorn M, Maktabi M, Sucher R, et al. Comparison of hyperspectral imaging and fluorescence angiography for the determination of the transection margin in colorectal resections: A comparative study. Int J Colorectal Dis. 2021 Feb;36(2):283-91.
34. McEntee PD, Singaravelu A, McCarrick CA, Murphy E, Boland PA, Cahill RA. Quantification of indocyanine green fluorescence angiography in colorectal surgery: a systematic review of the literature. Surg Endosc. 2025 Apr;39(4):2677-91.
35. Soares AS, Clancy NT, Bano S, Raza I, Diana M, Lovat LB, et al. Interobserver variability in the assessment of fluorescence angiography in the colon. Surg Innov. 2023 Feb;30(1):45-9.
36. Jafari MD, Pigazzi A, McLemore EC, Mutch MG, Haas E, Rasheid SH, et al. Perfusion Assessment in Left-Sided/Low Anterior Resection (PILLAR III): A Randomized, Controlled, Parallel, Multicenter Study Assessing Perfusion Outcomes With PINPOINT Near-Infrared Fluorescence Imaging in Low Anterior Resection. Dis Colon Rectum. 2021 Aug;64(8):995-1002.
37. Slooter MD, Eshuis WJ, Cuesta MA, Gisbertz SS, van Berge Henegouwen MI, Bemelman WA, et al. Optimizing omentoplasty for management of chronic pelvic sepsis by intra-operative fluorescence angiography: a comparative cohort study. Colorectal Dis 2020; 22:2252-61.
38. Lobbes LA, Hoveling RJM, Schmidt LR, Berns S, Weixler B. Objective perfusion assessment in gracilis muscle interposition: a novel software-based approach to indocyanine green-derived near-infrared fluorescence in reconstructive surgery. Life (Basel). 2022 Feb;12(2):278.
39. Slooter MD, van der Does de Willebois EML, Joosten JJ, Reijntjes MA, Buskens CJ, Tanis PJ, et al. Fluorescence perfusion assessment of vascular ligation during ileal pouch-anal anastomosis. Tech Coloproctol. 2023 Apr;27(4):281-90.
40. Halabi WJ, Jafari MD, Nguyen VQ, Carmichael JC, Mills S, Pigazzi A, et al. Ureteral injuries in colorectal surgery: an analysis of trends, outcomes, and risk factors over a 10-year period in the United States. Dis Colon Rectum. 2014 Feb;57(2):179-86.
41. Mandovra P, Kalikar V, Patankar RV. Real-time visualization of ureters using indocyanine green during laparoscopic surgeries: can we make surgery safer? Surg Innov. 2019 Aug;26(4):464-8.
42. White LA, Joseph JP, Yang DY, Kelley SR, Mathis KL, Behm K, et al. Intraureteral indocyanine green augments ureteral identification and avoidance during complex robotic-assisted colorectal surgery. Colorectal Dis. 2021 Mar;23(3):718-23.
43. Ushijima H, Kawamura J, Ueda K, Yane Y, Yoshioka Y, Daito K, et al. Visualization of lymphatic flow in laparoscopic colon cancer surgery using indocyanine green fluorescence imaging. Sci Rep [Internet] 2020;10:14274. Available from: https://www.nature.com/articles/s41598-020-71215-3?utm_source=researchgate.net&utm_medium=article
44. Handgraaf HJM, Boogerd LSF, Verbeek FPR, Tummers QRJG, Hardwick JCH, Baeten CIM, et al. Intraoperative fluorescence imaging to localize tumors and sentinel lymph nodes in rectal cancer. Minim Invasive Ther Allied Technol. 2016;25(1):48-53.
45. Nishigori N, Koyama F, Nakagawa T, Nakamura S, Ueda T, Inoue T, et al. Visualization of lymph/blood flow in laparoscopic colorectal cancer surgery by ICG fluorescence imaging. Ann Surg Oncol. 2016 Feb:23(Suppl 2):S266-74.
46. Emile SH, Elfeki H, Shalaby M, Sakr A, Sileri P, Laurberg S, et al. Sensitivity and specificity of indocyanine green near-infrared fluorescence imaging in detection of metastatic lymph nodes in colorectal cancer: systematic review and meta-analysis. J Surg Oncol. 2017 Nov;116(6):730-40.
47. Litchinko A, Meyer J, Buhler L, Ris F, Adamina M. Fluorescence indocyanine green for sentinel-lymph-node mapping in colorectal cancer: a systematic review. Langenbecks Arch Surg. 2025 Jul;410(1):202.

48. Lee SJ, Sohn DK, Han KS, Kim BC, Hong CW, Park SC, et al. Preoperative tattooing using indocyanine green in laparoscopic colorectal surgery. Annals of Coloproctology 2018;34(4):206-11.
49. Nagata J, Fukunaga Y, Akiyoshi T, Konishi T, Fujimoto Y, Nagayama S, et al. Colonic marking with near-infrared, light-emitting, diode-activated indocyanine green for laparoscopic colorectal surgery. Dis Colon Rectum. 2016 Feb;59(2):e14-8
50. Varanese M, Arcieri S, Lauro A, Panetta C, Eberspacher C, Palma R, et al. Indocyanine green tattooing during colonoscopy as a guide to laparoscopic colorectal cancer surgery: a literature review. Surg Innov 2024; 31(1):103-10.
51. Liberale G, Vankerckhove S, Gomez Caldon M, Ahmed B, Moreau M, El Nakadi I, et al. Fluorescence imaging after indocyanine green injection for detection of peritoneal metastases in patients undergoing cytoreductive surgery for peritoneal carcinomatosis from colorectal cancer: a pilot study. Ann Surg. 2016 Dec;264(6):1110-5.
52. Barabino G, Klein JP, Porcheron J, Grichine A, Coll JL, Cottier M. Intraoperative near-infrared fluorescence imaging using indocyanine green in colorectal carcinomatosis surgery: proof of concept. Eur J Surg Oncol 2016 Dec;42(12):1931-7.
53. Ishizawa T, Fukushima N, Shibahara J, Masuda K, Tamura S, Aoki T, et al. Real-time identification of liver cancers by using indocyanine green fluorescent imaging. Cancer 2009 Jun;115(11):2491-504.
54. Peloso A, Franchi E, Canepa MC, Barbieri L, Briani L, Ferrario J, et al. Combined use of intraoperative ultrasound and indocyanine green fluorescence imaging to detect liver metastases from colorectal cancer. HPB (Oxford). 2013 Dec;15(12):928-34.
55. van der Vorst JR, Schaafsma BE, Hutteman M, Verbeek FPR, Liefers GJ, Hartgrink HH, et al. Near-infrared fluorescence-guided resection of colorectal liver metastases. Cancer. 2013 Sep;119(18):3411-8.
56. Dapri G, Cahill R, Bourgeois P, Liberale G, Gomez Galdon M, Cadiere GB. Peritumoural injection of indocyanine green fluorescence during transanal total mesorectal excision to identify the plane of dissection: a video vignette. Colorectal Dis. 2017 Jun;19(6):599-600
57. Kim DH, Son GM, Kwon MS, Baek SH, Park BS, Kim HS. Educational benefits of intraoperative indocyanine green angiography for surgical beginners during laparoscopic colorectal surgery. J Minim Invasive Surg [Internet]. 2018 Mar; 21(1):25-30. Available from: https://www.e-jmis.org/journal/view.html?doi=10.7602/jmis.2018.21.1.25
58. Son GM, Kwon MS, Kim Y, Kim J, Kim SH, Lee JW. Quantitative analysis of colon perfusion pattern using indocyanine green angiography in laparoscopic colorectal surgery. Surg Endosc. 2019 May;33(5):1640-9
59. Park SH, Park HM, Baek KR, Ahn HM, Lee IY, Son GM. Artificial intelligence based real-time microcirculation analysis system for laparoscopic colorectal surgery. World J Gastroenterol. 2020 Nov;26(44):6945-62.
60. Kather JN, Pearson AT, Halama N, Jäger D, Krause J, Loosen SH, et al. Deep learning can predict microsatellite instability directly from histology in gastrointestinal cancer. Nat Med. 2019 Jul;25(7):1054-56.
61. Echle A, Grabsch HI, Quirke P, van den Brandt PA, West NP, Hutchins GGA, et al. Clinical-grade detection of microsatellite instability in colorectal tumors by deep learning. Gastroenterology. 2020 Oct;159(4):1406-1416.e11.
62. Mc Entee PD, Singaravelu A, Boland PA, Moynihan A, Creavin B, Cahill RA. Impact of indocyanine green fluorescence angiography on surgeon action and anastomotic leak in colorectal resections: a systematic review and meta-analysis. Surg Endosc. 2025 Mar;39(3):1473-89.
63. Maroli A, Paoluzzi Tomada E, Foppa C, Carvello M, Ris F, Hompes R, et al. Indocyanine green fluorescence to prevent anastomotic leak in colorectal surgery: an updated systematic review and meta-analysis on randomized controlled trials. Surg Endosc. 2026 Mar;40(3):1815-27.
64. Boalot A, Yau J, Hasan M, Wang X, Younes A, Hannah M, et al. Use of intraoperative ICG fluorescence angiography to reduce anastomotic leak in left-sided colorectal resections: a systematic review and meta-analysis of RCTs. Colorectal Dis [Internet]. 2026 Feb;28(2):e70378. Available from: https://onlinelibrary.wiley.com/doi/10.1111/codi.70378
65. Kapsampelis P, Calabrese EC, Kumar SS, Shehata D, Bansal V, Carsky K, et al. SAGES 2025 systematic review and meta-analysis for fluorescence image-guided gastrointestinal surgery using indocyanine green. Surg Endosc. 2025 Dec;39(12):7860-904.
66. Semeniv S, Pedziwiatr M, Rymarowicz J, Szpakowska A, Jurczak M, Putowski M, et al. Indocyanine green fluorescence angiography in laparoscopic sigmoid and rectal cancer surgery: no reduction in anastomotic leakage but a lower incidence of anastomotic strictures: a prospective single-center study. Front Surg [Internet] 2026;13:1822071. Available from: https://www.frontiersin.org/journals/surgery/articles/10.3389/fsurg.2026.1822071/full
67. Pavlidis L, Geropoulos G, Kechagias KS, Psarras K, Patel V, Reza L, et al. Near-infrared fluorescence with indocyanine green for minimally invasive hernia surgery: a systematic review and evidence synthesis. World J Clin Cases [Internet]. 2026 May;14(14):118964. Available from: https://www.wjgnet.com/2307-8960/full/v14/i14/118964

Review

Hell J Surg. 2025 Jul-Sep;95(3):127–139
doi: 10.59869/25073

Regenerative Therapies in Oral and Maxillofacial Surgery: Current Clinical Evidence

Marina Gkelsini[1], Elissavet Anestiadou[2], Orestis Ioannidis[1,2]

[1]MSc Program in Regenerative Medicine and Stem Cells, Aristotle University of Thessaloniki, Greece
[2]4th Department of General Surgery, General Hospital of Thessaloniki "G. Papanikolaou", Aristotle University of Thessaloniki, Thessaloniki, Greece

ABSTRACT

Background: Regenerative medicine is increasingly used in oral and maxillofacial surgery (OMFS), but clinical evidence remains heterogeneous. This review assessed reproducible clinical benefit, comparison with established reconstruction, and clinical maturity. **Objective:** To evaluate stem cell therapies, platelet-derived autologous biologics, and emerging regenerative technologies by indication, surgical role, comparative evidence, limitations, and readiness. **Methods:** PubMed/MEDLINE, Scopus, and Web of Science Core Collection were searched from 2010 onwards using "mesenchymal stem cells"/"mesenchymal stromal cells", "stem cell therapy", "oral and maxillofacial surgery", "craniofacial bone regeneration", "alveolar ridge preservation", "maxillary sinus augmentation", "alveolar cleft", "periodontal regeneration", "platelet-rich plasma", "platelet-rich fibrin", "advanced platelet-rich fibrin", "concentrated growth factors", "bone marrow aspirate concentrate", "secretome", "extracellular vesicles"/"exosomes", "biomaterials", and "3D bioprinting", with Medical Subject Headings (MeSH) terms "Mesenchymal Stem Cells", "Platelet-Rich Plasma", "Bone Regeneration", "Tissue Engineering", and "Maxillary Sinus Augmentation". Human evidence was prioritised, including randomised trials, systematic reviews, meta-analyses, and prospective studies; no formal risk-of-bias assessment or quantitative meta-analysis was performed. **Results:** PRF/PRP are clinically integrated adjuncts for selected indications, particularly soft-tissue healing. MSCs show clinical proof of concept, but evidence is limited by small cohorts, heterogeneous cell products, scaffold variability, and insufficient long-term comparative data. BMAC/CGF occupy an intermediate translational position, whereas secretome, extracellular vesicles/exosomes, advanced biomaterials, bioprinting, and AI-enabled platforms remain investigational. **Conclusions:** Regenerative therapies should complement, not replace, established reconstruction. Adoption depends on reproducible incremental benefit over contemporary standards and reduced donor-site morbidity, operative burden, treatment time, complications, or reconstructive failure.

Key words: *Regenerative medicine; mesenchymal stromal cells; platelet-rich fibrin; alveolar ridge preservation; maxillary sinus augmentation; clinical translation*

Corresponding author:
Marina Gkelsini
Aristotle University of Thessaloniki, Greece
Nikiforou Vrettakou St., 41335, Larissa, Greece
Tel.: +30 6942 615874,
e-mail: marina.gkel@gmail.com

Submission: 06.09.2026, Acceptance: 23.10.2026

INTRODUCTION

The originally laboratory-based concept of regenerative medicine is increasingly being applied in a selective clinical manner in the field of oral and maxillofacial surgery (OMFS). Translation of in vitro evidence for a biological product that can stimulate cells to improved reconstruction of OMFS defects in the clinical setting of patients is

hampered by a number of constraints including defect geometry, vascularity and surrounding soft tissues, risk of infection, functional loading and aesthetic requirements. Therefore, more than evidence of a biological product that can stimulate cells in vitro is needed by the surgeon. The only clinically relevant question is whether the intervention leads to an improvement in patient reconstruction compared with a modern surgical standard [1,2,3].

In addition to their potential for cell differentiation, mesenchymal stromal cells (MSCs) exert various effects through their paracrine actions, such as providing trophic support, modulating the immune system, and promoting angiogenesis [4,5]. Even a plausible mechanism of action does not necessarily translate into clinical superiority. Human studies investigating the treatment of defects in the oral cavity have been designed with substantial variability in several factors, including the type and processing of cells, cell number, type of scaffold, route of application, extent and type of oral cavity defect, clinical endpoint(s), and duration of follow-up [1,3,4,6,7].

Other types of translational models include autologous platelet concentrates. Although platelet-rich plasma (PRP) and platelet-rich fibrin (PRF) contain platelets, fibrin, growth factors, cytokines, and leukocytes from the patient, these are not expanded in culture before they are applied. Their relatively low logistical burden has facilitated their clinical adoption. It is the same field with a lot of variability in protocols. However, there is much more clinical value in selected end-point measures for healing, than in predictable de novo hard tissue formation [8,9,10,11,12,13,14].

The early clinical translation, established adjunctive care, and investigational approaches for each of the modalities are reviewed within the framework of five key questions. The five key questions used as a framework for this review of the various modalities are as follows: (1) where would you use it; (2) how would it be incorporated into the surgical procedure; (3) what benefit could reasonably be expected; (4) what is the strength of the clinical evidence; and (5) is the technology ready to change routine surgical practice?

REVIEW APPROACH AND EVIDENCE FRAMEWORK

The primary search terms included "mesenchymal stem cells", "mesenchymal stromal cells", "stem cell therapy", "oral and maxillofacial surgery", "craniofacial bone regeneration", "alveolar ridge preservation", "maxillary sinus augmentation", "alveolar cleft", "periodontal regeneration", "platelet-rich plasma", "platelet-rich fibrin", "advanced platelet-rich fibrin", "concentrated growth factors", "bone marrow aspirate concentrate", "secretome", "extracellular vesicles", "exosomes", "biomaterials", and "3D bioprinting"; the principal MeSH terms included "Mesenchymal Stem Cells", "Platelet-Rich Plasma", "Bone Regeneration", "Tissue Engineering", and "Maxillary Sinus Augmentation".

This review is part of a narrative search of the databases PubMed/MEDLINE, Scopus, and Web of Science Core Collection for English-language publications from 2010 onwards. During the manuscript revision process, the evidence base was updated by searching PubMed and publisher databases for relevant 2026 systematic reviews and meta-analyses. The highest-quality evidence was considered for inclusion in this manuscript. This consisted of randomised clinical trials, controlled clinical studies, systematic reviews, meta-analyses, and studies reporting clinically relevant outcomes.

In assessing the maturity of the evidence for the many different regenerative interventions currently under development, we have used clinical rather than purely biological criteria. Because regenerative interventions are highly heterogeneous, "clinically integrated" refers to a modality that can be used in an adjunctive fashion, added to established surgical procedures, and applied safely and effectively on the basis of sufficient clinical evidence. "Early clinical translation" refers to human studies that report on feasibility and preliminary efficacy, but do not provide sufficient evidence for routine clinical adoption. "Investigational" refers to approaches for which the available clinical evidence remains too limited, inconsistent, or immature to support their use in standard surgical practice. In this section, we will outline the principal categories through which clinical translation of regenerative therapies in OMFS can be assessed, and describe the general biological pathways that are involved in the clinical translation of regenerative therapies depicted in Figure 1.

A summary of the resulting clinical evidence framework and the current surgical readiness of the principal regenerative approaches across relevant OMFS indications is presented in Table 1. The table provides a clinically oriented overview of the best-supported human evidence, the principal reported clinical benefit, the major evidence limitations, and the current role of each regenerative strategy relative to established surgical treatment.

STEM CELL-BASED THERAPIES: WHERE DO THEY CURRENTLY FIT IN OMFS?

Stem cell-based regeneration should not be regarded as a single treatment. In clinical practice, the outcome depends on the cell source, processing, dose, scaffold, delivery method, defect environment, and the quality of the underlying surgical reconstruction. MSCs derived from bone marrow, adipose tissue, and dental-associated tissues

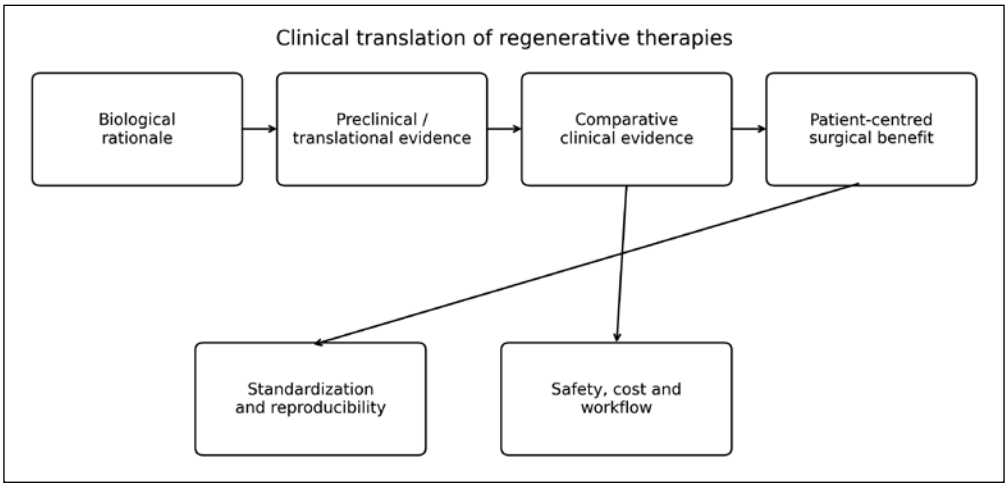

FIGURE 1. Clinical adoption requires convergence of evidence, reproducibility and meaningful surgical benefit.

TABLE 1. Clinical evidence and surgical readiness of regenerative approaches by indication.

Clinical indication	Regenerative strategy / surgical role	Comparator / standard treatment	Highest level of human evidence	Main reported benefit	Key evidence limitation	Current clinical role
Alveolar ridge augmentation	MSC/cell-enriched adjunct to graft or scaffold	Conventional grafting or scaffold-based augmentation	Small clinical studies and heterogeneous comparative evidence	Potential to enhance bone regeneration and reduce graft requirements in selected settings	Small, heterogeneous clinical studies; limited evidence of superiority over conventional grafting	Investigational / early clinical translation
Maxillary sinus augmentation	MSC-assisted grafting in a contained defect	Conventional sinus augmentation with grafting	Clinical studies and systematic/meta-analytic evidence	Human clinical feasibility; a 2026 meta-analysis found no significant implant-success advantage over conventional treatment [15]	Small RCT evidence base; heterogeneous protocols; clinical superiority not established	Early clinical translation
Periodontal regeneration	MSC-assisted regenerative periodontal surgery	Conventional periodontal regenerative therapy	Clinical studies and systematic review/ meta-analysis [16]	Improvements in selected periodontal parameters reported in clinical studies	Limited number of trials; variable cell sources, scaffolds, and clinical endpoints	Early clinical translation
Alveolar cleft / complex craniofacial defects	Cell + biomaterial reconstruction	Conventional bone grafting or reconstructive surgery	Small clinical study demonstrating feasibility of MSC-assisted alveolar cleft repair [17]	Feasibility of biologically enhanced reconstruction in complex defects	Small cohorts and limited long-term comparative data	Investigational
Extraction, ridge preservation and selected regenerative procedures	PRF / platelet concentrates as surgical adjuncts	Conventional healing or graft-based ridge preservation	Randomised clinical trials and systematic reviews [18,19]	Supportive effects on soft-tissue healing and selected postoperative or ridge-preservation outcomes	Protocol heterogeneity; inconsistent hard-tissue effects; not a predictable substitute for grafting	Clinically integrated adjunct in selected indications

Abbreviations: MSC = mesenchymal stromal cell; PRF = platelet-rich fibrin.

have been investigated because of their osteogenic, trophic, angiogenic, and immunomodulatory properties [3,4,5,6].

Alveolar ridge reconstruction

Indication and surgical role: The clinically relevant indication is a deficient alveolar ridge in which conventional augmentation would require substantial graft volume or a donor site. MSC-based approaches have been studied as cell-enriched grafting or scaffold-based adjuncts to provide osteogenic or pro-regenerative activity within a mechanically stable defect [1,3,7].

Expected benefit: There are more expected benefits to the proposed advantage (i.e. faster bone formation) than just that alone, including a reduced amount of autogenous graft required, enhanced biologic activity in the grafted area, and potentially improved regeneration of difficult defects. However, these advantages remain incompletely demonstrated in comparative human studies [1,3,6,7].

Most studies investigated the feasibility of MSC-based therapy for different defects using different cell preparations, carrier systems, and other protocols. Therefore, a direct comparison of MSC-based therapy with contemporary grafting was not possible. Recently, a systematic review and meta-analysis on clinical stem cell therapy for oral and craniofacial bone-regeneration procedures similarly found heterogeneous evidence. Stem-cell therapy improves histological bone quality and 3D radiographic bone volume but does not increase periodontal clinical attachment level or linear bone height/width above levels achieved by conventional therapy [15]. In summary, the evidence supports a clinical investigation rather than routine substitution of established augmentation techniques.

Surgical readiness: INVESTIGATIONAL/EARLY TRANSLATION. MSC-assisted alveolar reconstruction can be considered for cases treated in specialised centres within the framework of clinical trials. However, for alveolar reconstruction, MSC-assisted approaches should not replace established methods of autogenous, allogeneic, xenogeneic, or synthetic grafting solely on the basis of their regenerative potential.

Maxillary sinus augmentation

Indication and technique: Maxillary sinus augmentation is a clinical indication in which a contained 3D space is available for a biologically active graft. Subsequent protection and support of the graft by the surrounding tissue are required. Cell-assisted bone regeneration strategies have been investigated as adjuncts to grafting, with the aim of increasing bone formation while reducing the need for autogenous bone [7,20].

Comparative evidence: The randomised clinical trial by Kaigler et al. demonstrated the feasibility of enriched CD90+ bone marrow-derived stem cell therapy for maxillary sinus bone regeneration [20]. This is important proof-of-concept because it moves the field beyond laboratory findings; however, a single positive trial does not establish superiority across routine implant patients or different cell-processing systems. Of note is a systematic review and meta-analysis from 2026 consisting of 6 RCTs (74 patients, 222 implants) that investigated the success of implants grafted with MSCs in comparison to implants grafted with conventional grafting materials. There were no significant differences between the two groups (RR 0.98; 95% CI 0.94–1.03). For continuous bone-neoformation outcomes, the control group values for conventional augmentation were higher than those of the study group for MSC-assisted augmentation of the sinuses. However, for dichotomous bone-regeneration outcomes, there were no significant differences between the two groups of patients [21]. Therefore, MSC-assisted sinus augmentation remains a promising but unproven clinical strategy rather than an established replacement for conventional grafting.

Surgical interpretation: The evidence currently supports the use of sinus lift as a potential consideration for the further development of cell-based materials for clinical application. However, not all indications for bone grafting will be suitable for the use of cell-based materials. The additional requirements for cell harvesting, processing, regulatory considerations, and cost must be justified by a measurable clinical benefit.

Craniofacial and alveolar cleft reconstruction

Reconstruction of craniofacial defects is a significant translational challenge. In order to achieve adequate function of the reconstructed part, in addition to lasting structural support of the reconstructed skull, sufficient amounts of soft tissue must be provided to allow for successful rehabilitation. Human MSCs have been used to repair alveolar clefts and have demonstrated clinical feasibility [17]. However, there is not enough evidence to support cell-based therapy as the new gold standard of care.

Until sufficient data exist to establish MSC therapy as a stand-alone treatment within reconstructive algorithms, MSCs should be viewed as an adjunct under investigation to enhance the effects of established reconstructive algorithms.

Periodontal and peri-implant regeneration

Periodontal defects are complex and therefore difficult to close biologically. For successful regeneration of a periodontal defect, in addition to cementum, the periodontal ligament has to be regenerated and the alveolar bone has to be rebuilt. Isolated

bone fill is not sufficient. In probing depth, clinical attachment level, and radiographic parameters, clinical studies and systematic evidence have demonstrated potential improvements with MSC-based approaches in selected periodontal defects [7,16].

More importantly, for the practicing clinician, the question is whether adding cell therapy to thorough debridement, the selection of appropriate defects, the use of established periodontal regenerative membranes/scaffolds, and conventional periodontal regenerative surgery provides any additional benefit to the patient. To date, there is insufficient evidence to support the routine use of cell transplantation for the average periodontal patient. Therefore, such treatment would only be indicated for highly selected defects which are to be treated within controlled clinical investigations.

AUTOLOGOUS BIOLOGICS: THE MOST CLINICALLY ACCESSIBLE REGENERATIVE ADJUNCTS

Autologous biologics have a fundamentally different surgical value proposition from cell therapy. Intraoperative preparation of autologous biologic products usually does not add substantial operative complexity. Most established surgical procedures can incorporate autologous biologics after minor modification. Their clinical accessibility has facilitated their rapid adoption. However, this accessibility does not mean that they have proven efficacy. Finally, growth factors in PRP and PRF are able to create a better wound-healing environment, yet they are not able to create tissue with the necessary mechanical properties, cover a wound with vascularised tissue, achieve wound closure by proper management of a defect, or provide a sufficiently sized and sound graft of appropriate quality [8,9,10,12,13,14].

Platelet-rich plasma (PRP)

Indication and technique: For periodontal and other dental surgeries, including extraction socket healing, implant procedures, bone grafting and sinus lift. [8,10]

Expected benefit: Early soft-tissue healing and postoperative recovery can be accelerated or modulated by the action of platelet-derived growth factors (such as platelet-derived growth factor [PDGF], transforming growth factor-β [TGF-β], and vascular endothelial growth factor [VEGF]) in the early stages of healing. These are credible clinical endpoints rather than a predictable replacement of missing bone [8,9,12].

Limitations: The lack of standardisation of PRP preparation, i.e. the number of platelets, the number of leukocytes, the method of activation, the type and concentration of anticoagulant(s), centrifugation and application methods, results in different biological activities of PRP. Thus, results obtained with one PRP system may be difficult to extrapolate to another [9,11,12].

Surgical readiness: PRP is clinically integrated as an adjunct to support the clinical benefit anticipated from other treatments. It should be used when the expected supportive benefit justifies the additional preparation burden and should not be presented as an independent regenerative treatment.

Platelet-rich fibrin (PRF)

Indication and technique: PRF is produced without anticoagulants and forms a fibrin matrix containing platelets and leukocytes. Depending on the formulation, it can be used as a membrane, plug, clot or injectable preparation [8,9,11,12].

Expected benefit: The clinically attractive feature is the combination of biological mediator release with a manipulable fibrin matrix. Evidence is most consistent for soft-tissue healing, wound maturation, postoperative discomfort and selected extraction-socket outcomes [8,10,13,14].

Hard-tissue interpretation: PRF should not be equated with a structural bone graft. Meta-analytic evidence suggests benefits in selected hard- and soft-tissue endpoints, but results are heterogeneous and do not establish predictable large-volume bone reconstruction or superiority over established grafting strategies [12,14]. A 2026 systematic review and meta-analysis of randomised controlled trials found that PRF alone reduced alveolar ridge height loss at selected follow-up intervals compared with spontaneous healing, although the pooled ridge-height analysis showed substantial heterogeneity ($I^2 = 80\%$) [18]. More importantly for surgical decision-making, a 2026 meta-analysis published in the International Journal of Oral and Maxillofacial Surgery that directly compared PRF with bone grafts found greater ridge-height and ridge-width loss in the PRF groups, while bone density did not differ significantly [19]. Thus, PRF may improve healing and preserve dimensions relative to unassisted healing in selected settings, but current comparative evidence does not support treating PRF as equivalent to a structural graft for ridge preservation.

Surgical readiness: CLINICALLY INTEGRATED ADJUNCT. PRF is currently one of the most practical regenerative tools in OMFS, particularly when the surgical objective is to improve the early healing environment rather than to provide primary structural regeneration.

Standardisation is a surgical issue, not only a laboratory issue

Standardisation of promising biologicals is mandatory to make them useful in clinical practice as surgical procedures. Apparently similar interventions in oral and maxillofacial surgery can vary significantly according to the cell source, cell processing, dose, scaffold, platelet concentration, centrifugation force and duration, activation method, carrier material, defect characteristics, and timing of application. Such variability can substantially influence treatment outcomes and limits the reproducibility and interpretation of clinical evidence. There are several variables that can affect the biological composition and clinical effects of a final product. In summary, direct comparison between individual studies is often not possible, and therefore the reproducibility and transferability of the results obtained from single studies are limited. This is particularly relevant for platelet concentrates, which are prepared using substantially different methods and may consequently differ markedly in their biological composition and clinical effects despite being described using the same general terminology [9,11,12,13]. Surgical standardisation therefore extends to the full description of the clinical intervention that was performed under study conditions. The description of the regenerative product used has to be complete and include the preparation and processing of the regenerative product, as well as the use of additional materials. A complete description of the clinical intervention should also include the defect morphology, surgical technique, comparator treatment, timing of application, and clinically meaningful outcome measures. This level of reporting is essential to allow meaningful interpretation, comparison, and reproducibility of the results. For platelet concentrates, the following information needs to be consistently reported: relative centrifugal force, centrifugation time, tube type, platelet and white blood cell numbers, handling, activation, and delivery method. The consistent reporting of these parameters will allow for a more accurate assessment of the effects of a regenerative treatment. It will also allow the distinction between true treatment effects and effects related to the preparation protocol, patient selection, defect type, or surgical technique [9,11,12,13].

Evaluating current evidence for a regenerative product that causes measurable biological or radiographic effects under a specific set of circumstances does not necessarily translate to the same clinical benefit when the product is prepared differently or applied under different clinical conditions or for a different surgical indication. Consequently, terms such as PRP and PRF should not be interpreted as referring to biologically identical interventions across studies. The preparation protocol should be regarded as an integral part of the intervention itself, rather than as a secondary laboratory detail.

Standardisation of regenerative products is not only a matter for the laboratory. It is a prerequisite for reproducible surgical decisions and for meaningful comparative effectiveness research. It is a prerequisite for the integration of these therapies into the routine clinical practice of OMFS. It is crucial to consider any efficacy claims in the light of the specific preparation system, the specific surgical indication and the overall clinical protocol within which evidence of efficacy has been obtained.

Why promising regenerative therapies have not yet become standard surgical care

There are no interventions currently performed on a routine basis, as there is a lack of consistent evidence that they provide any clinical benefit over and above that already achieved by established methods of reconstructive surgery. Studies report improvements in histological, radiographic or early healing parameters. However, the translation of these improvements into reduced donor-site morbidity, fewer procedures, complications, and reoperations, shorter times to implant placement, etc. (true patient-centered outcomes) remains unclear. In the field of OMFS, even the smallest biological change is not worth the additional procedural complexity, cost and regulatory requirements.

A second set of barriers are related to the heterogeneity of the intervention. Most reports on the use of mesenchymal stem cells (MSCs), platelet-rich plasma (PRP) or platelet-rich fibrin (PRF) describe a variety of different products that are vastly different from each other with regard to the cell source, processing, dose, etc., whether or not they use a scaffold and differing in terms of centrifugation parameters, cellular composition, activation method, and delivery. Consequently, apparently similar interventions may not represent the same biological treatment across studies. This heterogeneity limits reproducibility and makes it difficult to determine whether apparently conflicting results reflect differences in biological efficacy or differences in the intervention itself. Standardised preparation and reporting are therefore necessary before findings can be generalised across centres, products, or surgical indications.

The comparative evidence is also incomplete. A 2026 systematic review and meta-analysis of clinical stem-cell therapy in oral and craniofacial bone regeneration found improvements in selected histological and volumetric outcomes, but no significant advantage over conventional

treatment for periodontal clinical attachment level or linear bone height and width [15]. Similarly, a 2026 systematic review and meta-analysis of MSC-assisted maxillary sinus augmentation found no significant difference in implant success compared with conventional grafting, despite evidence of clinical feasibility and biological activity [21]. Evidence from platelet-based ridge-preservation studies is likewise mixed. A 2026 meta-analysis found that PRF alone reduced alveolar ridge height loss compared with spontaneous healing, although substantial heterogeneity was reported, while a separate 2026 meta-analysis directly comparing PRF with bone grafts found greater ridge-height and ridge-width loss in the PRF groups, with no significant difference in bone density [18,19].

These findings do not indicate that regenerative therapies are ineffective. Rather, they show that biological activity and selected surrogate improvements have not yet translated consistently into superior surgical outcomes. The clinically relevant question is therefore not whether a regenerative intervention produces a measurable biological effect, but whether that effect is sufficiently large and reproducible to improve the outcome that would otherwise be achieved with contemporary reconstructive surgery.

A further limitation is the short duration and scale of many clinical studies. Small cohorts, single-centre designs, variable follow-up periods, and inconsistent outcome definitions make it difficult to determine whether early gains remain stable and whether they translate into durable functional benefit. For a surgical technology to become the standard of care, evidence should demonstrate reproducible performance across surgeons and patient populations, with adequate follow-up and direct comparison against the treatment that would otherwise be selected in routine practice.

Finally, clinical translation requires more than efficacy. A regenerative intervention must fit within the operative workflow, have a reproducible manufacturing or preparation process, maintain an acceptable safety profile, and provide a benefit large enough to justify its additional complexity and cost. In summary, while some of the autologous biologics can be used on a selective, indication-specific basis, most of the cell-based and engineered approaches are still in the early stages of clinical translation and investigation. The factors that will be considered in future trials are whether the treatments change any of the key decisions made by the surgeon for the patient and whether they affect any of the main outcomes of interest to patients.

Key differences between PRP and PRF exist that make a difference for clinical use. These differences affect the matrix formation, the release of mediators and the clinical outcomes that have been reported, while also influencing their handling and the way in which their effects are interpreted across different clinical studies. PRF has been studied more extensively in the available evidence base, particularly for soft-tissue healing, periodontal applications, postoperative management, and alveolar ridge preservation [8,9,10,13,14,18,19]. However, the available literature does not establish either PRP or PRF as universally superior, and clinical effects should remain linked to the specific preparation protocol and surgical indication. These differences and the principal evidence limitations are summarised in Table 2.

OTHER AUTOLOGOUS BIOLOGICS: CONCENTRATED GROWTH FACTOR (CGF) AND BONE MARROW ASPIRATE CONCENTRATE (BMAC)

Concentrated growth factor (CGF)

CGF is a modified platelet-derived preparation designed to generate a relatively dense fibrin matrix containing platelets, leukocytes and growth factors [22]. A scaffold and sustained release of biological mediators could be of value in a surgical context; however, to date there is no evidence to suggest that CGF is superior to PRF or other platelet concentrates. CGF is best used as an adjunctive, investigational tool until more clinical information is gathered and until the tool is translated into other forms of clinical use.

Surgical readiness: EARLY TRANSLATION. Early consideration for use in selected cases of regenerative surgery but need for comparative clinical trials to establish clinical benefit over other established platelet concentrates.

Bone marrow aspirate concentrate (BMAC)

BMAC is particularly relevant for the surgeon, as BMAC is a mix of cells and growth factors that do not need to go through prolonged ex vivo expansion. It contains a heterogeneous mixture of stromal/progenitor cells, growth factors, cytokines and other marrow-derived elements [4,20].

The distinction between BMAC and culture-expanded MSC therapy is clinically important. The randomised maxillary sinus study by Kaigler et al. evaluated enriched CD90+ bone marrow-derived cells rather than generic BMAC [20]. Therefore, evidence from that trial should not be used to imply that every BMAC preparation has the same efficacy.

Surgical readiness: EARLY TRANSLATION / INVESTIGATIONAL. BMAC may become attractive when a one-stage

TABLE 2. Direct clinical comparison of platelet-rich plasma (PRP) and platelet-rich fibrin (PRF) in oral and maxillofacial regenerative surgery.

Domain	Platelet-rich plasma (PRP)	Platelet-rich fibrin (PRF)	Clinical interpretation / evidence limitation
Preparation principle	Platelet-enriched plasma obtained after blood collection and centrifugation; preparation commonly involves anticoagulation and may include one- or two-step processing	Blood is centrifuged without anticoagulants, allowing formation of a fibrin matrix containing platelets and leukocytes [8,9,11]	Preparation protocols vary substantially among platelet concentrates, limiting direct comparison across studies [8,9,11]
Biological architecture	Predominantly a platelet-enriched plasma fraction that delivers platelet-derived mediators	Three-dimensional fibrin matrix that entraps platelets and leukocytes and provides a biologically active scaffold [8,9,12]	The structural distinction may influence retention and release kinetics, but biological differences should not automatically be interpreted as clinical superiority
Growth-factor release	Relatively rapid release of platelet-derived mediators following activation	Fibrin matrix provides a more sustained release environment for platelet-derived mediators [8,9,12]	Sustained release is a proposed biological advantage of PRF, although its clinical significance remains indication-dependent
Handling and surgical application	Can be applied as a liquid preparation or after activation and may be incorporated into grafting or regenerative procedures	Forms a fibrin clot or membrane that can be manipulated and adapted to the surgical site [8,9,10,13]	PRF may provide practical advantages where a membrane or stable fibrin matrix is desirable, whereas PRP may be advantageous where a liquid preparation is required
Soft-tissue healing	Platelet concentrates may support soft-tissue repair through delivery of platelet-derived mediators	Systematic evidence supports beneficial effects of PRF on soft-tissue wound healing [8,9]	Evidence is stronger for healing-related outcomes than for predictable hard-tissue regeneration
Postoperative pain and morbidity	May be used as a biological adjunct in selected surgical procedures	Clinical evidence supports reductions in postoperative morbidity in selected oral surgical procedures [13,14]	Magnitude of benefit depends on procedure, protocol, and outcome definition; evidence should not be generalised across all indications
Bone regeneration / ridge preservation	May be used as an adjunct to graft-based regenerative procedures	PRF has been investigated extensively for ridge preservation and bone-healing applications [10,12,14,18,19]	Recent systematic reviews support potential benefit in selected ridge-preservation outcomes, but PRF should not be considered a predictable replacement for bone grafting [18,19]
Periodontal regeneration	Platelet-based concentrates may be incorporated as adjuncts to periodontal regenerative procedures	PRF has demonstrated regenerative potential in periodontal applications [9,10,13]	Clinical outcomes remain heterogeneous and are influenced by defect characteristics, preparation protocol, and concomitant regenerative treatment
Fibrin matrix formation	Does not primarily rely on formation of a dense autologous fibrin scaffold	Formation of an endogenous fibrin matrix is a defining characteristic of PRF [8,9,11]	Fibrin architecture represents one of the principal biological differences between PRP and PRF
Need for exogenous anticoagulant	Commonly used during PRP preparation	Not required for conventional PRF preparation [11]	Avoidance of anticoagulants permits endogenous fibrin polymerisation during PRF preparation
Protocol standardisation	Considerable variation in platelet concentration, leukocyte content, activation methods, and centrifugation protocols	Also substantial variation among PRF formulations, centrifugation protocols, and preparation systems [11,13]	Protocol heterogeneity is a major limitation when comparing platelet-concentrate studies and interpreting pooled clinical evidence
Overall clinical position	Platelet-concentrate adjunct with potential application in selected regenerative and healing procedures	Clinically integrated adjunct with the strongest evidence in selected healing, periodontal, and ridge-preservation applications [8,10,13,14,18,19]	Neither PRP nor PRF should currently be regarded as a universal substitute for established grafting or reconstructive procedures

Abbreviations: PRP = platelet-rich plasma; PRF = platelet-rich fibrin.

autologous cellular approach can provide a measurable reduction in graft burden or donor-site morbidity, but current evidence is insufficient for routine use.

WHAT REGENERATIVE THERAPY CAN ACTUALLY CHANGE IN THE OPERATION?

The central surgical test is incremental value. A regenerative modality becomes clinically relevant when it changes an outcome that matters to the patient or surgeon, such as reducing autogenous graft harvesting or donor-site morbidity, decreasing the number of procedures, accelerating functional rehabilitation, improving the predictability of reconstruction, reducing complications or reoperation, or providing more durable restoration of tissue architecture. Even though biological activity, histological changes and radiographic improvements are good to know about when deciding on a treatment, they do not necessarily translate into clinically relevant results that demonstrate superiority to established surgical methods and techniques. In most current applications, regenerative technologies are best understood as adjuncts to sound surgical principles rather than binary alternatives to conventional reconstruction; they cannot compensate for inadequate vascularity, infection, poor soft-tissue coverage, instability, inappropriate defect selection, or inadequate space maintenance.

EMERGING TECHNOLOGIES: PROMISING, BUT NOT YET READY FOR ROUTINE SURGERY

Cell-free secretome therapies

The secretome of MSCs contains soluble mediators and extracellular vesicles that may reproduce part of the therapeutic effect of transplanted cells [23]. The attraction for surgery is obvious: a cell-free product could potentially reduce concerns related to cell survival, differentiation, manufacturing complexity and storage. However, the composition of the secretome is influenced by cell source and culture conditions, and standardised dosing and potency remain unresolved. Clinical evidence in OMFS is insufficient for routine use.

Extracellular vesicles and exosomes

Extracellular vesicles can transfer proteins, lipids and nucleic acids between cells and may provide a controllable mechanism for modifying inflammation, angiogenesis and tissue regeneration [24]. Their current limitations include isolation and characterisation, batch consistency, scalable manufacture, dosing, delivery, storage, regulatory classification and lack of robust human efficacy data. They should therefore remain within the scope of investigational research.

Advanced biomaterials and bioactive scaffolds

The next generation of scaffolds is designed not merely to occupy a defect but to provide mechanical support while presenting biochemical and structural cues to cells [25]. For OMFS, the clinically important opportunity is patient-specific reconstruction of complex defects where current grafting strategies are limited by volume, resorption or donor-site morbidity. At present, however, most advanced bioactive scaffolds lack the comparative human evidence required to replace established reconstructive materials.

Three-dimensional bioprinting

Three-dimensional bioprinting may ultimately allow patient-specific constructs containing cells, biomaterials and biological signals to be fabricated according to defect geometry [26]. However, a number of significant barriers have to be overcome, i.e. vascularisation, matureness of the printed construct, mechanical performance, manufacturing reproducibility and regulatory validation. Its present role in OMFS therefore remains experimental, and further research is required before it can be considered for routine clinical application.

Artificial intelligence and computational planning

Artificial intelligence (AI) and machine learning can indirectly help improve regenerative surgery by optimising scaffolds, analysing images, predicting tissue reactions and enabling patient-specific planning [27,28,29]. All of the above enabling technologies are not yet considered to be regenerative therapies. Clinical value will be established through prospective validation and comparison with external data sets, explainability, reproducibility and, most importantly, clinical outcomes.

PRACTICAL EVIDENCE-BASED RECOMMENDATIONS FOR THE OMFS SURGEON

For the OMFS surgeon, the current evidence supports a selective, indication-specific approach to the use of regenerative therapies in a selective and indication-specific manner rather than their routine use on the basis of biological plausibility. The relevant clinical question is whether an intervention, added to a current technique, has a reproducible, additive effect and whether this provides clinically meaningful benefits, such as improved healing, preserva-

tion of tissue dimensions, reduced donor-site morbidity, reduced graft requirements, fewer procedures, improved functional recovery, or greater predictability of reconstruction. Biological activity, histological changes, or radiographic improvements may support the treatment rationale, but should not be interpreted as evidence of clinical superiority in the absence of appropriate comparative data.

The current position of regenerative therapies can therefore be understood as a clinical-readiness continuum rather than as a binary distinction between effective and ineffective treatments. At one end are investigational approaches for which human clinical evidence remains limited or insufficient for routine surgical use; intermediate positions include technologies in early clinical translation, where clinical feasibility has been demonstrated but comparative evidence remains incomplete; and at the clinically integrated end are selected adjunctive approaches that can be incorporated into established surgical workflows with a relatively defensible evidence and safety profile (Figure 2). This continuum reflects not only the presence of biological activity, but also the consistency of human evidence, reproducibility of the intervention, comparative effectiveness, and the extent to which a technology can provide a meaningful incremental benefit over contemporary surgical care.

PRF and selected platelet-concentrate applications currently occupy the clinically integrated end of this continuum because they can be incorporated into established surgical workflows with relatively limited additional complexity. Here, as with the other approaches, their role is as an adjunct to indication-specific therapy and they should not be seen as alternatives to structural grafts for substantial 3D reconstruction [8,9,12,14,18,19]. Of note, MSC-based therapies and CGF are described at earlier stages of clinical translation, reflecting satisfying biological activity and clinical feasibility, but their clinical translation remains limited by insufficient comparative evidence, variability in preparation and application protocols, and the need for more consistent evidence of clinically meaningful benefit [1,7,15,16,20,21,22]. BMAC is considered to be under investigation within the current evidence framework, largely due to the lack of modality-specific clinical evidence to establish routine efficacy and comparative superiority to other available therapies. Therefore, cell-free secretome and extracellular vesicle-based therapies, as well as advanced biomaterials and three-dimensional bioprinting, remain predominantly investigational and should currently be restricted to appropriately designed clinical or translational research [11,23,24,25,26]. Enabling technologies, such as AI and computational tools, may support regenerative treatments; however, their clinical impact has not yet been prospectively validated [27,28,29].

The clinical-readiness continuum does not represent a hierarchy between therapies. Instead, every modality is located on the continuum according to the specific clinical indication. For now, a modality that is sufficiently integrated for a certain healing indication may remain investigational for other applications, such as structural reconstruction. Its position may also change as comparative clinical evidence accumulates, and apparent biological or radiographic benefits should not automatically be interpreted as evidence of a higher level of clinical readiness. Thus, the choice of a regenerative intervention must correspond to the specific surgical problem and must complement established reconstructive options in an optimal fashion.

In reality, any expected clinical benefit must be proportionate to the additional time, increased complexity, costs, and approval requirements associated with the respective procedure. The preparation and delivery protocols must be standardised and described in sufficient detail to allow adequate interpretation and reproducibility of the results. The absence of demonstrated superiority should not be interpreted as evidence of no biological or clinical value; rather, the strength and scope of any claimed benefit should remain linked to the specific indication, preparation protocol, comparator, and outcome for which evidence exists. The clinical-readiness matrix in Table 3 provides a practical summary of this evidence-based position.

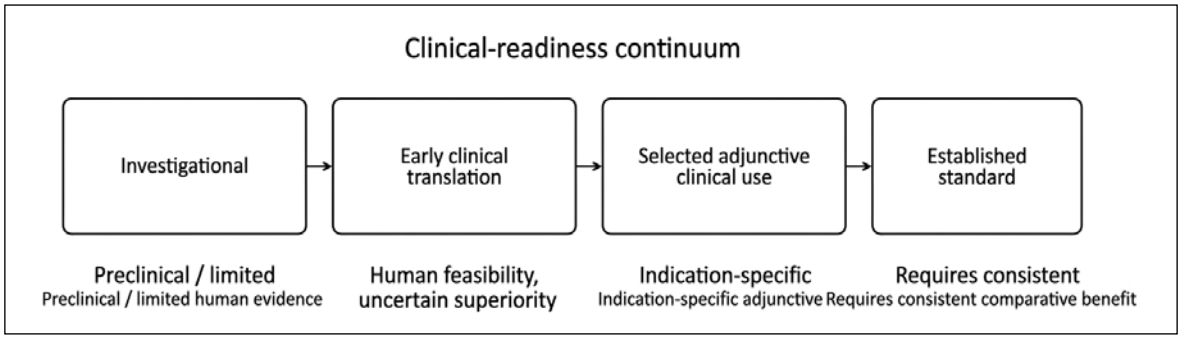

FIGURE 2. Movement to the right requires reproducible comparative evidence, safety and patient-centred benefit.

TABLE 3. Selected regenerative modalities of major regenerative modalities in oral and maxillofacial surgery.

Regenerative modality	Principal therapeutic rationale	Human clinical evidence	Main clinical signal	Key evidence limitation	Translational maturity	Current clinical position
Mesenchymal stromal/stem cells (MSCs)	Cell-based osteogenic, angiogenic and immunomodulatory regeneration, generally combined with grafts or scaffolds [1,3,4,6]	Clinical studies and systematic reviews across selected OMFS indications [7,15,16,17,20,21]	Clinical feasibility and potential improvement in bone and periodontal regeneration in selected indications	Small and heterogeneous trials; variable cell sources, processing methods, scaffolds, dosing and outcome measures; limited evidence of superiority over standard treatment [1,7,15,16,21]	Early clinical translation	Investigational adjunct; not established as a routine replacement for conventional grafting
Platelet-rich plasma (PRP)	Autologous delivery of platelets and growth factors to support healing and tissue regeneration	Clinical evidence from platelet-concentrate literature	Potential benefit in selected healing and regenerative applications	Substantial variation in platelet concentration, leukocyte content, activation and preparation protocols; inconsistent hard-tissue outcomes	Clinically integrated in selected applications	Adjunctive modality; indication-specific
Platelet-rich fibrin (PRF)	Autologous fibrin-based matrix providing platelets, leukocytes and growth factors within a three-dimensional scaffold [8,9,11,12]	Multiple clinical studies, systematic reviews and recent meta-analyses [10,13,14,18,19]	Clinical signal for improved soft-tissue healing and selected postoperative, periodontal and ridge-preservation outcomes	Protocol heterogeneity and variable clinical endpoints; evidence does not support predictable substitution for grafting [18,19]	Clinically integrated	Clinically integrated adjunct in selected oral and maxillofacial procedures
Concentrated growth factor (CGF)	Autologous platelet concentrate with a dense fibrin network and concentrated growth factors [22]	Mainly biological and limited clinical evidence	Potential regenerative and healing effects in oral and maxillofacial applications	Limited high-level comparative evidence; heterogeneous preparation protocols; insufficient long-term clinical data	Early clinical translation	Emerging adjunctive modality
Bone marrow aspirate concentrate (BMAC)	Delivery of autologous marrow-derived cellular and trophic components to support bone regeneration	Limited modality-specific evidence within the present reference set	Biological rationale and potential role as a cell-enriched adjunct to graft-based reconstruction	Insufficient modality-specific clinical evidence to establish efficacy or comparative superiority	Investigational	Experimental / investigational adjunct
MSC secretome / conditioned medium	Cell-free delivery of soluble paracrine factors with regenerative and immunomodulatory activity [23]	Predominantly preclinical and translational evidence	Strong biological rationale and regenerative potential without direct transplantation of viable cells	Variable secretome composition; lack of standardised production, dosing, potency assessment and clinical validation [23]	Investigational	Experimental; not established for routine surgical use
Extracellular vesicles (EVs) / exosome-based approaches	Cell-free delivery of proteins, lipids and nucleic acids mediating paracrine regenerative effects [24]	Predominantly preclinical evidence	Promising biological potential for tissue repair and regeneration	Major challenges in isolation, characterisation, dose definition, potency testing, standardisation and clinical translation [24]	Investigational	Experimental; not established for routine clinical use

Abbreviations: MSC = mesenchymal stromal cell; PRP = platelet-rich plasma; PRF = platelet-rich fibrin; CGF = concentrated growth factor; BMAC = bone marrow aspirate concentrate; EVs = extracellular vesicles.

FUTURE RESEARCH PRIORITIES

Future studies should be designed around surgical decision-making rather than biological novelty. First, randomised trials should compare regenerative interventions directly with the current standard of care, not only with no treatment. Second, protocols should report the complete intervention—cell source and dose, preparation method, scaffold, centrifugation parameters, defect characteristics and surgical technique—so that results are reproducible [9,11,12].

Third, outcomes should prioritise patient-centred and surgical endpoints: donor-site morbidity, operative time, number of procedures, complications, implant placement readiness, functional recovery, reoperation, long-term volumetric stability and cost-effectiveness. Fourth, follow-up should be long enough to determine whether an early radiographic or healing advantage persists. Finally, multicentre studies are needed to determine whether apparently promising technologies remain effective across different surgeons, patient populations and defect types.

The decisive research question should therefore be: does the regenerative intervention produce an incremental benefit large enough to justify its additional cost, complexity, regulatory burden and impact on the operative workflow? Technologies that cannot answer this question are unlikely to change routine OMFS practice regardless of their mechanistic sophistication.

CONCLUSION

Oral and maxillofacial surgery is increasingly being combined with regenerative medicine. However, the clinical maturity of the different treatments is very heterogeneous. The most clinically integrated approaches are autologous platelet concentrates, such as PRF, used as adjuncts for healing and selected regenerative indications, whereas MSC-based therapies, BMAC, and CGF remain at earlier stages of clinical translation. Cell-free and engineered approaches remain predominantly investigational. Across these modalities, biological plausibility alone is insufficient to justify replacing established reconstructive strategies.

The most clinically relevant future advances will therefore be those that demonstrate a reproducible and meaningful incremental benefit over contemporary surgical standards, particularly through reduction of donor-site morbidity, operative burden, number of procedures, complications, or reconstructive failure. Until such advantages are demonstrated in adequately designed comparative clinical studies, regenerative therapies should be adopted selectively, according to indication-specific evidence and clinical readiness, and used to complement rather than replace established surgical principles.

Acknowledgements: *The author acknowledges Dr Orestis Ioannidis for supervision and academic guidance.*

Author Contributions: *Marina Gkelsini: Conceptualization, literature search, evidence synthesis, and writing—original draft. Elissavet Anestiadou: Writing—review and editing, critical revision, and refinement of the manuscript. Orestis Ioannidis: Supervision, writing—review and editing, critical revision, and refinement of the manuscript. All authors have read and approved the final version of the manuscript.*

Funding: *No external funding was received for this work.*

Conflict of Interest: *The author declares no conflict of interest.*

Ethics Approval: *Not applicable. This article is a review of published literature and does not involve human participants or identifiable patient data.*

REFERENCES

1. Hung M, Sadri M, Katz M, Schwartz C, Mohajeri A. A systematic review of stem cell applications in maxillofacial regeneration. Dent J (Basel). 2024 Sep;12(10):315. Doi:10.3390/dj12100315.
2. Mao AS, Mooney DJ. Regenerative medicine: current therapies and future directions. Proc Natl Acad Sci U S A. 2015 Nov;112(47):14452–9. Doi:10.1073/pnas.1508520112.
3. Kaigler D, Pagni G, Park CH, Braun TM, Holman LA, Yi E, et al. Stem cell therapy for craniofacial bone regeneration: a randomized, controlled feasibility trial. Cell Transplant. 2013;22(5):767-77. Doi:10.3727/096368912X652968.
4. Pittenger MF, Discher DE, Peault BM, Phinney DG, Hare JM, Caplan AI. Mesenchymal stem cell perspective: cell biology to clinical progress. NPJ Regen Med [Internet]. 2019 Dec;4:22. Available from: https://pubmed.ncbi.nlm.nih.gov/31815001/ Doi:10.1038/s41536-019-0083-6.
5. Caplan AI. Mesenchymal stem cells: time to change the name. Stem Cells Transl Med. 2017 Jun;6(6):1445–51. Doi:10.1002/sctm.17-0051.
6. Oryan A, Kamali A, Moshiri A, Baghaban Eslaminejad M. Role of mesenchymal stem cells in bone regenerative medicine: what is the evidence? Cells Tissues Organs. 2017;204(2):59–83. Doi:10.1159/000469704.
7. Dipalma G, Marinelli G, Palumbo I, Guglielmo M, Riccaldo L, Morolla R, et al. Mesenchymal stem cells in oral and maxillofacial surgery: A systematic review of clinical applications and regenerative outcomes. J Clin Med. 2025 May;14(11):3623. Doi:10.3390/jcm14113623.
8. Miron RJ, Fujioka-Kobayashi M, Bishara M, Zhang Y, Hernandez M, Choukroun J. Platelet-rich fibrin and soft tissue wound healing: a systematic review. Tissue Eng Part B Rev.

2017 Feb;23(1):83–99. Doi:10.1089/ten.TEB.2016.0233.
9. Castro AB, Meschi N, Temmerman A, Pinto N, Lambrechts P, Teughels W, et al. Regenerative potential of leucocyte- and platelet-rich fibrin. Part A: intra-bony defects, furcation defects and periodontal plastic surgery. A systematic review and meta-analysis. J Clin Periodontol. 2017;44(1):67-82. Doi:10.1111/jcpe.12643.
10. Pereira VBS, Barbirato DS, Lago CAP, Vasconcelos BCE. The effect of advanced platelet-rich fibrin in tissue regeneration in reconstructive and graft surgery: systematic review. J Craniofac Surg. 2023 Jun;34(4):1217–21. Doi:10.1097/SCS.0000000000009328.
11. Choukroun J, Ghanaati S. Reduction of relative centrifugation force within injectable platelet-rich-fibrin (PRF) concentrates advances patients' own inflammatory cells, platelets and growth factors: the first introduction to the low speed centrifugation concept. Eur J Trauma Emerg Surg. 2017 Mar;44(1):87–95. Doi: 10.1007/s00068-017-0767-9
12. Jia K, You J, Zhu Y, Li M, Chen S, Ren S, et al. Platelet-rich fibrin as an autologous biomaterial for bone regeneration: Mechanisms, applications, optimization. Front Bioeng Biotechnol [Internet]. 2024 Apr;12:1286035. Available from: https://pubmed.ncbi.nlm.nih.gov/38689760/ Doi:10.3389/fbioe.2024.1286035.
13. Chmielewski M, Pilloni A, Adamska P. Application of advanced platelet-rich fibrin in oral and maxillo-facial surgery: a systematic review. J Funct Biomater. 2024 Dec;15(12):377. Doi:10.3390/jfb15120377.
14. Hajibagheri P, Basirat M, Tabari-Khomeiran Z, Asadi-Aria A. The efficacy of platelet-rich fibrin (PRF) in post-extraction hard and soft tissue healing and associated complications: a systematic review and meta-analysis of split-mouth randomized clinical trials. BMC Oral Health. 2025 May;25:869. Doi:10.1186/s12903-025-06238-1.
15. Hazrati P, Alanazi A, Alrmali AE, Galindo-Fernandez P, Kassem H, Kaigler D. Clinical stem cell therapy in oral and craniofacial bone regeneration: a systematic review and meta-analysis. Front Bioeng Biotechnol [Internet]. 2026 Jan;14:1677400. Doi:10.3389/fbioe.2026.1677400. Available from: https://pubmed.ncbi.nlm.nih.gov/41658988/
16. Sun L, Du X, Kuang H, Sun H, Luo W, Yang C. Stem cell-based therapy in periodontal regeneration: a systematic review and meta-analysis of clinical studies. BMC Oral Health. 2023 Jul;23(1):492. Doi:10.1186/s12903-023-03186-6.
17. Behnia H, Khojasteh A, Soleimani M, Tehranchi A, Khoshzaban A, Keshel SH. Secondary repair of alveolar clefts using human mesenchymal stem cells. Oral Surg Oral Med Oral Pathol Oral Radiol Endod. 2009;108(2). Doi:10.1016/j.tripleo.2009.03.040.
18. Yan J, Lu K. The efficacy of platelet-rich fibrin in alveolar ridge preservation: a systematic review and meta-analysis of randomized controlled trials. Front Med (Lausanne) [Internet]. 2026 Feb;13:1753189. Available from: https://pubmed.ncbi.nlm.nih.gov/41797764/ Doi:10.3389/fmed.2026.1753189.
19. Mahardawi B, Jiaranuchart S, Damrongsirirat N, Arunjaroensuk S, Yaklai S, Pimkhaokham A. Platelet-rich fibrin versus bone grafts for alveolar ridge preservation: A systematic review and meta-analysis of randomized clinical trials. Int J Oral Maxillofac Surg. 2026 Aug;55(8):960–8. Doi:10.1016/j.ijom.2026.03.012.
20. Kaigler D, Avila-Ortiz G, Travan S, Taut AD, Padial-Molina M, Rudek I, et al. Bone engineering of maxillary sinus bone deficiencies using enriched CD90+ stem cell therapy: A randomized clinical trial. J Bone Miner Res. 2015 Jul;30(7):1206–16. Doi:10.1002/jbmr.2464.
21. Coronel-Zubiate FT, Marroquín-Soto C, Luján-Valencia SA, Meza-Málaga JM, Luján-Urviola E, Aguirre-Ipenza R, et al. Can mesenchymal stem cells improve bone regeneration in maxillary sinus augmentation? A systematic review and meta-analysis. Stem Cells Int [Internet]. 2026 Jan;2026:6656563. Available from: https://pubmed.ncbi.nlm.nih.gov/41561408/ Doi:10.1155/sci/6656563.
22. Rodella LF, Favero G, Boninsegna R, Buffoli B, Labanca M, Scari G, et al. Growth factors, CD34 positive cells, and fibrin network analysis in concentrated growth factors fraction. Microsc Res Tech. 2011 Aug;74(8):772–7. Doi:10.1002/jemt.20968.
23. Vizoso FJ, Eiro N, Cid S, Schneider J, Perez-Fernandez R. Mesenchymal stem cell secretome. Int J Mol Sci. 2017 Aug;18(9):1852. Doi:10.3390/ijms18091852.
24. Pegtel DM, Gould SJ. Exosomes. Annu Rev Biochem. 2019 Jun;88:487–514. Doi:10.1146/annurev-biochem-013118-111902.
25. O'Brien FJ. Biomaterials and scaffolds for tissue engineering. Mater Today. 2011 Mar;14(3):88–95. Doi:10.1016/S1369-7021(11)70058-X.
26. Murphy SV, Atala A. 3D bioprinting of tissues and organs. Nat Biotechnol. 2014 Aug;32:773–785. Doi:10.1038/nbt.2958.
27. Gharibshahian M, Torkashvand M, Bavisi M, Aldaghi N, Alizadeh A. Recent advances in artificial intelligent strategies for tissue engineering and regenerative medicine. Skin Res Technol [Internet]. 2024 Sep;30(9):e70016. Available from: https://onlinelibrary.wiley.com/doi/10.1111/srt.70016 Doi:10.1111/srt.70016.
28. Jeznach O, Tabakoglu S, Zaszczyńska A, Sajkiewicz P. Review on machine learning application in tissue engineering: what has been done so far? Application areas, challenges, and perspectives. J Mater Sci [Internet]. 2024;59:21222–50. Available from: https://link.springer.com/article/10.1007/s10853-024-10449-2 Doi:10.1007/s10853-024-10449-2.
29. Wu Y, Ding X, Wang Y, Ouyang D. Harnessing the power of machine learning into tissue engineering: current progress and future prospects. Burns Trauma [Internet]. 2024 Dec;12:tkae053. Available from: https://pubmed.ncbi.nlm.nih.gov/39659561/ Doi:10.1093/burnst/tkae053.

Review

Hell J Surg. 2025 Jul-Sep;95(3):140–144
doi: 10.59869/25074

The Role of Physiotherapy in Enhanced Recovery After Surgery for Lung Cancer: A Narrative Review

Eleni Paskalidi[1], Stella Miraka[1], Georgia Kamparoudi[1], Pagona Kamparoudi[2], Dimitrios Lytras[3], Paris Iakovidis[3], Ilias Kallistratos[3]

[1]Department of Physiotherapy, Faculty of Health Sciences, International Hellenic University, Alexander Campus, Sindos, Thessaloniki, Greece

[2]"Theagenio" Cancer Hospital of Thessaloniki, Thessaloniki, Greece

[3]Laboratory of Basic and Applied Research in Physiotherapeutic Rehabilitation, Department of Physiotherapy, Faculty of Health Sciences, International Hellenic University, Alexander Campus, Sindos, Thessaloniki, Greece

ABSTRACT

Introduction: Enhanced Recovery After Surgery (ERAS) is a multimodal approach to the perioperative care of patients undergoing surgery for lung cancer. Physiotherapy can support both preoperative preparation and postoperative functional recovery. However, its contribution must be distinguished from the impact of the overall ERAS program. **Aim:** The aim of this narrative review is to present the contribution of prehabilitation, respiratory physiotherapy, early mobilisation, and subsequent functional rehabilitation to the perioperative care of lung cancer patients, distinguishing the individual interventions from the comprehensive ERAS program. **Methods:** A narrative review was conducted involving searches of the PubMed and PEDro databases and the ScienceDirect platform between April 12 and September 8, 2025. Publications regarding perioperative recovery and ERAS were reviewed, including the 2019 ERAS Society/ESTS guidelines. The literature was examined regarding preoperative preparation, postoperative rehabilitation, and the relationship between physiotherapy interventions and the overall ERAS program. **Results:** A literature search indicated that therapeutic exercise can improve the functional capacity of lung cancer patients. ERAS programs have been associated with fewer postoperative complications and shorter hospital stays, although these benefits cannot be attributed solely to physiotherapy. The heterogeneity of patient populations and interventions limits the ability to formulate standardised recommendations. **Conclusions:** Physiotherapy can contribute to the perioperative functional rehabilitation of lung cancer patients when integrated into personalised, multidisciplinary care. Further studies are needed to clarify the contribution of specific physiotherapy interventions and their appropriate dosage within the ERAS framework.

Key words: *Lung cancer; physiotherapy; enhanced recovery after surgery; ERAS*

Corresponding author:
Georgia Kamparoudi, PT, PhD, MSc
Lecturer in Physiotherapy, Department of Physiotherapy, Faculty of Health Sciences, International Hellenic University
Alexander Campus, P.O. Box 141
GR-57400 Sindos, Thessaloniki, Greece
Tel.: +30 699 841 8449, e-mail: geokamp@hotmail.com

Submission: 05.09.2026, Acceptance: 24.10.2026

INTRODUCTION

Enhanced Recovery After Surgery (ERAS) protocols constitute a multimodal approach to perioperative care, combining interventions before, during, and after the procedure. In lung surgery, the guidelines from the ERAS Society and the European Society of Thoracic Surgeons (ESTS) encompass preoperative education and prepara-

tion, optimisation of analgesia, management of drains and catheters, and early mobilisation. Physiotherapy contributes to this coordinated care, although it is not synonymous with the overall ERAS program [1].

Implementing ERAS requires collaboration among surgeons, anaesthesiologists, nurses, physiotherapists, and other healthcare professionals, depending on the patient's needs. Preoperative physiotherapy aims to improve functional reserve before surgery, while postoperative physiotherapy supports respiratory care, mobilization, and functional recovery. These interventions are an integral part of ERAS protocols and do not constitute a comprehensive program on their own [2,3].

The surgical management of lung cancer involves varying extents of pulmonary resection, such as segmentectomy, lobectomy, or pneumonectomy. Resection may be performed via open thoracotomy or through a minimally invasive approach, such as video-assisted thoracoscopic surgery or robotic surgery. These surgical approaches are related to the risk of mortality and morbidity due to potential postoperative complications.

Preoperative physiotherapy can improve the patient's functional capacity and support their preparation for the procedure [4]. However, there is no evidence that it alone ensures the safety of the procedure or reduces postoperative mortality. The primary goal is to improve clinical parameters such as dyspnoea, cardiorespiratory endurance, and functional recovery, with the principal objective being the patient's smooth reintegration into daily life.

Critical components of postoperative rehabilitation within ERAS protocols include early mobilisation and early oral feeding within the first 24 hours, as well as the effective management of tubes and catheters, with an emphasis on their prompt removal. From a physiotherapy perspective, early mobilisation, muscle strengthening, and functional reintegration into daily activities constitute the core elements of rehabilitation [1]. Prolonged immobilisation results in muscle weakness, decreased muscle mass, respiratory difficulties, complications such as atelectasis, and pneumonia, as well as an increased risk of venous thromboembolic events [1].

Early mobilisation is an integral part of postoperative care within ERAS; however, the benefits of comprehensive ERAS programs cannot be attributed solely to mobilisation, nor does evidence support an independent reduction in mortality resulting from this intervention [1,2].

METHODOLOGY

This paper presents a narrative review of the literature regarding the contribution of physiotherapy to the perioperative care of patients undergoing lung cancer surgery, focusing on the relationship between specific interventions and the overall ERAS program. The literature search was conducted between April 12 and September 8, 2025, using the PubMed and PEDro databases and the ScienceDirect platform. The combination of terms "lung cancer AND physiotherapy AND enhanced recovery after surgery" was used. The publication timeframe was limited to the period 2020–2025. An exception was made for the lung cancer management guideline developed by the ERAS Society, published in 2019, which was included for analysis due to its clinical relevance. This guideline was collected from the ERAS Society website: https://erassociety.org/ "Guidelines for enhanced recovery after lung surgery: recommendations of the Enhanced Recovery After Surgery (ERAS) Society and the European Society of Thoracic Surgeons (ESTS)"

The selection focused on English-language publications concerning perioperative physiotherapy, preoperative physiotherapy, and ERAS in the surgical management of lung cancer. Sources concerning broader oncological rehabilitation and general background were also utilised; these sources provided supplementary context and were not considered direct evidence of the effectiveness of physiotherapy interventions within ERAS. Selection was limited to publications with freely available full text, and articles were excluded due to a lack of access. This limitation may introduce availability bias and does not constitute a scientific criterion of relevance or quality. Initially, 26 publications were reviewed, including the 2019 ERAS Society/ESTS guidelines and general background sources. This narrative synthesis focuses on the publications cited and discussed in the final text. Duplicates were identified and removed using Mendeley. A complete record of the initial results and exclusions was not retained; therefore, numerical data regarding the successive selection stages are not presented.

The selection of publications was carried out by a single researcher, without an independent second check. No standardised assessment of methodological quality or risk of bias was performed. These limitations are taken into account when interpreting the findings of the narrative review. Eventually, for the collection of general anatomical information and background data regarding lung cancer, additional information was collected from the book ABC of Lung Cancer [5].

RESULTS

The role of physiotherapy in the eras protocol in lung cancer

Preoperative Management

Physiotherapy is an essential part of the ERAS proto-

TABLE 1. Key publications on perioperative rehabilitation and ERAS in lung cancer surgery.

Publication	Design and population	Intervention and comparator	Main findings or recommendations	Relationship to ERAS and interpretation
Batchelor et al., 2019	ERAS Society/ESTS clinical practice guidelines for lung surgery; not an individual clinical trial.	Multimodal perioperative care, including prehabilitation for high-risk patients, analgesia, chest-drain management and early mobilization.	Recommendations support coordinated interventions to facilitate recovery; they do not represent outcomes from a single physiotherapy programme.	Directly addresses ERAS. Physiotherapy is one component of the overall pathway.
Ferreira et al., 2021	Randomised controlled trial: 124 patients randomised; final cohort of 95 patients undergoing lung cancer surgery.	Multimodal prehabilitation initiated four weeks before surgery versus multimodal postoperative rehabilitation.	Prehabilitation was as effective as postoperative rehabilitation in restoring functional capacity.	Both groups received care within an enhanced recovery pathway. The trial did not compare ERAS with conventional care or physiotherapy with no physiotherapy.
Goldsmith et al., 2021	Prospective observational study involving 216 patients with lung cancer.	Pulmonary prehabilitation, with assessments before and after the intervention and postoperative comparisons between risk subgroups.	Improvements were observed in dyspnoea, performance status and frailty. In the high-risk subgroup defined by dyspnoea and performance status, 52.6% became eligible for surgery and 42.8% subsequently underwent surgery.	Addresses preoperative optimization. The observational design does not establish an independent causal effect on mortality.
Li et al., 2021	Systematic review and meta-analysis of 21 studies involving 6,480 patients.	Multimodal ERAS programmes versus conventional perioperative care in lung cancer surgery.	Lower postoperative complication risk and shorter hospital stay; no significant reduction in in-hospital mortality or readmission rates.	Findings concern the complete ERAS pathway and do not isolate the contribution of physiotherapy.

The table presents selected publications directly relevant to perioperative rehabilitation and ERAS. Guidelines, randomised trials, observational studies and meta-analyses provide different types of evidence and should not be regarded as equivalent. Publications used for general background or broader cancer rehabilitation are not included.

Abbreviations: ERAS, Enhanced Recovery After Surgery; ESTS, European Society of Thoracic Surgeons.

col, as it aims to enhance patient recovery. Preoperative physiotherapy aims to improve functional capacity and prepare the patient for surgery. Findings regarding multimodal prehabilitation do not allow for the isolation of physiotherapy's contribution, nor do they substantiate an independent reduction in postoperative mortality [4].

The prospective observational study by Goldsmith and colleagues examined 216 patients with lung cancer participating in a pulmonary prehabilitation program. Following the intervention, improvements were observed in dyspnoea, functional status, frailty, and activity levels [6]. In the high-risk patient subgroup—defined based on dyspnoea and functional status—52.6% were deemed suitable for surgery following prehabilitation, and 42.8% ultimately underwent surgery. These figures pertain to the specific subgroup rather than the total cohort of 216 participants. The study design does not allow the change in surgical suitability to be causally attributed solely to the intervention [6].

Prehabilitation may be of particular importance for patients with limited cardiopulmonary reserve, chronic obstructive pulmonary disease, frailty, or low exercise tolerance. The need for and content of the intervention should be determined by the preoperative assessment rather than being considered identical for all patients. ERAS/ESTS guidelines recommend considering prehabilitation for patients with borderline pulmonary function or exercise capacity [1].

The randomised study by Ferreira et al. compared multimodal prehabilitation—initiated four weeks prior to surgery—with multimodal postoperative rehabilitation within an enhanced recovery pathway. Prehabilitation was equally effective regarding the recovery of functional capacity. The study did not compare physiotherapy against the absence of physiotherapy, nor did it isolate its effect from the other components of the multimodal intervention [4].

Preoperative physiotherapy aims to prepare the patient for the demands of the surgery, although its independent effect on postoperative mortality has not been established.

Surgical procedures, whether major or minimally invasive, may lead to postoperative complications. Lobectomy refers to the removal of a lung lobe and can be performed via open thoracotomy or a minimally invasive approach, such as video-assisted thoracoscopic surgery or robotic surgery. Therefore, the term "minimally invasive" refers to the surgical approach rather than the lobectomy "itself" [1].

Postoperative Management

Postoperative complications are common following thoracic surgery, and the implementation of preoperative physiotherapy has demonstrated promising outcomes in reducing their incidence. Structured postoperative physiotherapy can support functional recovery and the return to daily activities through personalised intervention programs tailored to patients' clinical conditions and needs. Patients' abilities and endurance need to be assessed to include them in a program that will benefit them and that they will want to participate in.

In postoperative physiotherapy, mobilisation in the first 24 hours after surgery is essential, as is strengthening and reintegration into everyday life. Prolonged immobilisation results in muscle weakness, reduced muscle mass, respiratory difficulties and complications, such as atelectasis and pneumonia, as well as an increased risk of venous thromboembolic events [1]. Early mobilisation is a key principle of postoperative care within ERAS protocols. However, the reduction in complications and length of hospital stay associated with ERAS programs cannot be attributed solely to early mobilisation, nor has an independent reduction in mortality resulting from this intervention been demonstrated [1,2].

Early mobilisation requires adequate pain control and coordinated management of drains and catheters. The ERAS/ESTS guidelines recommend multimodal analgesia with opioid-sparing strategies and the use of regional analgesia, timely removal of chest drains based on clinical criteria, and the avoidance of unnecessary urinary catheters. These interventions facilitate patient participation in physiotherapy and highlight the need for collaboration among physiotherapists, surgeons, anaesthesiologists, and nurses [1].

Postoperative Respiratory Physiotherapy

In postoperative respiratory rehabilitation, breathing exercises such as diaphragmatic breathing and pursed-lip breathing are generally recommended, as well as the use of inspiratory muscle training (IMT) aimed at improving their strength [7]. The narrative review by Toohey et al. reports that shorter programs with higher session frequency showed higher attendance compared to longer programs with lower frequency. This observation does not establish general superiority regarding effectiveness and requires further investigation [7].

Subsequent Functional Rehabilitation

The exercise program includes aerobics, resistance and breathing exercises and the dosage depends on the stage and endurance of each patient. The review by Toohey et al. [7] describes various exercise intensities and frequencies for patients with lung cancer. These dosages do not constitute a uniform recommendation for the immediate postoperative period. Early mobilisation must be distinguished from subsequent aerobic and strengthening exercise programs, depending on the patient's clinical status and tolerance [7].

DISCUSSION

Physiotherapy is a component of ERAS protocols and can support functional recovery, although its contribution cannot always be isolated from the other interventions. Respiratory interventions should not be treated as a single category with equivalent efficacy. Specifically, regarding incentive spirometry, ERAS/ESTS guidelines state that no additional benefit has been demonstrated in terms of pulmonary function recovery or the reduction of postoperative pulmonary complications. Consequently, the use of respiratory devices requires evidence supporting the specific intervention and the target population [1].

Moreover, physiotherapy improves physical condition through aerobic exercise training, resulting in enhanced cardiorespiratory endurance and an increase in maximal oxygen uptake (VO_2max), as well as through resistance training, which promotes gains in muscle strength. The meta-analysis by Li et al. included 21 studies involving 6,480 patients and compared comprehensive ERAS programs with conventional perioperative care. A lower risk of postoperative complications and a shorter length of hospital stay were observed, without a significant reduction in in-hospital mortality or readmissions. The relative risk of postoperative complications was 0.64, with a 95% confidence interval of 0.52–0.78. These findings do not isolate the effect of physiotherapy from the other components of ERAS [2].

Limitations

This narrative review does not constitute an exhaustive mapping of the literature. The limited coverage of databases and platforms, the restricted combination of

search terms, and the selection of English-language publications may have led to the omission of relevant sources. Furthermore, the exclusion of articles lacking free access to the full text introduces potential availability bias.

Selection was performed by a single researcher without independent verification, and a complete record of exclusions was not maintained. No standardised assessment of methodological quality or risk of bias was conducted. The heterogeneity of populations, interventions, and study designs, along with potential data overlap between primary studies and reviews, limits the interpretation of the findings. Finally, the contribution of physiotherapy cannot always be disentangled from the other components of ERAS.

CONCLUSIONS

Available literature suggests that perioperative physiotherapy can support the functional recovery of patients undergoing lung cancer surgery. Preoperative preparation, respiratory care, and early mobilisation require individualisation and coordination with the multidisciplinary team. However, the benefits of comprehensive ERAS programs cannot be attributed solely to physiotherapy, nor has its independent effect on postoperative mortality been established.

It should also be noted that the implementation of the protocol must be based on the needs of each patient, and the human-centered approach must be appreciated. It is important to provide support, boost self-confidence, maintain honesty and deliver timely information. Furthermore, health professionals need to listen to their patients and recognise their needs including communication needs [8].

Further studies are needed to clarify the independent contribution of physiotherapy interventions within ERAS, their optimal dosage, and the patient characteristics associated with the greatest benefit. Evaluating their implementation across different healthcare systems—including the Greek system—can facilitate the tailoring of perioperative care to local needs and available resources.

Data Availability Statement: *No new data were created or analysed in this study. Data sharing does not apply to this article, as this study is based on previously published literature.*

REFERENCES

1. Batchelor TJP, Rasburn NJ, Abdelnour-Berchtold E, Brunelli, A, Cerfolio RJ, Gonzalez M, et al. Guidelines for enhanced recovery after lung surgery: Recommendations of the Enhanced Recovery after Surgery (ERAS®) Society and the European Society of Thoracic Surgeons (ESTS). Eur J Cardiothorac Surg. 2019 Jan 1;55(1):91-115.
2. Li R, Wang K, Qu C, Qi W, Fang T, Yue W, et al. The effect of enhanced recovery after surgery program on lung cancer surgery: A systematic review and meta-analysis. J Thorac Dis. 2021 Jun;13(6):3566-86.
3. Lu Y, Yuan Z, Han Y, Zhang Y, Xu R. Summary of best evidence for enhanced recovery after surgery for patients undergoing lung cancer operations. Asia Pac J Oncol Nurs [Internet]. 2022 Mar;9(7):100054. Available from: https://doi.org/10.1016/j.apjon.2022.03.006
4. Ferreira V, Minnella EM, Awasthi R, Gamsa A, Ferri L, Mulder D, et al. Multimodal Prehabilitation for Lung Cancer Surgery: A Randomized Controlled Trial. Ann Thorac Surg. 2021 Nov;112(5):1600-8.
5. Hunt I, Muers MM, Treasure T, editors. ABC of Lung Cancer (ABC Series). 1st ed. BMJ Books / Wiley-Blackwell; c2009.
6. Goldsmith I, Chesterfield-Thomas G, Toghill H. Pre-treatment optimization with pulmonary rehabilitation in lung cancer: Making the inoperable patients operable. EClinicalMedicine. 2021 Jan;31:100663. Available from: https://doi.org/10.1016/j.eclinm.2020.100663
7. Toohey K, Mizrahi D, Hart NH, Singh B, Lopez P, Hunter M, et al. Exercise in cancer care for people with lung cancer: A narrative synthesis. J Sci Med Sport. 2025 Jan;28(1):16-25.
8. Collet R, Major M, van Egmond M, van der Leeden M, Maccow R, Eskes A, et al. Experiences of interaction between people with cancer and their healthcare professionals: A systematic review and meta-synthesis of qualitative studies. Eur J Oncol Nurs. 2022 Oct:60:102198. Available from: https://doi.org/10.1016/j.ejon.2022.102198

Perspective

Hell J Surg. 2025 Jul-Sep;95(3):145–151
doi: 10.59869/25075

Building an Accountable Centre of Excellence for Complex Pelvic Oncology: Beyond Centralisation

Christos Kontovounisios

Director, 2nd Surgical Department, HYGEIA Hospital, Athens, Greece; IPEX Athens, HYGEIA Hospital, Athens, Greece
Adjunct Professor, Department of Surgery, NYU Grossman School of Medicine, New York, USA
Visiting Reader, Department of Surgery and Cancer, Faculty of Medicine, Imperial College London, London, UK
Visiting Professor, School of Medicine, National and Kapodistrian University of Athens, Athens, Greece
Honorary Consultant in Colorectal Surgery, The Royal Marsden NHS Foundation Trust and Chelsea and Westminster Hospital NHS Foundation Trust, London, UK

ABSTRACT

Complex pelvic cancer surgery is no longer an isolated operation; it is the end point of a pathway that begins with referral and selection and continues through reconstruction, recovery, and survivorship. Pelvic exenteration may offer local control or cure to carefully selected patients, but its physiological and functional costs remain substantial. In this Perspective, I argue that technical capability and referral volume are not, by themselves, evidence of excellence. A Centre of Excellence should be judged by the quality of its decisions, the depth of its multidisciplinary support, its ability to measure outcomes, and its responsibility to the wider clinical network. IPEX Athens is used as an example of how such a structure can be organised, not as proof of superior results. The central proposition is simple: excellence in complex pelvic oncology must be demonstrated through transparent, patient-centred outcomes and continuous service improvement.

Key words: *Pelvic exenteration; complex pelvic oncology; centralisation; multidisciplinary care; quality improvement; centres of excellence*

INTRODUCTION: EXCELLENCE IS MORE THAN TECHNICAL CAPABILITY

Pelvic exenteration has moved a long way from its origins as a predominantly palliative procedure. For selected patients with locally advanced or recurrent pelvic cancer, it can now be part of a curative plan [1]. That change has not been driven by surgery alone. Better imaging, systemic treatment, radiotherapy, anaesthesia, critical care, reconstruction, and rehabilitation have all widened the group of patients who can be considered for radical treatment. The operation itself has also changed: a planned resection may involve the pelvic sidewall, sacrum, iliac vessels, urinary tract, neural structures, or major soft-tissue reconstruction.

There is a risk in complex surgery of confusing technical reach with excellence. A service must be able to decide who should be considered for surgery, define the likely planes of resection, anticipate reconstruction, explain the functional consequences honestly, and support the patient when recovery is prolonged or complications occur. None of these responsibilities belongs to a single surgeon. They belong to a dedicated system.

The Greek experience provides a useful illustration. A

Corresponding author:
Christos Kontovounisios
2nd Surgical Department, HYGEIA Hospital, Athens, Greece
e-mail: c.kontovounisios@hotmail.com

Submission: 18.08.2026, Acceptance: 01.11.2026

national survey showed variation in experience and perioperative practice and strong support for clearer standards and more centralised pathways [2]. A later single-centre series from Evangelismos General Hospital reported an R0 resection in 16 of 18 patients, but also showed the morbidity and resource intensity of these operations [3]. I regard those two observations as complementary: concentration of expertise is important, but operative volume or margin status alone cannot describe the quality of a service.

This Perspective therefore takes the discussion one step further. Centralisation is necessary, but it is not the end point. The more important question is what a centre should be accountable for once complex pelvic cancer care has been concentrated within it?

Why Centralisation Matters

Locally advanced and recurrent rectal cancer may involve the bladder, prostate, vagina, pelvic sidewall, sacrum, or iliac vessels; selected gynaecological, urological, anal, and soft-tissue malignancies create similar problems. The chance of complete resection, which remains closely linked to long-term outcome, depends on careful anatomical assessment and coordinated planning across specialties [5-8].

Centralisation makes that coordination easier to reproduce. Radiologists, pathologists, surgeons, oncologists, anaesthetists, specialist nurses, rehabilitation teams, and reconstructive services become accustomed to working together on the same type of difficult case. The institution can also maintain practical systems for major haemorrhage, long operations, critical-care support, complex wounds, stoma care, and early rehabilitation. The PelvEx minimum standards reflect this wider view by emphasising referral arrangements, specialist imaging, multidisciplinary infrastructure, perioperative capability, and prospective audit [5].

I would nevertheless avoid using annual case volume as the sole parameter for quality. Repeated exposure matters, but so do case mix, anatomical complexity, patient selection, team stability, rescue capability, and the discipline with which outcomes are recorded. Benchmark data are useful because they allow a centre to place its results in context, but they only become meaningful when interpreted alongside the patients who were selected and the pathway through which they were treated [11].

From Specialist Service to Accountable Centre

For practical purposes, I find it helpful to think of service development in four stages (Figure 1). A pelvic exenteration service can perform the operation. A specialist referral centre adds a concentration of difficult cases and relevant

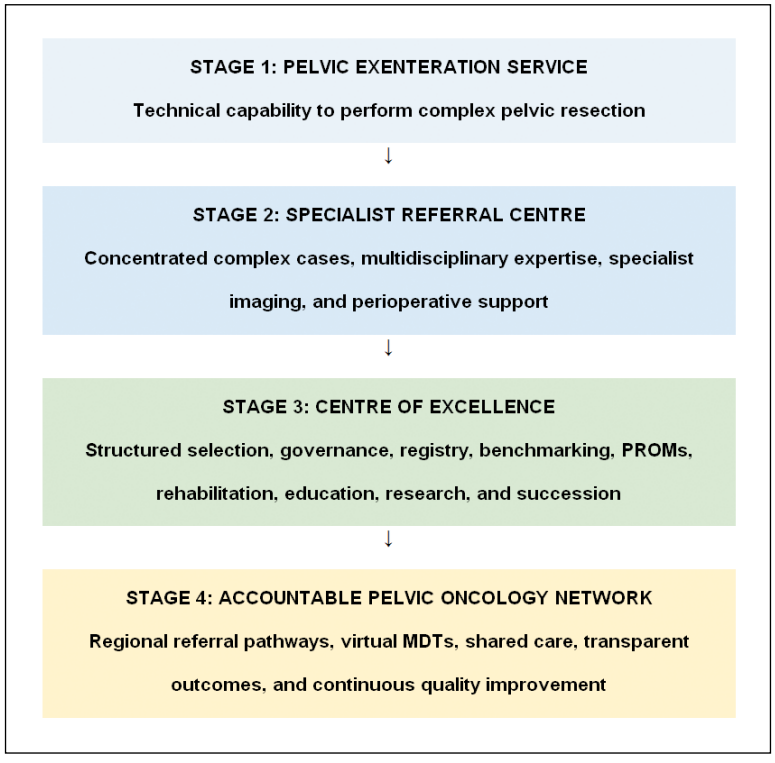

FIGURE 1. From procedural capability to accountable excellence. Proposed stages of maturity: (1) pelvic exenteration service; (2) specialist referral centre; (3) Centre of Excellence; and (4) accountable pelvic oncology network.

expertise. A Centre of Excellence goes further by accepting formal responsibility for governance, prospective data, external comparison, patient-reported outcomes, training, research, and succession. The most mature model is a network in which the specialist centre remains linked to referring hospitals through agreed pathways, virtual review, shared care, and transparent reporting.

This distinction is more than terminology. The phrase 'Centre of Excellence' should not function as a self-awarded title. Minimum standards tell us what is needed to practise safely. Excellence requires evidence that the service can identify its own shortcomings, act on them, and improve access and outcomes beyond the walls of the institution (Table 1).

Core Components of an Accountable Service

Referral, access, and selection

The first responsibility of a specialist centre is selection, not surgery. Patients with potentially resectable advanced or recurrent disease should have access to assessment by a team that can judge the anatomy, previous treatment, metastatic burden, physiological reserve, symptoms, and the patient's own priorities. The discussion must also ask whether the likely oncological benefit justifies the functional price of treatment.

Referral needs to be straightforward and timely. Second opinions and virtual multidisciplinary review are particularly valuable for patients who live far from the specialist centre. Centralisation should not force every part of the pathway into one hospital. Local teams remain essential for diagnosis, systemic treatment, surveillance, rehabilitation, and survivorship; the specialist centre should concentrate the decisions and interventions that genuinely require concentrated expertise (Figure 2).

Multidisciplinary decision-making

The pelvic oncology multidisciplinary team is where the service either becomes coherent or fragments. Its core membership should include pelvic oncological or colorectal surgeons, specialist radiologists, pathologists, medical oncologists, radiation oncologists, urologists, and specialist nurses. Vascular, orthopaedic or spinal, plastic and reconstructive, gynaecological, pain, nutrition, rehabilitation, palliative-care, and anaesthetic expertise should be available when the planned treatment requires it [5].

A useful MDT record should contain more than a binary decision to operate or not operate. It should state the intent of treatment, the anatomical extent of disease, the margins at risk, the structures likely to require en bloc resection, the reconstructive plan, alternatives to surgery, expected morbidity, and the patient's priorities. I would also include declined cases in formal review. Understanding why surgery was not offered is part of understanding how a centre selects patients, and it makes later audit of decision-making possible.

Imaging, pathology, and operative planning

In complex pelvic surgery, imaging is part of the operation before the patient reaches theatre. High-resolution pelvic MRI, structured reporting, and direct review between radiology and the surgical team help define threatened margins and map the compartments that may need to

TABLE 1. Proposed domains and indicators for an accountable Centre of Excellence.

Domain	Examples of indicators	Purpose
Referral and access	Defined referral criteria; virtual review; referral-to-review and referral-to-treatment intervals	Timely access and reduced geographical inequality
Selection and MDT governance	Structured decisions; documented intent; review of declined cases; patient priorities recorded	Consistent selection and shared decision-making
Imaging and pathology	Specialist MRI review; anatomical roadmap; radiology-surgery-pathology correlation	More accurate assessment of resectability and margins
Operative and perioperative care	Planned multivisceral and reconstructive support; anaesthesia, critical care, transfusion and rehabilitation pathways	Appropriate radicality and safer recovery
Outcomes and improvement	Prospective registry; complications, reintervention, mortality, R0, survival, PROMs, external comparisons	Transparency and continuous quality improvement
Education and network responsibility	Training pathway; research participation; succession planning; shared-care and referrer communication	Sustainable expertise and continuity of care

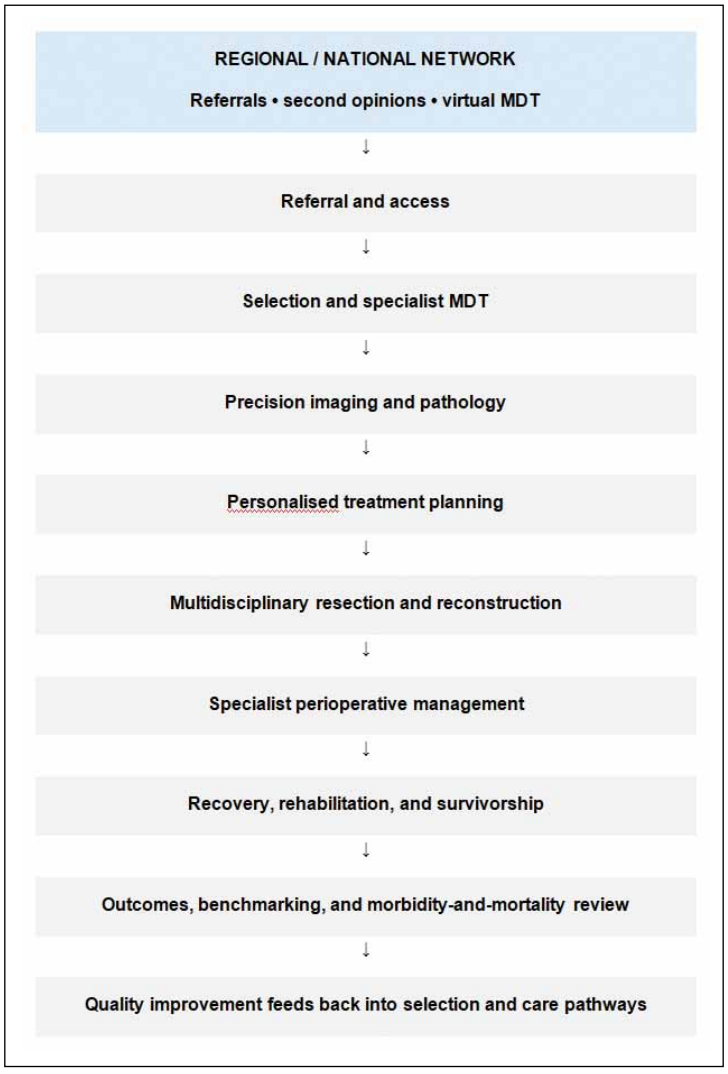

FIGURE 2. Patient-centred governance model for complex pelvic oncology. The pathway runs from referral and access to specialist assessment, imaging and pathology, personalised planning, multidisciplinary surgery and reconstruction, perioperative care, rehabilitation and survivorship, and prospective outcome review. Clinical, outcome, professional, and network governance support each stage. Results feed back into pathway design and future decision-making.

be resected [13]. CT and PET/CT have complementary roles depending on tumour type, prior treatment, and the clinical question.

The same principle applies after surgery. Pathology should not sit separately from radiology and operative planning; standardised margin reporting and case review allow the three disciplines to learn from each other. Planning should remain anatomy-led. The practical question is which structures must be removed to obtain an oncologically meaningful clearance, and which can be preserved without compromising that aim.

Operative and perioperative capability

An excellent service is an institutional team, not a named operator. When the anatomy requires it, urological, vascular, orthopaedic, gynaecological, and reconstructive expertise should be planned in advance rather than called for after the operation has started. Specialist anaesthesia, blood-bank support, interventional radiology, critical care, theatre and ward nursing, stoma therapy, nutrition, and physiotherapy are equally important [5,14].

These services also need to agree on how patients are prepared and rescued. Prehabilitation, nutritional optimisation, anaesthetic assessment, venous-thromboembolism prevention, haemorrhage planning, analgesia, wound care, stoma education, and mobilisation should be built into the pathway. Radical surgery should never be discussed as if the operation were separate from the preparation and

postoperative systems that make it tolerable and, when things go wrong, survivable.

Recovery and survivorship

Patients live with the consequences of exenterative surgery long after the pathology report has been filed. Urinary and bowel diversion, sexual dysfunction, pain, impaired mobility, fatigue, psychological distress, and social consequences can remain important months or years after discharge. These possibilities deserve explicit discussion before treatment, including the likely course of rehabilitation and the alternatives to radical surgery.

A centre that claims excellence should therefore provide more than follow-up scans. Stoma care, nutrition, physiotherapy, pain management, psychological support, and sexual-health counselling should be available when relevant. Patient-reported outcome measures are still used inconsistently in the literature [18], but recent consensus work has made the priorities clearer: survival and recurrence matter, but so do margin status, quality of life, physical and psychological function, and independent mobility [19].

Measurement, benchmarking, and improvement

A prospective registry is the practical backbone of accountability. At a minimum, it should capture where the patient was referred from, how long assessment took, the MDT decision, treatment intent, operative complexity, pathology, complications, reinterventions, readmission, length of stay, 30- and 90-day mortality, survival, functional recovery, and patient-reported outcomes. Common terminology, including the Pelvic Exenteration Lexicon, makes comparison between centres more credible [15].

No single metric should dominate that assessment. R0 rate and procedural volume are important, but published studies have used heterogeneous definitions and reporting standards [17]. Regular morbidity-and-mortality review, examination of near misses, and comparison with external benchmarks should lead to visible changes in practice. Service measures deserve the same attention. Delays from referral to review or from decision to treatment can undermine a technically excellent operation, and they are often easier to improve than the biology of the cancer.

Education, research, and network responsibility

A field this specialised cannot remain dependent on a handful of individuals. Training needs to include judgement, imaging interpretation, complication management, reconstruction, recovery, and audit as well as operative technique. Prospective registries, collaborative studies, technical standardisation, and multidisciplinary education are the mechanisms by which experience becomes transferable rather than personal [20,21].

The same principle applies to the centre's relationship with referrers. Clinicians outside the specialist unit need clear criteria, reliable communication, and timely advice. Virtual MDT review can spare patients unnecessary travel, while shared-care arrangements can return suitable parts of treatment and follow-up to local teams without losing specialist oversight for the highest-risk decisions [10].

IPEX Athens as an Implementation Example

IPEX Athens was established at HYGEIA Hospital in July 2026 to coordinate assessment and treatment for patients with complex pelvic malignancy [22]. Its intended structure includes multidisciplinary planning, advanced pelvic surgery, specialist imaging and oncology input, critical care, rehabilitation, prospective data collection, education, and professional collaboration. I describe it here because it provides a current example of how the organisational principles discussed above can be assembled within a new service.

Referral activity, time to decision, selection, resection margins, morbidity, mortality, functional recovery, patient experience, and continuity with referring teams should all be reported prospectively. Negative findings will be as important as positive ones if they lead to changes in the pathway. The previously published 18-patient series was undertaken at Evangelismos General Hospital before IPEX Athens was established [3], and those results should remain clearly attributed to that earlier public-hospital experience.

From Centres to Networks

The next development in complex pelvic oncology should be a move away from informal claims of expertise towards explicit standards that can be audited. The PelvEx minimum standards provide a baseline [5]; benchmark data provide context for performance [11]; and patient-centred outcome work broadens the definition of success beyond the operation itself [19]. Together, these strands make it possible to discuss excellence in terms that are testable rather than promotional.

Any future accreditation system should be cautious about setting a single annual case-number threshold. Volume matters, but it does not describe anatomical complexity, referral patterns, team depth, selection quality, perioperative infrastructure, functional outcomes, or contribution to the wider network. In smaller countries,

a hub-and-spoke model may be particularly practical: difficult cases can be reviewed centrally, major surgery can be concentrated where the full team is available, and appropriate elements of care can remain close to the patient's home.

CONCLUSION

Complex pelvic oncology requires more than technical proficiency. Centralisation matters because it brings together the people and infrastructure needed for difficult decisions and demanding surgery. The quality of the service, however, is revealed across the whole pathway: who reaches specialist review, how decisions are made, how complications are anticipated and managed, what happens during recovery, which outcomes are measured, and whether the organisation changes when results are not good enough.

For that reason, I do not think a Centre of Excellence should be defined by prestige, ownership, or the ability to perform pelvic exenteration. It should be defined by accountable multidisciplinary care and by outcomes that matter to patients. The broader objective is not to create a label. It is to create a service in which complex pelvic cancer patients reach the right expertise in time, receive a well-reasoned treatment recommendation, and can see that the centre is prepared to measure, report, and improve the care it provides.

Conflict of Interest: *C.K. is Director of IPEX Athens, HYGEIA Hospital. IPEX Athens is discussed as an implementation example. No clinical outcomes from IPEX Athens are reported in this Perspective.*

Funding: *No specific funding was received for preparation of this Perspective.*

Data Availability: *No new patient-level data were generated or analysed.*

Ethics Statement: *Not applicable. This article does not report new human-subject research.*

Author Contributions: *C.K. conceived the article, developed the framework, and reviewed and approved the final manuscript.*

REFERENCES

1. Kontovounisios C. Dictum of success in pelvic exenterative surgery. Hell J Surg. 2024 Jan-Mar;94(1):5–6. Doi:10.59869/23021.
2. Greek Pelvic Exenteration Collaborative, Bikas K, Papaeleftheriou S, Giannos G, Tseliou V, Chrysikopoulou A, Katsimente S. Pelvic exenteration for locally advanced rectal cancer (LARC) and locally recurrent rectal cancer (LRRC) in Greece: A national snapshot survey of current practice. Hell J Surg. 2024 Jul-Sep;94(3):115–41. Doi:10.59869/24037.
3. Bikas K, Matsagkos D, Papaeleftheriou S, Tseliou V, Katsimente S, Chrysikopoulou A, et al. Perioperative outcomes and morbidity following pelvic exenteration surgery: a single-centre experience. Hell J Surg. 2025 Apr-Jun;95(5):78–85. Doi:10.59869/25064.
4. Kontovounisios C, Tan E, Pawa N, Brown G, Tait D, Cunningham D, et al. The selection process can improve the outcome in locally advanced and recurrent colorectal cancer: activity and results of a dedicated multidisciplinary colorectal cancer centre. Colorectal Dis. 2017 Apr;19(4):331-8. Doi:10.1111/codi.13517.
5. PelvEx Collaborative. Minimum standards of pelvic exenterative practice: PelvEx Collaborative guideline. Br J Surg. 2022 Nov;109(12):1251-63. Doi:10.1093/bjs/znac317.
6. PelvEx Collaborative. Surgical and survival outcomes following pelvic exenteration for locally advanced primary rectal cancer: Results from an international collaboration. Ann Surg. 2019 Feb;269(2):315-21. Doi:10.1097/SLA.0000000000002528.
7. PelvEx Collaborative. Factors affecting outcomes following pelvic exenteration for locally recurrent rectal cancer. Br J Surg. 2018 May;105(6):650-7. Doi:10.1002/bjs.10734.
8. PelvEx Collaborative. Pelvic exenteration for advanced nonrectal pelvic malignancy. Ann Surg. 2019 Nov;270(5):899-905. Doi: 10.1097/SLA.0000000000003533
9. Traeger L, Bedrikovetski S, Oehler MK, Cho J, Wagstaff M, Harbison J, et al. Short-term outcomes following development of a dedicated pelvic exenteration service in a tertiary centre. ANZ J Surg. 2022 Oct;92(10):2620-7. Doi:10.1111/ans.17921.
10. Fitzsimmons T, Thomas M, Tonkin D, Murphy E, Hollington P, Solomon M, et al. Establishing a state-wide pelvic exenteration multidisciplinary team meeting in South Australia. ANZ J Surg. 2023 May;93(5):1227-31. Doi:10.1111/ans.18220.
11. Brown KGM, Solomon MJ, Koh CE, Sutton PA, Aguiar SJr, Bezerra TS, et al. Defining benchmarks for pelvic exenteration surgery: a multicentre analysis of patients with locally advanced and recurrent rectal cancers. Ann Surg. 2025 Dec;282(6):1118-26. Doi:10.1097/SLA.0000000000006348.
12. Humphries EL, Kroon HM, Dudi-Venkata NN, Thomas ML, Moore JW, Sammour T. Short- and long-term outcomes of selective pelvic exenteration surgery in a low-volume specialized tertiary setting. ANZ J Surg. 2019 Jun;89(6):E226–E230. Doi: 10.1111/ans.15212
13. Nougaret S, Lambregts DMJ, Beets GL, Beets-Tan RGH, Blomqvist L, Burling D, et al. Imaging in pelvic exenteration—a multidisciplinary practice guide from the ESGAR-SAR-ESUR-PelvEx collaborative group. Eur Radiol. 2025 May;35(5):2681-91. Doi:10.1007/s00330-024-10940-z.
14. PelvEx Collaborative. Perioperative management and anaesthetic considerations in pelvic exenterations using Delphi methodology: results from the PelvEx Collaborative. BJS Open. 2021 Jan;5(1):zraa055. Doi:10.1093/bjsopen/zraa055.
15. Burns EM, Quyn A; Lexicon Collaboration of UKPEN and the ACPGBI Advanced Cancer Subcommittee. The Pelvic

Exenteration Lexicon: creating a common language for complex pelvic cancer surgery. Colorectal Dis. 2023 May;25(5):888–96. Doi:10.1111/codi.16476.
16. PelvEx Collaborative. Contemporary results from the PelvEx Collaborative: improvements in surgical outcomes for locally advanced and recurrent rectal cancer. Colorectal Dis. 2024 May;26(5):926-31. Doi:10.1111/codi.16948.
17. Brown KGM, Pisaniello J, Ng KS, Solomon MJ, Sutton PA, Hatcher S, et al. Variation in outcome measurement and reporting in studies of pelvic exenteration for locally advanced and recurrent rectal cancer: a systematic review. Colorectal Dis. 2024 Feb;26(2):272-80. Doi:10.1111/codi.16844.
18. Denys A, van Nieuwenhove Y, Van de Putte D, Pape E, Pattyn P, Ceelen W, et al. Patient-reported outcomes after pelvic exenteration for colorectal cancer: a systematic review. Colorectal Dis. 2022 Apr;24(4):353–68. Doi:10.1111/codi.16028.
19. Brown KGM, Morkaya J, Solomon MJ, Ng K-S, White K, Sutton P, et al. Priority outcomes of pelvic exenteration for rectal cancer: a patient, carer, and clinician consensus. Br J Surg. 2024 Nov;111(12):znae298. Doi:10.1093/bjs/znae298.
20. Steffens D, Solomon MJ, Lee P, Austin K, Koh C, Byrne C, et al. Surgical, survival and quality of life outcomes in over 1000 pelvic exenterations: lessons learned from a large Australian case series. ANZ J Surg. 2023 May;93(5):1232-41. Doi: 10.1111/ans.18356.
21. Brown KGM, McBride KE, Anderson T, Solomon MJ. Delivering complex surgical services: lessons learned from the evolution of a specialised pelvic exenteration centre. Aust Health Rev. 2023 Dec;47(6):735-40. Doi:10.1071/AH23186.
22. HYGEIA Hospital. HYGEIA Hospital establishes IPEX Athens: International Centre for Advanced Pelvic Oncology and Pelvic Exenteration [Internet]. Institutional announcement. 8 July 2026. Available from: https://www.hygeia.gr/en/press-release/hygeia-hospital-establishes-ipex-athens-international-centre-for-advanced-pelvic-oncology-and-pelvic-exenteration/

Hell J Surg. 2025 Jul-Sep;95(3):152–156
doi: 10.59869/25076

Adipokines and Clinical Outcomes in Upper Gastrointestinal Cancer: Protocol for a Prospective Cohort Study

Adam Mylonakis[1], Konstantinos G. Toutouzas[2], Dimitrios Theodorou[2], Dimitrios Schizas[1]

[1]First Department of Surgery, National and Kapodistrian University of Athens, Laiko General Hospital, Athens, Greece
[2]First Propaedeutic Department of Surgery, National and Kapodistrian University of Athens, Hippocration General Hospital, Athens, Greece

ABSTRACT

Obesity is associated with upper gastrointestinal (GI) malignancies, with particularly strong epidemiological links to oesophageal adenocarcinoma and gastric cardia cancer. Adipose tissue is biologically active, and adipokines may provide one of the links between excess adiposity, inflammation, and tumour progression. Clinical evidence, however, remains limited. Most studies have examined one or a small number of circulating adipokines, often in relatively small cohorts, while tissue expression and long-term oncological outcomes have received much less attention. This prospective cohort study will be conducted at two tertiary university hospitals in Athens, Greece, with a 36-month recruitment period and a total study duration of 48 months. Adults with histologically confirmed oesophageal or gastric cancer undergoing curative-intent surgery will be eligible. Preoperative serum adipokines will be measured using enzyme-linked immunosorbent assays, while subcutaneous and omental adipose tissue will be collected during surgery for tissue-level assessment. Clinical, nutritional, metabolic, pathological, and oncological data will be recorded prospectively. The primary objective is to examine whether circulating and tissue adipokine profiles are associated with tumour stage, clinicopathological characteristics, and prognosis. Postoperative morbidity, recurrence, disease-free survival, and overall survival will also be evaluated. By examining serum and two adipose tissue compartments within the same patients, this study will address whether circulating adipokine changes reflect tissue-level findings and whether particular adipokine patterns are associated with tumour behaviour or clinical outcome. Findings from this cohort may help identify signals that warrant further evaluation in larger, disease-specific studies.

Key words: *Adipokines; upper gastrointestinal cancer; obesity; prognosis; prospective cohort study*

Corresponding author:
Adam Mylonakis
First Department of Surgery
National and Kapodistrian University of Athens
Laiko General Hospital
17, Ag. Thoma 17 St., 11527, Athens, Greece
e-mail: adam.mylonakis@gmail.com

Submission: 05.06.2026, Acceptance: 30.10.2026

BACKGROUND

Upper gastrointestinal (GI) malignancies, including oesophageal and gastric cancer, remain major causes of cancer-related mortality worldwide and continue to carry a poor prognosis despite advances in treatment. Among these malignancies, oesophageal squamous cell carcinoma and adenocarcinoma differ substantially in their epidemiology and risk factors, while gastric cancer presents a biologically

and clinically heterogeneous group of tumours [1,2].

Obesity is increasingly recognised as a risk factor for certain upper GI malignancies, with an established association with oesophageal and gastric cardia adenocarcinoma [3,4]. In contrast, oesophageal squamous cell carcinoma is primarily associated with tobacco smoking and alcohol consumption, rather than obesity [1]. Beyond its association with increased cancer risk, adiposity is thought to influence tumour biology through the endocrine activity of adipose tissue and the release of bioactive mediators [5-7]. Among these, adipokines have attracted interest because of their involvement in metabolic regulation, inflammation, angiogenesis, and cell proliferation [6,7]. Several adipokines, including leptin, adiponectin, resistin, visfatin, chemerin, and omentin, have been linked to pathways involved in tumour development and progression [6,7]. Among these, leptin and adiponectin have been studied more extensively, while evidence for other adipokines in oesophageal and gastric cancer remains limited [6-9].

The aim of this study is to investigate the association between circulating and adipose tissue adipokine profiles and tumour characteristics, prognosis, and clinical outcomes in patients with oesophageal and gastric cancer.

OBJECTIVES

Primary Objectives

The primary objectives of the proposed study protocol are:

1. To assess the association between preoperative serum concentrations of selected adipokines, including leptin, adiponectin, resistin, visfatin, chemerin, and omentin, and tumour stage and prognosis in patients with oesophageal and gastric cancer.
2. To evaluate the expression of these adipokines in subcutaneous and omental adipose tissue and correlate tissue expression with clinicopathological characteristics and clinical outcomes.

Secondary Objective

To investigate the relationship between nutritional and metabolic status and prognosis in patients with upper gastrointestinal cancer.

METHODS AND DESIGN

Study Design and Setting

This is a prospective cohort study that will be conducted at two tertiary university hospitals in Athens, Greece. Patients will be eligible if they are aged ≥18 years, have histologically confirmed oesophageal or gastric cancer, and are scheduled for elective surgical resection with curative intent. Written informed consent will be required before inclusion. Patients with another active malignancy and those unable to provide informed consent or comply with study procedures will be excluded. Patients found to have unresectable or metastatic disease during surgery will remain in the observational cohort, while analyses requiring pathological staging after resection or disease-free survival will be restricted to patients who undergo tumour resection and meet the criteria for the respective analyses.

Sample Size and Recruitment

The participating centres have a combined annual surgical volume of approximately 150 patients with oesophageal or gastric cancer. Over the planned 36-month recruitment period, approximately 450 patients are expected to be assessed for eligibility. Assuming an enrolment rate of 80%, the anticipated study population will comprise approximately 360 patients.

Given the exploratory nature of the study, the sample size is primarily based on anticipated recruitment feasibility. Allowing for 10% incomplete data, approximately 324 patients are expected to be available for analysis. For a representative comparison of circulating adipokine concentrations between two groups with a 30:70 distribution, this sample would provide 80% power to detect a standardised mean difference of approximately 0.34, using a two-sided significance level of 0.05. This calculation represents an illustrative sensitivity analysis rather than a formal power calculation for all planned biomarker–outcome associations.

The study is intended to explore associations between adipokines and clinical outcomes rather than provide definitive validation of individual biomarkers. Analyses involving smaller subgroups or less frequent outcomes may have limited statistical power and will be interpreted accordingly.

Data Collection

Demographic and clinical data will include age, sex, type of malignancy, treatment received, type of surgery, American Society of Anesthesiologists (ASA) physical status, Eastern Cooperative Oncology Group (ECOG) performance status, and follow-up. Medication use, including antidiabetic agents, statins, and corticosteroids, will also be recorded. Routine blood tests, inflammatory markers, tumour markers, and lipid parameters will also be recorded.

Nutritional and metabolic status will be assessed using changes in body weight and body mass index (BMI),

along with validated nutritional assessments including the Patient-Generated Subjective Global Assessment (PG-SGA), Prognostic Nutritional Index (PNI), Geriatric Nutritional Risk Index (GNRI), Controlling Nutritional Status (CONUT), and Global Leadership Initiative on Malnutrition (GLIM) criteria. Anthropometric and body-composition assessment will include skeletal muscle and sarcopenia indices, with CT-derived measurements obtained from available staging examinations, while functional assessment will include handgrip strength and gait speed.

Pathological variables will include histological type, tumour grade, TNM classification, and disease stage. Clinical stage before treatment and pathological stage after surgery will be recorded separately, including post-neoadjuvant pathological staging (ypTNM), where applicable. Neoadjuvant treatment regimens and the interval between treatment completion and surgery will also be documented. Postoperative outcomes will include length of stay and any complications graded using the Clavien-Dindo classification. Clinical and oncological follow-up will be performed at 3, 6, and 12 months after surgery and annually thereafter, with additional assessments according to clinical indications. Disease recurrence, disease-free survival, and overall survival will be recorded using clinical records and available follow-up information.

Patient recruitment and biological sample collection will take place over 36 months, with an anticipated enrollment of approximately 360 patients. An additional 12 months will be allocated for completion of follow-up, laboratory analyses, and statistical evaluation, resulting in a total study duration of 48 months. Primary results are expected to become available by the end of this period, while longer-term oncological follow-up will continue beyond study completion.

Biological Sample Collection and Laboratory Analyses

Preoperative venous blood samples will be obtained within one week before surgery. Sampling will follow a standardised protocol across both participating centres, including consistent collection, processing, and storage procedures. Serum will be separated by centrifugation and stored at −80°C until analysis. Approximately 0.5–1 g of tissue will be collected from each compartment, with subcutaneous samples obtained from the abdominal incision site and omental samples obtained from macroscopically unaffected areas of the greater omentum. Tissue collection will be attempted in all enrolled patients whenever anatomically feasible, and unavailable or inadequate samples will be documented. Samples intended for molecular analysis will be stored at −80°C. Samples intended for histological assessment will be fixed in 10% neutral-buffered formalin and processed as formalin-fixed, paraffin-embedded tissue.

Serum leptin, adiponectin, resistin, visfatin, chemerin, and omentin concentrations will be measured using commercially available enzyme-linked immunosorbent assay (ELISA) kits. Samples from both participating centres will be distributed across batches to minimise intercentre analytical variability. Adipokine protein expression in adipose tissue will also be examined by immunohistochemistry (IHC), using antibodies validated for human formalin-fixed, paraffin-embedded tissue, with standard positive and negative controls. Immunohistochemical expression will be assessed semi-quantitatively based on staining intensity, classified as negative (0), weak (1+), moderate (2+), or strong (3+), and the percentage of positively stained cells. Furthermore, tissue expression will be assessed by two independent observers blinded to clinical outcomes. Interobserver agreement will be assessed using weighted Cohen's kappa, and discrepancies will be resolved by consultation with a senior pathologist. Finally, relationships between serum adipokine concentrations and expression in subcutaneous and omental adipose tissue will also be investigated.

Statistical Analysis

Baseline characteristics will be summarised using appropriate descriptive statistics. Associations between individual adipokines and tumour stage, histological characteristics, and postoperative outcomes will be examined using univariable analyses. Continuous outcomes will be analysed using linear regression, binary outcomes using logistic regression, and ordered categorical outcomes using ordinal logistic regression where appropriate. Multivariable analyses will be performed to account for relevant clinical and demographic factors, including age, sex, BMI, tumour type, and treatment characteristics. Given the exploratory nature of the study, analyses involving multiple biomarkers and outcomes will be considered hypothesis-generating. The Benjamini–Hochberg method will be used to adjust for multiple comparisons, while statistical significance will be set at a two-sided p value of <0.05, with adjusted p values reported for analyses involving multiple comparisons.

Overall survival and DFS will be estimated using Kaplan-Meier analysis. Overall survival will be defined as the interval from surgery to death from any cause, while DFS will be defined as the interval from curative resection in patients without residual disease to documented disease recurrence or death, whichever occurs first. Patients without an event will be censored at their last available follow-up. Cox proportional hazards regression will be

used to associate adipokine concentrations and survival after adjustment for covariates, including age, sex, BMI, tumour stage, and comorbidities. Oesophageal and gastric cancers will be analysed separately where sample size permits, with further subanalyses according to histological or anatomical subtype. In addition, patients receiving neoadjuvant treatment and treatment-naïve patients will be evaluated in separate strata to account for potential treatment-related effects on adipokine concentrations. Clinical and pathological tumour stages will be analysed separately, with post-neoadjuvant pathological staging considered in patients who received preoperative treatment.

The primary analyses will focus on the associations between adipokine profiles, tumour stage, and survival outcomes. Additional evaluation will examine associations with clinicopathological, postoperative, nutritional, and metabolic outcomes.

Relationships among circulating adipokine levels and between serum levels and tissue expression will also be assessed. Correlations between serum concentrations and adipokine expression in subcutaneous and omental adipose tissue will be investigated separately using appropriate correlation coefficients.

Ethical Considerations

The study protocol will be submitted for approval to the Ethics Committees of both participating institutions. Written informed consent will be obtained from all participants before enrolment, including consent for biological sample collection and analysis. Patient data will be pseudonymised and handled in accordance with applicable data protection regulations.

DISCUSSION

Obesity is increasingly recognised as an important factor in the development and progression of several malignancies, including upper gastrointestinal cancers. One suggested link between excess adiposity and aggressive tumour biology is the activity of adipose tissue, which contributes to metabolic, inflammatory, and endocrine signalling through the release of adipokines [5-7]. These mediators have been linked to pathways involved in cell proliferation, angiogenesis, immune regulation, and tumour progression [6,7]. Among them, leptin and adiponectin have been studied more extensively in gastrointestinal malignancies, while the roles of resistin, visfatin, chemerin, and omentin remain less clearly defined [6-8].

The role of adipokines in upper gastrointestinal malignancy remains unclear. Most of the available data has focused on circulating biomarkers, and findings have not always been consistent. For instance, in oesophageal adenocarcinoma, a systematic review of obesity-related inflammatory and metabolic biomarkers found inconsistent associations across several circulating markers [9]. Additionally, evidence relating broader adipokine profiles to adipose tissue expression, pathological characteristics, recurrence, DFS, and OS is less developed [7,8]. It therefore remains uncertain whether alterations in adipokines primarily reflect obesity, systemic inflammation, nutritional deterioration, or tumour burden, or whether particular profiles are more closely associated with tumour behaviour and prognosis.

The proposed protocol was designed to address several of these gaps. Rather than examining individual adipokines in isolation, a broader panel will be assessed in parallel. Circulating concentrations will also be examined alongside expression in subcutaneous and omental adipose tissue obtained from the same patients. This permits comparison of systemic adipokine levels with two distinct adipose compartments. Omental adipose tissue is of particular interest as a visceral depot within the upper abdominal tumour environment, while subcutaneous tissue provides a different adipose compartment for comparison.

Adipokine measurements will further be interpreted alongside clinical, nutritional, pathological, and oncological data. Their associations with TNM stage, histological characteristics, postoperative morbidity, recurrence, DFS, and OS will be examined together with nutritional and metabolic parameters. This may help clarify whether particular adipokine patterns are associated with specific tumour characteristics or subsequent clinical outcomes.

A major strength of the protocol is the prospective and simultaneous collection of biological samples and clinical data within a defined surgical population. The assessment of several adipokines in parallel, together with paired serum and tissue measurements, provides the opportunity to examine both systemic and tissue-level patterns. Sampling both subcutaneous and omental adipose tissue also allows differences between adipose compartments to be explored and provides the opportunity to assess the same biomarkers across distinct tissue environments. In addition, assessment of nutritional status, body composition, inflammatory indices, functional status, and pathological characteristics should allow adipokine findings to be interpreted within the broader clinical and metabolic context of each patient.

Several limitations should also be considered. The observational design cannot establish causality, and preoperative adipokine concentrations may be influenced by tumour burden, cancer-related weight loss, systemic

inflammation, nutritional status, or previous neoadjuvant treatment. In patients receiving neoadjuvant therapy, preoperative adipokine concentrations will reflect the post-treatment state, which may differ from that of treatment-naïve patients. These groups will therefore be evaluated separately. A single preoperative serum measurement will also not capture changes occurring during treatment or follow-up. Oesophageal and gastric cancers each include biologically distinct histological and anatomical subtypes, and the number of patients within individual subgroups may limit the power of disease-specific analyses. In addition, the evaluation of several biomarkers and multiple outcomes increases the possibility of chance associations. Accordingly, findings will be considered exploratory and will require confirmation in independent cohorts.

Overall, this prospective investigation aims to clarify the relationship between circulating and adipose tissue adipokines and the clinical and pathological features of upper gastrointestinal cancer. Comparing serum, subcutaneous adipose tissue, and omental adipose tissue within the same cohort may help identify patterns associated with tumour behaviour or prognosis and determine which adipokines warrant further investigation in larger, disease-specific populations.

CONCLUSION

This prospective study will investigate the relationship between circulating and adipose tissue adipokine profiles and the clinicopathological and oncological characteristics of oesophageal and gastric cancer. By assessing serum concentrations together with subcutaneous and omental adipose tissue expression, it aims to provide a clearer picture of adipokine profiles across different biological compartments. The findings may help determine whether specific adipokine patterns are associated with tumour stage, recurrence, or survival and identify those that warrant further investigation in larger, disease-specific cohorts.

REFERENCES

1. Lagergren J, Smyth E, Cunningham D, Lagergren P. Oesophageal cancer. Lancet. 2017 Nov;390(10110):2383-96. Doi: 10.1016/S0140-6736(17)31462-9.
2. Smyth EC, Nilsson M, Grabsch HI, van Grieken NC, Lordick F. Gastric cancer. Lancet. 2020 Aug;396(10251):635-48. Doi: 10.1016/S0140-6736(20)31288-5.
3. Renehan AG, Tyson M, Egger M, Heller RF, Zwahlen M. Body-mass index and incidence of cancer: A systematic review and meta-analysis of prospective observational studies. Lancet. 2008 Feb;371(9612):569-78. Doi: 10.1016/S0140-6736(08)60269-X.
4. Lauby-Secretan B, Scoccianti C, Loomis D, Grosse Y, Bianchini F, Straif K. Body fatness and cancer- Viewpoint of the IARC Working Group. N Engl J Med. 2016 Aug;375(8):794-8. Doi: 10.1056/NEJMsr1606602.
5. Park J, Morley TS, Kim M, Clegg DJ, Scherer PE. Obesity and cancer- Mechanisms underlying tumour progression and recurrence. Nat Rev Endocrinol. 2014 Aug;10(8):455-65. Doi: 10.1038/nrendo.2014.94.
6. Kim JW, Kim JH, Lee YJ. The role of adipokines in tumor progression and its association with obesity. Biomedicines. 2024 Jan;12(1):97. Doi: 10.3390/biomedicines12010097.
7. Kounatidis D, Vallianou NG, Karampela I, Grivakou E, Dalamaga M. The intricate role of adipokines in cancer-related signaling and the tumor microenvironment: Insights for future research. Semin Cancer Biol. 2025 Aug;113:130-50. Doi: 10.1016/j.semcancer.2025.05.013.
8. Marques V, Arella F, Afonso MB, Santos AA, Rodrigues CMP. Decoding the role of leptin and adiponectin in obesity-related gastrointestinal cancer. Clin Sci (Lond). 2023 Aug;137(15):1095-114. Doi: 10.1042/CS20230411.
9. Xie SH, Rabbani S, Ness-Jensen E, Lagergren J. Circulating levels of inflammatory and metabolic biomarkers and risk of esophageal adenocarcinoma and Barrett esophagus: Systematic review and meta-analysis. Cancer Epidemiol Biomarkers Prev. 2020 Nov;29(11):2109-18. Doi: 10.1158/1055-9965.EPI-20-0572.

Case Report

Hell J Surg. 2025 Jul-Sep;95(3):157–161
doi: 10.59869/25077

Appendiceal Endometriosis Presenting as Acute Appendicitis: Successful Management with Laparoscopic Appendectomy

Panayiotis Antoniou[1], Giorgos Skouroumouni[1], Athanasios Bounovas[1], Maria Emmanouela Kopaka[2], Nikolaos Nikitakis[1]

[1]*Second Department of General Surgery, Sismanoglion General Hospital, Athens, Greece*
[2]*Department of Pathology, Sismanoglion General Hospital, Athens, Greece*

ABSTRACT

Appendiceal endometriosis is a rare form of endometriosis that may mimic acute appendicitis, thereby posing a diagnostic challenge in surgical practice. Preoperative differentiation between these entities remains difficult due to the nonspecific nature of the condition in terms of clinical presentation and imaging findings. Herein, we report a case of a young woman who presented with right iliac fossa pain and nausea. Laboratory investigations and imaging findings on ultrasound and computed tomography were suggestive of acute appendicitis. The patient underwent laparoscopic appendectomy, and histopathological examination revealed appendiceal endometriosis. This case demonstrates the inherent limitations of preoperative diagnosis and highlights that surgical management is generally guided by clinical suspicion of acute appendicitis rather than by aetiological identification. The important role of laparoscopy in both diagnosis and management was addressed. Particular emphasis is given to diagnostic considerations, intraoperative assessment, and implications for general surgeons managing women of reproductive age with suspected acute appendicitis.

Key words: *Appendiceal endometriosis; acute appendicitis; laparoscopic appendectomy; case report*

INTRODUCTION

Endometriosis is an estrogen-dependent condition characterised by the presence of endometrial glands and stroma outside the uterine cavity and myometrium. The estimated prevalence is approximately 8-10% among women of reproductive age. Endometriosis can occur at several anatomical sites, including pelvic sites, which involve the ovaries, oviducts, and recto-uterine ligaments. Less frequently, it may occur at extra-pelvic sites, including the gastrointestinal (GI) or urinary tract, chest cavity, and soft tissues [1].

Gastrointestinal involvement is relatively uncommon, and appendiceal endometriosis (AE) represents a rare manifestation of the disease. It may occur in women with previously diagnosed endometriosis as well as in those without a known gynaecological history. From a general surgical perspective, the clinical significance of this entity lies not in altering acute operative management, but in its postoperative recognition and the subsequent consideration of underlying endometriosis, particularly in women of reproductive age. This case report aims to highlight the diagnostic limitations and to discuss the clinical implications for general surgeons who will manage similar presentations. Written informed consent was obtained from the patient. This report was conducted in

Corresponding author:
Panayiotis Antoniou
Sismanogliou 1, Marousi, Athens, Greece 15126
Tel.: +30 6944 561 029, e-mail: panayiotis.antoniou@outlook.com

Submission: 06.06.2026, Acceptance: 01.11.2026

accordance with the Declaration of Helsinki, and ethical approval was provided by the scientific council of the Institute. This case report was prepared in accordance with the CARE Guidelines.

CASE REPORT

A 39-year-old female patient (G0P0) presented to the A&E department complaining of right lower quadrant pain accompanied by nausea. The onset of pain was 24 hours earlier without any correlation with her menstrual cycle. She was on day 21 of her menstrual cycle, which was regular, and the patient did not report cyclic pelvic pain or any other gynaecological symptoms. The medical and gynaecological history was unremarkable, and no previous surgeries were reported. The patient was afebrile and haemodynamically stable. Physical examination revealed right lower quadrant pain, accompanied by rebound tenderness, with positive McBurney's sign. Laboratory results showed an elevated white blood cell count of 19000/μL with an increased neutrophil count of 83% and C-reactive protein at 28 (normal range: <6 mg/dL). Beta-human chorionic gonadotropin testing was negative. Abdominal ultrasound scan revealed fluid accumulation in the right lower quadrant area accompanied by a dilated tubular structure. Contrast-enhanced abdominal CT scan demonstrated a mildly dilated intrapelvic appendix (6.67 mm) with focal swelling at the tip, extending parallel to the right parametrium. A small adjacent fluid collection and fat stranding were also reported (Figure 1).

Taking all of the above into account, laparoscopic exploration was performed. The intraoperative findings were consistent with those described on the CT scan, revealing a mildly dilated and edematous appendix mainly at the tip with a small amount of fluid. No macroscopic features suggestive of endometriosis were observed in the appendix. Furthermore, a systematic laparoscopic inspection of the abdominal and pelvic cavities was performed to identify any additional macroscopic endometriotic lesions. However, no such lesions were identified. Laparoscopic appendectomy was carried out successfully. The postoperative period was uneventful, and the patient was discharged 48 hours after the operation. Gynaecological assessment was then performed to determine the extent of endometriosis, however no other endometriotic lesions were identified. Histopathological report demonstrated an appendix measuring 4.1x0.6 cm in diameter, and at the tip, multiple foci of endometrial tissue were revealed (ER, CD10: compatible immunophenotype). On the serosal surface, focal fibrinopurulent exudates were observed, with accompanying changes of mesothelial/histiocytic hyperplasia [WT-1 (+), CD68 (+)] (Figure 2). The patient was advised to undergo further outpatient gynaecological evaluation for the management of endometriosis.

DISCUSSION

Appendiceal endometriosis is a rare but important differential diagnosis within the spectrum of appendiceal pathology. In clinical practice, it most commonly presents with signs and symptoms indistinguishable from acute appendicitis, leading to surgical management based on a presumptive diagnosis rather than aetiological certainty. Consequently, the definitive diagnosis is typically established only after histopathological examination of the resected appendix. This diagnostic uncertainty, however, does not influence initial operative decision-making, as the standard surgical approach remains appendectomy in the setting of suspected acute appendicitis.

Carl von Rokitansky was the first to describe appendiceal endometriosis (AE) in 1860. AE is rare, especially in women with an unremarkable gynaecological history. The estimated prevalence in the general population is 0.4% and can reach up to 1.7% in patients with a known history of endometriosis [2,3]. Patients with AE may be asymptomatic or present with symptoms similar to those of acute appendicitis such as lower abdominal pain, anorexia, nausea, and vomiting. AE may cause cyclic right lower quadrant pain associated with menstruation, melena or lower GI tract bleeding and, in severe cases, cecal intussusception or perforation. Based on the current literature, the prevalence of appendiceal endometriosis among women undergoing surgery



FIGURE 1. Computed tomography scan findings. Contrast-enhanced CT scan demonstrating a mildly dilated intrapelvic appendix (6.67 mm in diameter) with focal swelling of the tip (arrow). The appendix extends parallel to the right parametrium and is associated with a small adjacent fluid collection and surrounding fat stranding.

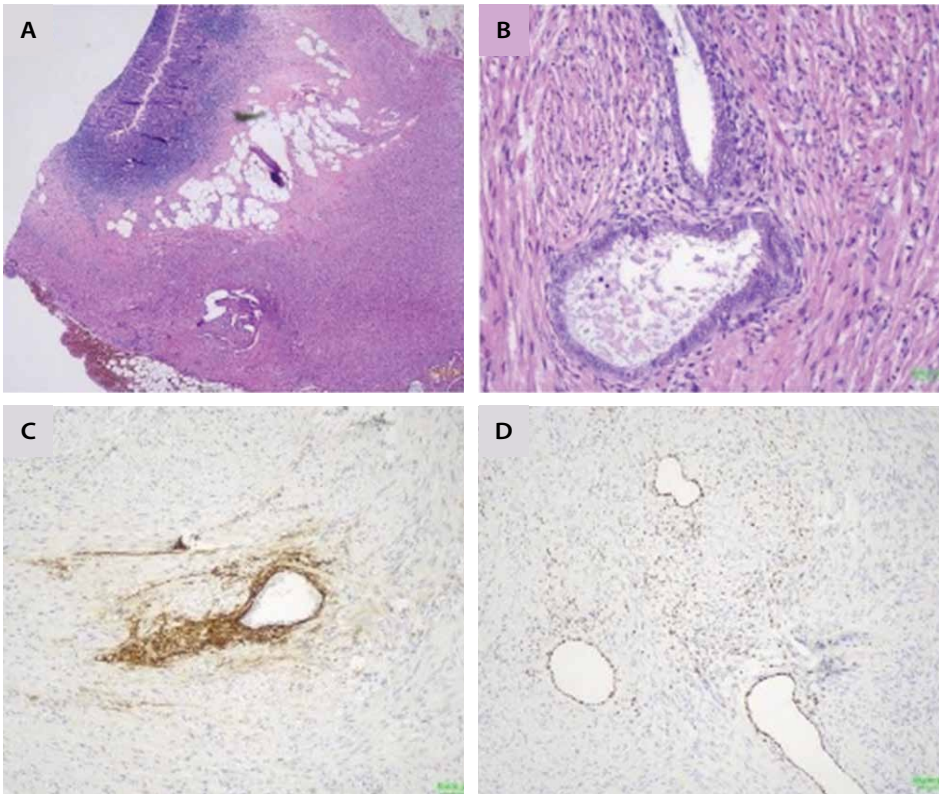

FIGURE 2: Appendiceal endometriosis involving the muscular wall. (A) Low-power view of the appendiceal wall demonstrating a nodular focus of endometriosis within the muscularis propria, composed of endometrial glands and stroma associated with surrounding fibrosis and mild inflammatory infiltrate (H&E, ×20). (B) Higher magnification showing endometrial-type glands lined by a single layer of columnar epithelial cells without cytologic atypia, surrounded by characteristic endometrial stroma (H&E, ×200). (C) Immunohistochemical staining for CD10 highlights the stromal component with diffuse cytoplasmic positivity, confirming endometrial stromal differentiation (CD10, ×100). (D) Immunohistochemical staining for estrogen receptor (ER) demonstrates nuclear positivity in both glandular epithelial and stromal cells, supporting endometrial origin (ER, ×100).

who present with a clinical picture resembling acute appendicitis is 2.67% [1].

The pathogenesis of appendiceal endometriosis remains incompletely understood and is likely multifactorial. Sampson's theory of retrograde menstruation, which proposes the reflux and implantation of viable endometrial tissue through the fallopian tubes, remains the most widely accepted mechanism for endometriosis development and may explain appendiceal involvement through pelvic dissemination. Histopathological findings demonstrating endometriotic implants predominantly within the muscularis propria and subserosal layers of the appendix support the possibility of ectopic transplantation. However, the presence of appendiceal endometriosis in patients without concurrent ovarian or pelvic disease challenges retrograde menstruation as the sole pathogenic mechanism. Alternative pathways, including coelomic metaplasia and lymphatic or haematogenous dissemination have therefore been proposed. These mechanisms may contribute to the occurrence of isolated appendiceal endometriosis and explain its heterogeneous clinical presentation [1, 4].

Ectopic endometrial tissue within the appendix responds to cyclical hormonal stimulation, causing haemorrhage, chronic inflammation, fibrosis, and luminal obstruction. These mechanisms account for the wide spectrum of symptomatology, ranging from nonspecific abdominal symptoms to a classic presentation of acute appendicitis. AE may involve either the tip or the body of the appendix, without affecting the presentation. In contrast, the depth of appendiceal wall involvement may influence the clinical manifestations. In the majority of reported cases, endometriotic lesions are located within the muscular or seromuscular layers. When the mucosa or submucosa is involved, patients are more likely to present with symptoms resembling inflammatory, ischaemic, or infectious enteritis or colitis [5].

The clinical presentation and laboratory findings of AE are similar to those of acute appendicitis, as previously described. In this case, the absence of gynaecological

symptoms and the lack of known history of endometriosis further limited preoperative recognition. In addition, the patient's pain was not associated with her menstrual cycle, a characteristic commonly observed in endometriosis-related pathology, further reducing the clinical suspicion that the pain was attributable to endometriosis. This reflects a key diagnostic challenge, as clinical assessment alone is insufficient for reliable identification of AE in the acute setting. Patients can be categorised into four categories: (a) asymptomatic with incidental diagnosis, (b) presenting with acute appendicitis, characterised by right lower quadrant pain and potential complications such as perforation, (c) appendiceal invagination characterised by intussusception and "currant jelly" stools, and (d) atypical symptoms such as abdominal colic, nausea, vomiting, melena, constipation, and fever [5].

Imaging modalities are routinely used in the evaluation of suspected acute appendicitis; however, in the context of appendiceal endometriosis, their diagnostic value is limited [6]. Radiological findings are typically nonspecific and largely indistinguishable from uncomplicated appendiceal inflammation, most commonly demonstrating mild appendiceal enlargement, mural thickening, periappendiceal fat stranding, or minimal fluid collection. Although these features support a diagnosis of appendicitis, they do not provide reliable indicators of ectopic endometrial tissue involvement. Both ultrasound and cross-sectional imaging lack specific criteria for identifying appendiceal endometriosis, and reported findings overlap with those of routine inflammatory appendiceal disease. Consequently, imaging alone is insufficient for preoperative differentiation, and a definitive diagnosis cannot be established on radiological grounds [3,7].

From a surgical perspective, the management of suspected appendiceal pathology is primarily guided by clinical assessment and imaging findings consistent with acute appendicitis, rather than aetiological certainty. In this context, uncertainty regarding rare underlying causes such as appendiceal endometriosis does not typically modify the operative decision-making pathway. Laparoscopy plays a central role in this setting, offering both diagnostic and therapeutic advantages by enabling direct visualisation of the appendix and the entire peritoneal cavity, as well as facilitating definitive appendectomy with low morbidity. The author's opinion is that, although in the present case no additional endometriotic lesions were identified, a systematic intraoperative assessment may be considered in women of reproductive age, particularly when intra-abdominal findings raise suspicion of endometriosis or when there is a relevant gynaecological history. In selected cases, intraoperative gynaecological consultation or evaluation may further assist in guiding comprehensive management. Importantly, given the inability to reliably differentiate appendiceal endometriosis from routine appendicitis preoperatively, laparoscopic appendectomy is commonly employed when clinical and radiological findings support a diagnosis of acute appendicitis [1,8,9].

CONCLUSION

The current literature suggests that AE is a relevant differential diagnosis in women of reproductive age presenting with acute abdominal pain and is usually identified incidentally following appendectomy for suspected appendicitis. As can be inferred from the above, preoperative diagnosis of AE is challenging in the acute setting due to similarities in clinical presentation and imaging findings with acute appendicitis. This is even more challenging when the woman has an unremarkable gynaecological history. Standard management pathways for suspected appendicitis should therefore be followed, as the possibility of AE does not alter the surgical management. Laparoscopic appendectomy followed by histopathological examination remains the definitive diagnostic and therapeutic approach. Postoperative recognition of AE and subsequent gynaecological evaluation are of vital importance.

Conflict of Interest Statement: *The authors declare no conflicts of interest.*

Funding statement: *The authors received no financial support for the research, authorship, and/or publication of this article.*

Author Contributions: *Conception: Bounovas Athanasios conceived the original idea and performed the patients' operation. Design: Skouroumouni Giorgos, Antoniou Panayiotis; Literature search: Skouroumouni Giorgos, Antoniou Panayiotis; Manuscript preparation: Skouroumouni Giorgos, Antoniou Panayiotis; Manuscript editing: Skouroumouni Giorgos, Antoniou Panayiotis; Manuscript review: All Authors; Supervision: All authors; Final approval of manuscript: All Authors.*

Ethical Approval: *Ethical approval to report this case was obtained from the ethical committee of the scientific council of Sismanoglion General Hospital of Athens (approval number/ID: 6849).*

Consent form: *Written informed consent was obtained from the individual for the publication of personal information.*

Declaration of conflicting interest: *The authors declared no potential conflicts of interest with respect to the research, authorship, and/or publication of this article.*

Data Availability statement: *Data available upon request from the corresponding author.*

REFERENCES

1. Allahqoli L, Mazidimoradi A, Momenimovahed Z, Günther V, Ackermann J, Salehiniya H, et al. Appendiceal Endometriosis: A Comprehensive Review of the Literature. Diagnostics (Basel). 2023 May 23;13(11):1827.
2. Mabrouk M, Raimondo D, Mastronardi M, Raimondo I, Del Forno S, Arena A, et al. Endometriosis of the Appendix: When to Predict and How to Manage—A Multivariate Analysis of 1935 Endometriosis Cases. J Minim Invasive Gynecol. 2020 Jan;27(1):100-6.
3. Bolcatto A, Erina M, Mandojana FI, Bruera N, Doniquian AM, Viscido GR. Acute appendicitis due to appendiceal endometriosis: Two case report and literature review. Int J Surg Case Rep [Internet]. 2025 Jan [cited 2026 Oct 15];126:110743. Available from: https://www.ovid.com/jnls/ijscr/fulltext/10.1016/j.ijscr.2024.110743~acute-appendicitis-due-to-appendiceal-endometriosis-two-case
4. Emre A, Akbulut S, Yilmaz M, Bozdag Z. An unusual cause of acute appendicitis: appendiceal endometriosis. Int J Surg Case Rep. 2013;4(1):54-7.
5. Zondervan KT, Becker CM, Missmer SA. Endometriosis. N Engl J Med. 2020 Mar;382(13):1244-56.
6. Laskou S, Papavramidis TS, Cheva A, Michalopoulos N, Koulouris C, Kesisoglou I, et al. Acute appendicitis caused by endometriosis: A case report. J Med Case Rep. 2011 Apr;5:144.
7. Kemal Memisoglu, Bora Karip, Metin Mestan, Ender Onur. The value of preoperative diagnostic tests in acute appendicitis, retrospective analysis of 196 patients. World J Emerg Surg [Internet]. 2010 Feb [cited 2026 Oct 15];5(5). Available from: https://link.springer.com/article/10.1186/1749-7922-5-5
8. Aragone L, Pasquini MT, Scasso Rebzda V, Talarico MS, Mihura M. Appendiceal endometriosis: case report of a rare differential diagnosis of acute appendicitis. Int J Surg Case Rep. 2023 Apr [cited 2025 Oct 15];105:107993. Available from: https://www.ovid.com/jnls/ijscr/fulltext/10.1016/j.ijscr.2023.107993~appendiceal-endometriosis-case-report-of-a-rare-differential

Case Report

Hell J Surg. 2025 Jul-Sep;95(3):162–165
doi: 10.59869/25078

Lipofuscin Pigmentation of the Gallbladder: A Rare Case Report and Literature Review

Dimitra Smerdi[1], Panagiotis Stratigos[1], Mpoltetsou Eumorfia[2], Panagiotis-Akindynos Petrozellis[1], Sotiris Megalemos[1], Katsaounis Dionusios[1], Rallis Georgios[1]

[1] *Surgical Department, "Elpis" General Hospital of Athens, Athens, Greece*
[2] *Pathology Department, "Elpis" General Hospital of Athens, Athens, Greece*

ABSTRACT

Pseudomelanosis is an umbrella term for a commonly encountered condition of the lower, but certainly rare in the upper, gastrointestinal tract. Plenty of other situations are associated with its incidence and medication usage as well. Most of the case reports in the literature refer to pseudomelanosis of the stomach, duodenum, and, uncommonly, oesophagus. In this paper, we present a rare case of gallbladder lipofuscin pseudomelanosis in a 25-year-old woman undergoing cholecystectomy. The aim of this study is to demonstrate a histopathological entity that has been rarely reported previously, highlighting the importance of avoiding misdiagnosis. The pathogenesis of the pseudomelanosis requires yet further investigation, as well as correlation with existing pathology findings.

Key words: *Gallbladder pseudomelanosis; histochemistry; lipofuscin pigmentation of the gallbladder; dark-colored gallbladder*

Pseudomelanosis of the gastrointestinal (GI) tract is an uncommon condition that is associated with certain predisposition factors; thus, it is mostly encountered as an incidental finding during gastrointestinal endoscopy for diagnostic and therapeutic purposes [1]. This discovery presents as pigmented black dots that cover the mucosa of the gastrointestinal tract, mimicking melanin accumulation [2]. This phenomenon is mainly observed in the lower GI tract and less commonly reported in the upper GI tract [3].

Pseudomelanosis is an umbrella term; microscopically, it is primarily caused by haemosiderin, lipofuscin, and iron or iron sulfide deposition in the mucosa, usually in the epithelial cells or histiocytes [4,5]. Various conditions are associated with pseudomelanosis, such as hypertension, diabetes mellitus, kidney impairment, and certain medications [2,5].

Pigment deposition within the gallbladder has been reported through the years, usually expressed as "melanosis" or a "dark-colored gallbladder"; thus, these cases commonly are not histopathologically proven. Some of these cases may report lipofuscin, haemosiderin, or iron accumulation, but well-documented cases describing definite lipofuscin pigmentation are rare.

In the current English-language literature, pseudomelanosis is mainly identified in gastric and duodenal endoscopy [6] and following histopathological examination, with the gallbladder not being so commonly reported. Its gross appearance as a black-colored gallbladder may cause clinical dilemmas and lead to misdiagnosis.

Herein, we present a rare case of gallbladder pseudomelanosis due to lipofuscin deposition, identified during routine biliary surgery.

Corresponding author:
Dimitra Smerdi
Imittou 129, Athens, 11 633, Athens, Greece
Tel.: +30 6978 137487, e-mail: demi.smerdi@gmail.com

Submission: 18.06.2026, Acceptance: 27.09.2026

CASE REPORT

Preoperative Assessment

A 25-year-old woman with no significant medical history and recurrent upper abdominal pain, mainly post-prandial, along with several episodes of biliary colic presented to our outpatient clinic. Her laboratory investigation was normal, while abdominal ultrasonography revealed a gallbladder without inflammatory features, along with gallstones and a thickened wall. The symptoms were compatible with chronic gallstone cholecystitis, and the patient was scheduled for laparoscopic cholecystectomy.

Surgical Management

During the operation, while inspecting the surgical site, the gallbladder was noted to be dark-colored, with a thickened and sclerotic wall. During the subserosal cholecystectomy, while dissecting the gallbladder from the liver bed in retrograde fashion, a preoperatively unrecognised replaced right hepatic artery that arose from the superior mesenteric artery was inadvertently torn, leading to severe haemorrhage and haemodynamic instability. The cholecystectomy was converted to an open procedure. Then, common bile duct injury occurred due to the massive haemorrhage. The common bile duct injury was not identified intraoperatively, the haemorrhage was controlled, and the cholecystectomy was completed.

Postoperative Course

The common bile duct injury led to the formation of a high-volume bilio-cutaneous fistula postoperatively. The postoperative computed tomography (CT) angiography confirmed a replaced right hepatic artery, a Michels type III anatomical variant (Figure 1). The patient was then referred for definite management at a tertiary hepatobiliary center.

Histopathological Examination

Regarding the histopathological examination, the gallbladder was dark-colored, with thickened walls. Microscopic examination revealed black staining within the mucosa's histiocytes that could be melanin or other pigments, such as haemosiderin, iron sulfide, or lipofuscin. The Fontana-Masson stain was negative, as was Perl's Prussian Blue. In contrast, the periodic acid–Schiff (PAS) stain was positive, indicating that lipofuscin was the cause of the pigmentation (Figure 2).

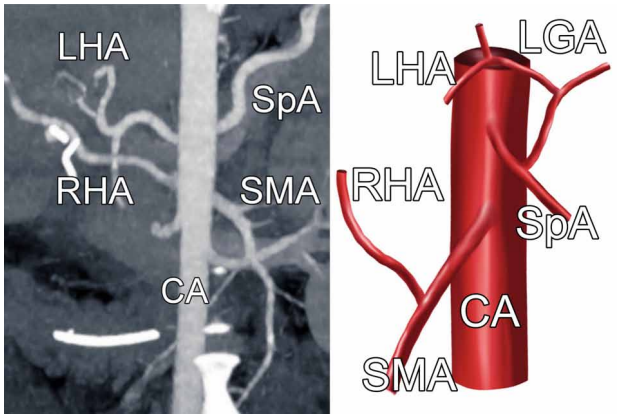

FIGURE 1. Computed Tomography Angiography showing the replaced RHA arising from the SMA and 3D illustration showing the previously discussed anatomic variant of the RHA. CA celiac aorta, LHA left hepatic artery, RHA right hepatic artery, SMA superior mesenteric artery, SpA splenic artery.

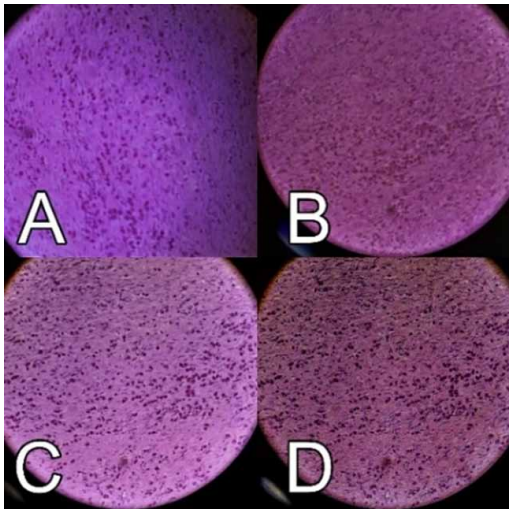

FIGURE 2. Microscopic findings of gallbladder pseudomelanosis A), B) microscopic examination of gallbladder without PAS stain, showing black stain in the mucosa that could be melanin or other stains C), D) microscopic examination of gallbladder after PAS stain, proving that the black dots are not from melanin pigmentation; it's lipofuscin, as Fontana-Masson and Perl's wre negative.

DISCUSSION

Lipofuscin pigmentation of the gallbladder is a rare histopathological finding. Pseudomelanosis is a descriptive term, rarely encountered in the upper gastrointestinal tract, and it is the result of iron or haemosiderin accretion in the mucosa, which is visualised endoscopically as black or dark brown dots [7,8].

Histologically, this endoscopic image is associated with macrophage's pigment deposition in the lamina propria of the mucosa, which can be haemosiderin, lipofuscin,

and iron sulfide [9]. In the present case, the negative Perl's stain and Fontana-Masson stain, in combination with the positive PAS stain, indicate that the accumulated substance is lipofuscin. Other previously reported cases with no histologically proven melanosis may also bear lipofuscin pigmentation. However, the conducted literature research only led to the identification of a prior report from 1980 that cannot be obtained. As a result, we should acknowledge that this is an exceptionally rare case report of this pathological entity. Moreover, the very detailed, well-documented histopathological examination confirms the aforementioned diagnosis.

The pathogenesis behind pseudomelanosis due to lipofuscin pigmentation is correlated with lipofuscin formation. Lipofuscin, also referred to as the "wear-and-tear pigment", is primarily formed due to oxidative stress and age-related cellular alterations [10]. Its accumulation is linearly associated with lysosomal instability and eventual cellular apoptosis [11]. In our case, chronic inflammation of the gallbladder may have led to lipofuscin pigmentation and potent macrophage activation due to the chronic oxidative stress.

Pseudomelanosis of the lower gastrointestinal tract, also known as melanosis coli, is a common endoscopic finding, mainly encountered during endoscopic procedures, that is primarily correlated with chronic constipation and laxative usage [3]. In general, pseudomelanosis has been associated with many conditions, such as diabetes mellitus, chronic kidney disease, hypertension, and a history of gastrointestinal bleeding [1,12]. Additionally, the utilization of certain medications, including iron supplements, hydralazine, beta-blockers, and thiazide diuretics, seems to also play a role in pseudomelanosis occurrence [1,8,9].

Furthermore, Agrawal et al. (2017) mentioned a possible connection between hyperplastic polyps of the colon and pseudomelanosis [8]; thus, despite the fact that this relation cannot be ruled out, more investigation is needed in this area, and more research should be conducted. In our case, the coincidence of the pseudomelanosis with a replaced right hepatic artery was incidental and should be taken into account as such.

Despite pseudomelanosis due to lipofuscin pigmentation of the gallbladder being a completely benign histopathological entity, it can result in surgical dilemmas. Intraoperatively, this appearance could mimic gangrenous cholecystitis, a possible local carcinoma, a haemorrhagic infarction of the gallbladder, or even a porcelain gallbladder. Given that pseudomelanosis of the gallbladder is rarely reported, the surgeon may convert a laparoscopic operation to an open one due to misinterpretation of the intraoperative findings. In our case, however, the conversion was necessitated by vascular haemorrhage and not the color of the gallbladder. Nevertheless, we should note that, in other cases, the rare gross appearance of the pseudomelanosis may lead to surgical dilemmas and unnecessary conversions.

As gallbladder pseudomelanosis is an existing histopathological entity, surgeons should consider it in any case of a dark-colored gallbladder and not convert the operation relying solely on this finding. Additionally, pathologists and surgeons should build a strong collaboration in identifying such cases. More cases like this should be reported in order to raise awareness of this phenomenon, and more research needs to be conducted in the future to possibly correlate it with chronic ongoing oxidative stress of the gallbladder.

PATIENT PERSPECTIVE

The patient tolerated these procedures well, and despite her prolonged clinical course, is currently in good clinical condition.

CONCLUSION

Lipofuscin pigmentation of the gallbladder is a rare form of pseudomelanosis and is typically an incidental finding on microscopic examination. It is mainly presented as a thickened-wall, dark-colored gallbladder, with black mucosa dots on macroscopic examination. While it has minimal clinical significance, its gross appearance may lead to intraoperative misdiagnosis and expose the patient to surgical risks.

Informed Consent: *In accordance with the Declaration of Helsinki, the patient provided written informed consent for publication of the case report and the accompanying images.*

Conflict of Interest: *The authors declare no conflict of interest.*

REFERENCES

1. Samies J, Shah RN, Pramick M, Unzueta A. Gastric pseudomelanosis: An uncommon finding. Case Rep Gastrointest Med [Internet]. 2022;2022:6290510. Available from: https://pmc.ncbi.nlm.nih.gov/articles/PMC9356900/
2. Lopez G, D'Ercole M, Ferrero S, Croci GA. Duodenal pseudomelanosis: A literature review. Diagnostics (Basel). 2021 Oct;11(11):1974.
3. Kevin PC, Xuchen Z. Pseudomelanosis of the stomach and duodenum. J Clin Gastroenterol Treat [Internet]. 2018;4(2). Available from: https://clinmedjournals.org/articles/jcgt/journal-of-clinical-gastroenterology-and-treatment-jcgt-4-057.php?jid=jcgt

4. Yang N, Ruan M, Jin S. Melanosis coli: A comprehensive review. Gastroenterol Hepatol. 2020 May;43(5):266-72.
5. Kim SY, Choung RS, Kwon BS, Hyun JJ, Jung SW, Koo JS, et al. Small bowel pseudomelanosis associated with oral iron therapy. J Korean Med Sci. 2013 Jul;28(7):1103-6.
6. Tang SJ, Zhang S, Grunes DE. Gastric and duodenal pseudomelanosis: a new insight into its pathogenesis. VideoGIE. 2019 Aug;4(10):467-8.
7. John S, Mehta N, Kaul V, Murthy UK. First reported case of pseudomelanosis gastri. Am J Gastroenterol. 2006;101:1383.
8. Agrawal A, Jain D, Arguello V, Sher D. Hyperplastic polyps and gastroduodenal pseudomelanosis. Case Rep Gastrointest Med [Internet]. 2017 Nov;2017:4270248. Available from: https://pmc.ncbi.nlm.nih.gov/articles/PMC5705894/
9. Wael Mohamed M, Althahabi R, Abubaker F, Sharif O. An incidental finding of gastric and duodenal pseudomelanosis: A case report. Case Rep Gastroenterol. 2022 Apr;16(1):264-9.
10. Katz ML, Robison WG Jr. What is lipofuscin? Defining characteristics and differentiation from other autofluorescent lysosomal storage bodies. Arch Gerontol Geriatr. 2002 May-Jun;34(3):169-84. doi:10.1016/s0167-4943(02)00005-5
11. Brunk UT, Terman A. Lipofuscin: Mechanisms of age-related accumulation and influence on cell function. Free Radic Biol Med. 2002 Sep;33(5):611-9.
12. Giusto DJS. Pseudomelanosis duodeni: Associated with multiple clinical conditions and unpredictable iron stainability - a case series. Endoscopy. 2008 Feb;40(2):165-7.

INSTRUCTIONS TO AUTHORS

BEFORE YOU BEGIN

Uniform requirements of ICMJE (International Committee of Medical Journal Editors)

Before submitting their manuscript, authors should check that they conform to the Uniform Requirements of the International Committee of Medical Journal Editors (www.ICMJE.org).

Types of manuscripts published

Manuscripts submitted must be based on original work and not have been published, submitted or accepted for publication elsewhere. The Journal accepts the following kinds of manuscripts:

1. Editorial
2. Original article
3. Review
4. Systematic review / Meta-analysis
5. Case report / series
6. How I do it
7. Commentary
8. Letter to the Editor
9. Surgical history
10. Perspective
11. Brief communication
12. Surgical image

Confidentiality

HJS editors and publication staff keep all information about a submitted manuscript confidential and limited to those involved in the evaluation, review and publication process. Only the Editor-in-Chief, the Managing and Associate Editors and the allocated Subject Editors are aware of the names of manuscript authors and their affiliations. HJS has a double-blind review process so that authors' names and affiliations are not revealed to reviewers nor are reviewers' names revealed to authors. Only information on accepted articles is archived for future reference.

Primary publication

Manuscripts submitted to the journal must represent reports of original research, and the original data must be available for review by the editor if necessary. By submitting a manuscript to the journal, the authors guarantee that they have the authority to publish the work and that the manuscript, or one with substantially the same content, was not published previously, is not being considered or published elsewhere, and was not rejected on scientific grounds by another journal. It is incumbent upon the author to acknowledge any prior publication, including his/her own articles, of the data contained in a manuscript submitted to the journal. A copy of the relevant work should be submitted with the paper as supplemental material not for publication. Whether the material constitutes the substance of a paper and therefore renders the manuscript unacceptable for publication is an editorial decision. In the event that the authors' previously published figures and/or data are included in a submitted manuscript, it is incumbent upon the corresponding author to (i) identify the duplicated material and acknowledge the source on the submission form, (ii) obtain permission from the original publisher (i.e., copyright owner), (iii) acknowledge the duplication in the figure legend, and (iv) cite the original article.

Authorship

Authorship must be based on all of the following four criteria: 1) Substantial contributions to conception and design, acquisition of data, or analysis and interpretation of data; 2) Drafting the article or revising it critically; 3) Final approval of the version to be published and 4) Agreement to be accountable for all aspects of the work in ensuring that questions related to the accuracy or integrity of any part of the work are appropriately investigated and resolved. All contributors who do not meet the criteria for authorship should be listed in an acknowledgements section at the end of the article.

Authorship changes

Authorship changes must be requested before publication of an article in an online issue. Requests for the addition, removal and re-arrangement of authors should be sent to the Submission Manager from the corresponding author with an appropriate statement which must state the reason. Agreement will be requested by all authors following evaluation of the request by the Editorial Board.

Conflict of interest

Trust in the peer review process and the credibility of published articles depends partly on the handling of conflict of interest issues in the writing, peer review and editorial decision-making process. Conflict of interest exists when an author (or the author's institution), reviewer or editor has financial or personal relationships that inappropriately influence his/her actions. These people must disclose all relationships that could be viewed as potential conflicts of interest. Authors need to add a Conflict of Interest statement in the Cover Letter. In addition, a Conflict of Interest statement must be added in the main manuscript just before References. The editors may use this information as a basis for editorial decisions and may publish it in the Journal. Peer-reviewers are requested to declare any conflict of interest. HJS Subject Editors have to declare any conflict of interest before taking responsibility for a manuscript.

Informed consent

Patients have a right to privacy that should not be infringed without informed consent. HJS does not publish identifying information in written descriptions or images unless the information is essential for scientific purposes and the patient (or guardian) has given written informed consent for publication. This requires that a patient who is identifiable be shown the manuscript before publication. If identifying characteristics are altered to protect anonymity, such as in genetic pedigrees, authors should provide assurance that alterations do not distort scientific meaning and editors should note this. When informed consent has been obtained, it should be indicated in the manuscript.

Ethics in publishing

All studies on human or animal subjects must contain a statement about ethical permission for the study including the name of the organization which granted it. Such studies must be in accordance with the ethical standards of the responsible committee on human experimentation (institutional and national) and with the Helsinki Declaration of 1975, as revised in 2008. If doubt exists whether the research was conducted in accordance with the Helsinki Declaration, the authors must explain the rationale for their approach, and demonstrate that the institutional review body explicitly approved the doubtful aspects of the study. When reporting experiments on animals, authors should indicate whether the institutional and national guidelines for the care and use of laboratory animals were followed.

Copyright

Copyright of the accepted manuscripts will transfer from the authors to the Hellenic Journal of Surgery. Copyright covers all publication forms and media, now or hereafter known, and is effective as soon as a manuscript is accepted for publication in HJS. The corresponding author should submit to the journal the copyright transfer agreement form signed by all authors. In case of submission of an original paper that has been already published in a foreign journal, it must be clearly stated that the authors have obtained the writ-

ten permission of the copyright owners, a copy of which must be attached. The final revised text will be resubmitted electronically in WORD and PDF form. All papers published in HJS are owned by the journal and are not allowed to be republished without the written consent of the Editor in chief. The authors retain the following nonexclusive copyrights, to be exercised only after the manuscript has been published in online format on the HJS website:

a. Reprint the manuscript in print collections of the author's own writing.
b. Present the manuscript orally in its entirety.
c. Use the manuscript in theses and/or dissertations.
d. Reproduce the manuscript for use in courses the author is teaching. (If the author is employed by an academic institution, that institution may also reproduce the manuscript for course teaching.)
e. Distribute photocopies of the manuscript to colleagues, but only for non-commercial purposes.
f. Reuse figures and tables created by the author in future manuscripts the author writes.
g. Post a copy of the manuscript on the author's personal website, departmental website, and/or the university's intranet, provided a hyperlink to the manuscript on the HJS website is included.

In all the above instances, the author shall give proper credit to the original publication in SQUMJ as follows: This research was originally published in HJS. Author(s). Title. HJS Year;vol:pp-pp. © by Hellenic Journal of Surgery.

User rights

Users have the right to read, download, copy, distribute, print, search, or link to the full texts of articles under the following conditions: Creative Commons Attribution 4.0 International (CC BY 4.0).

Scientific misconduct policy

Following the World Association of Medical Editors (WAME), SQUMJ defines scientific misconduct as:

1. ***Falsifying data:*** Inventing data, selective reporting or the omission, suppression or distortion of data.
1. ***Plagiarism:*** Using the published or unpublished language, ideas, or thoughts of another writer without reference or permission and presenting them as one's own. Plagiarism includes self-plagiarism (duplication of portions of your own previously published work), duplicate publication (publication of an article in more than one journal or in another language) and redundant publication (more than 10% of an article overlapping with another submission/ publication).
1. ***Authorship issues:*** Exclusion of involved researchers, or inclusion of researchers who have not contributed to the work, or publication without permission from all authors.
1. ***Disregard for generally accepted research practice:*** Manipulation of experiments/statistics to get biased results, or improper reporting of results, for example.
1. ***Failure to follow legal requirements:*** Violation of local regulations and laws involving the use of funds, copyright, care of animals, human subjects, investigational drugs, recombinant products, new devices, or radioactive, biological or chemical materials.
1. ***Inappropriate behavior in cases of misconduct:*** False accusations of misconduct; failure to report misconduct; not providing information relevant to a misconduct claim; and retaliation against people claiming or investigating misconduct, for example.

HJS takes all these forms of misconduct extremely seriously. It follows the Committee on Publication Ethics (COPE) guidelines. The final decision on action is taken by the Editor-in-Chief.

Funding source

You are requested to identify who provided financial support for the conduct of the research and/or preparation of the article and to briefly describe the role of the sponsor(s), if any, in study design; in the collection, analysis and interpretation of data; in the writing of the report; and in the decision to submit the article for publication. If the funding source(s) had no such involvement, it is recommended to state this. A Funding statement must be added both in the Cover Letter and in the main manuscript just before References.

Open access

HJS is an Open Access Journal. This means that all content is freely available without charge to the user or his/her institution. Users have the right to read, download, copy, distribute, print, search, or link to the full texts of articles under the following conditions: Creative Commons Attribution 4.0 International (CC BY 4.0). This is also in accordance with the Budapest Open Access Initiative (BOAI) definition of open access.

PREPARING THE MANUSCRIPT

Submission checklist

You can use this list to carry out a final check of your submission before you send it to the journal for review.

Ensure that the following items are present:

One author has been designated as the corresponding author with contact details:

- E-mail address
- Full postal address

All necessary files have been uploaded:

Manuscript:

- Include keywords
- All figures (include relevant captions)
- All tables (including titles, description, footnotes)
- Ensure all figure and table citations in the text match the files provided
- Indicate clearly if color should be used for any figures in print

Supplemental files (where applicable)

Further considerations:

Manuscript has been 'spell checked' and 'grammar checked'
All references mentioned in the Reference List are cited in the text, and vice versa
Permission has been obtained for use of copyrighted material from other sources (including the Internet)
A competing interests statement is provided, even if the authors have no competing interests to declare
Journal policies detailed in this guide have been reviewed
Referee suggestions and contact details provided, based on journal requirements

Types of papers

Types of papers that can be submitted for consideration by the Editorial Board include:

1. **Editorial.** Invited leading articles commissioned by the editorial team. Word and reference limits:800–1000 words and up to 10 references. Submissions will be subjected to peer review and the Editors retain the right to alter textual style.
2. **Original article.** Full-length original research articles, representing substantial, novel research in general surgery. **Word and reference limits:**Text: 3500 words, excluding abstract, references, tables, and figures; Structured abstract: 250 words; References: 50 maximum. A maximum combined number of 7 tables & figures may be included for publication. Additional tables and figures may be included as online-only supplemental data content. All clinical trials that prospectively assign human subjects to medical interventions, comparison groups, or control groups should ensure that all elements in the CONSORT checklist are covered. A copy of the CONSORT checklist must be uploaded as supplemental material. Please refer to the CONSORT state-

ment website at http://www.consort-statement.org for more information. Submitted manuscripts must include the unique registration number in the abstract as evidence of registration. In addition, experimental animal studies must be reported in accordance with the ARRIVE guidelines and must include the checklist as supplemental material *(Animals in Research: Reporting In Vivo Experiments, Kilkenny C, Browne WJ, Cuthill IC, Emerson M, Altman DG (2010) Improving Bioscience Research Reporting: The ARRIVE Guidelines for Reporting Animal Research. PLoS Biol 8(6): e1000412. https://doi.org/10.1371/journal.pbio.1000412).* The institutional protocol number should be included at the end of the abstract of the article.

3. **Review.** State-of-the-art reviews on specific topics within surgery. **Word and reference limits: T**ext: 7000 words, excluding abstract, references, tables, and figures; Structured abstract: 250 words; For narrative reviews an unstructured abstract is acceptable. References: 75 maximum. A maximum combined number of 7 tables & figures may be included for publication. Additional tables and figures may be included as online-only supplemental data content.
4. **Systematic Review / Meta-analysis.** Systematic, critical assessments of current literature pertaining to clinical topics, emphasizing factors such as cause, diagnosis, prognosis, therapy or prevention. All articles should be searched for and selected systematically for inclusion and critically evaluated, and the search and selection process should be described in the manuscript. The specific type of study or analysis should be described for each article or data source. Submitted meta-analyses need to comply with the PRISMA guidelines (https://prisma-statement.org/). The flow diagram should be uploaded as a figure and the checklist as supplemental material. **Word and reference limits:** Text: 5000 words, excluding abstract, references, tables, and figures; Structured abstract: 250 words; References: 75 maximum. A maximum combined number of 7 tables & figures may be included for publication. Additional tables and figures may be included as online-only supplemental data content.
5. **Case report / series.** Reports on new or very rare clinical cases, new diagnostic criteria or new therapeutic methods with proven results. Submitted case reports should comply with the CARE guidelines (https://www.care-statement.org/) and the checklist should be uploaded as a supplemental file. **Word and reference limits:** Text: 2000 words and up to 20 references; Unstructured abstract: 150 words.
6. **How I do it.** Articles describing a new surgical technique or a modification of known surgical techniques. Manuscripts should be accompanied by drawing figures of technique. **Word and reference limits:** 1000-1500 words and up to 10 references.
7. **Commentary.** Short, decisive observations and findings that generally relate to a contemporary issue, such as recent research findings, but can also include the discussion of difficulties and possible solutions in a field of research. **Word and reference limits:** 500 words and up to 5 references.
8. **Letter to the Editor.** Letters to the Editor will be considered for publication only if they are relevant to articles recently published in HJS. All letters should be received within 90 days of the published paper appearing in HJS. In addition, all letters should be clearly referred to the published article they are relevant to and should be addressed to the Editor-in-Chief. Letters should not duplicate other material published or submitted for publication and should not include unpublished data. **Word and reference limits:** 500 words and up to 5 references, 1 of which should be to the recent article, and no more than 3 authors. Letters not meeting these specifications are generally not considered for publication.
9. **Surgical History.** Articles that explore the life of a surgeon, examine the development of a new technique or technology, interrogate relationships among surgeons other health care providers, analyze the experience of patients who underwent an operation, address the hurdles minorities encountered when trying to enter the profession, assess the impact of race/gender/class in surgical history or research any other topic that relates to the history of surgery. **Word and reference limits:** Text: 3500 words, excluding abstract, references, tables, and figures; Unstructured abstract: 250 words; References: 50 maximum.
10. **Perspective.** Perspective articles present a viewpoint on a specific area of investigation. They may discuss current advances and future directions and can include original data as well as personal insights and opinions. **Word and reference limits:** Text: 3000 words, excluding abstract, references, tables, and figures; Unstructured abstract: 150 words; References: 50 maximum. A maximum combined number of 3 tables & figures may be included for publication.
11. **Brief Communication.** These manuscripts are short reports of original studies or evaluations or unique, first-time reports of clinical case series. **Word and reference limits:** Text: 1500 words, excluding abstract, references, tables, and figures; Unstructured abstract: 150 words; References: 15 maximum. A maximum combined number of 2 tables & figures may be included for publication.
12. **Surgical image.** These short articles highlight interesting surgical images (s), with a brief Introduction to the image/s and a detailed caption for each one, followed by a Comment section. **Word and reference limits:** Text: 500 words, excluding abstract, references and figures; References: 5 maximum. A maximum number of 3 figures may be included for publication.

Journal language

The official language of HJS is English. Authors whose native language is not English should review and edit their manuscripts by a native English speaker prior to submission.

Journal style

The modern trend to simplify has also influenced scientific writing. When preparing your manuscript, avoid long sentences, jargon and clichés. When tempted to use a difficult word or complex sentence, see if it can be replaced by a simpler one. Always write for the generalist, rather than the specialist. The overall essence of your manuscript should be understandable to someone educated until university level.

Abbreviations and Unit system

Since abbreviations tend to make the text difficult to read, avoid them except when essential. In the Abstract and the article itself, define each abbreviation when first used—e.g. coronary artery disease (CAD)—and thereafter use the abbreviation alone without further explanation. Avoid beginning sentences with abbreviations. All abbreviations must be expanded in titles, subtitles and captions. Use standard abbreviations, rather than words, for units and percentages (e.g. km, mm, kg, L, mL, %, etc.). This Journal uses the International System (SI) units for most measurements (eg. pmol/L). Alternative corresponding units may be included in parentheses.

Formatting

All manuscripts must be submitted in Microsoft Word. Use 12 point Times New Roman font for the entire manuscript. In addition, all manuscripts should have 2 spacing between the lines and have continuous line-numbering for the entire manuscript to facilitate the review and revision process. Use minimum formatting, restricting formatting to superscripts and subscripts and what is absolutely essential to reveal various heading levels, since most formatting will be removed before typesetting. Use true superscripts and subscripts and not "raised/lowered" characters. For symbols, use the standard symbol fonts on Windows or Macintosh. Using strange symbol

fonts may give unpredictable results in print, even if the fonts are supplied by the author. Put exactly one space between words and after any punctuation. Put one blank line between paragraphs and do not use indents to indicate new paragraphs. Ensure that the text of the entire manuscript is in uniform black font color, unless you need to indicate changes to your article made during a request for revision. Please do not insert page borders.

ARTICLE SECTIONS

Details

Papers must be typed in double space of the usual dimensions (ISO A4 210 × 297 mm), with margins of at least 3.5 cm. A separate page must be used for the title, the abstract and keywords, the main text, the acknowledgements, the references, the tables, the figures and the figure legends. Please ensure that you remove the author names and affiliation details from the Microsoft Word document of your manuscript as it will be sent out for blind peer review. In addition, ensure that any potential identifying information—such as that which might be included in an Acknowledgments/Funding/Conflict of Interest section—is uploaded as part of the Cover Letter on the HJS Editorial Manager website. This information can subsequently be included in the manuscript after an acceptance decision has been made.

Cover letter

The cover letter, from the author responsible for all correspondence regarding the manuscript, should contain a statement that the manuscript has been seen and approved by all authors. If color figures have been submitted, a statement should be included as to whether the authors are willing to meet possible costs of color reproduction.

Title page

Title: Concise and informative. Titles are often used in information-retrieval systems. Avoid abbreviations and formulae where possible. It must be brief (up to 12 words) accompanied by a running title (up to 50 characters).

Author names and affiliations: Where the family name may be ambiguous (e.g., a double name), please indicate this clearly. Present the authors' affiliation addresses (where the actual affiliations) with lower-case superscript letters immediately after the author's name and in front of the appropriate address. Provide the full postal address of each affiliation, including the country name and, if available, the email address of each author.

Corresponding author: Clearly indicate who will handle correspondence at all stages of refereeing and publication. Ensure that phone numbers (with country and area code) are provided in addition to the email address and the complete postal address. Contact details must be kept up to date by the corresponding author.

Blinded manuscript

Abstract: A concise and factual abstract is required in English. The article title should be repeated. The abstract should state briefly the purpose of the research, the principal results and major conclusions. An abstract is often presented separately from the article, so it must be able to stand alone. Also, non-standard or uncommon abbreviations should be avoided, but if essential they must be defined at their first mention in the abstract. Abstracts of original articles, systematic reviews/meta-analyses and brief communications should be structured into four paragraphs, under the following captions: Background, Material and Methods, Results, Conclusions (maximum 250 words). Editorials, commentaries and letters to the editor do not need an abstract. Reviews, "how I do it" articles, perspectives, historical articles and case reports have a narrative abstract in a single paragraph (up to 150 words). The high- quality of the English abstract would be strongly considered as a crucial requirement for publication.

Keywords: Immediately after the abstract, provide 3-5 keywords, using American spelling and avoiding general and plural terms and multiple concepts (e.g. 'and', 'of') chosen from the MeSHterms of Index Medicus.

Main text: Original papers usually contain the following chapters: Introduction, Material and Methods, Results, Discussion and Conclusion. The introduction contains the background along with the necessary references and cites the objective of the study. The study protocol must be thoroughly described in the methodology section. Details such as the mode of patient or material selection, as well as the methodology applied must be fully disclosed in order to allow the reported research to be reproduced by future investigators. In the case of research related to human beings it must be stated that the research was performed according to the principles of the Declaration of Helsinki (1975). The pharmaceutical substances used must be mentioned by their generic names. In the same chapter the data evaluated must be described and the chapter should be completed by an analysis of the statistical criteria used. In the next chapter the results should be presented fully, but briefly. Results shown in tables should not be repeated in the text. In the Discussion, the perspectives opened up by the results of the study as well as the final conclusions are discussed.The results must not be repeated in this section. A comparison with the results of other similar studies may be done. The results may, also, be related to the objectives of the study, but it is advisable to avoid arbitrary conclusions, not emerging from the results themselves. The main conclusions of the study may be presented in a short Conclusions section, which may stand alone or form a subsection of a Discussion or Results and Discussion section. Acknowledgements are addressed only to individuals who have contributed substantially to the presented work.

References

All statements which require support/evidence or cite data from previously published material should be referenced. Other literature should be referenced sequentially in their order of appearance, for example: "The Ministry of Health has prioritized eye care in its next 5 year plan (3)". Always try to use primary rather than secondary sources of data, if available. Avoid references to personal communications, unpublished data or other manuscripts which have not yet been accepted for publication. The reference number must be inserted within the text in brackets before a comma or full stop. In the article itself and the Reference section, list all the references in sequential numerical order. In the Reference section, list all authors up to a maximum of six. If there are more than six authors then write et al. after the sixth author. The Journal uses Vancouver style for references. Please adopt the exact style as shown in the examples below, including punctuation. Journal names should be abbreviated as per the Journals Database section in PubMed (http://www.ncbi.nlm.nih.gov/nlmcatalog/journals).

Journal Citation

Rose-Nussbaumer J, Prajna NV, Krishnan T, Mascarenhas J, Rajaraman R, Srinivasan M, et al. Risk factors for low vision related functioning in the Mycotic Ulcer Treatment Trial: A randomised trial comparing natamycin with voriconazole. Br J Ophthalmol 2016; 7:929–32.

Book Chapter

Brown J, Murphy KH. Adult-onset Still's disease. In: Maddison PJ, Woo P, Glass DN, Eds. Oxford Textbook of Rheumatology, 3rd ed. Oxford, UK: Medical Publication, 2010. Pp. 1127–31.

Book

Smith MD. Introduction to Gynaecology, 6th ed. New York, USA: Institutional Press, 2005. P. 15.

Report

World Health Organization. Issues in Health Services Delivery. Ge-

neva, Switzerland: World Health Organization. WHO/EIP/00l. Pp. 3–4.

Thesis

Rowe L. DNA damage-induced reactive oxygen species: A genotoxic stress response. PhD Thesis, 2012, Emory University, Georgia, USA. Pp. 315–22.

Website

Smith AD. Pregnancy after 35. From: www.marchof-dimes.com/pregnancy Accessed: Sep 2016.

Figures and tables

All tables and figures should be inserted/placed at the end of the manuscript, rather than within the main text. Provide a brief but fully self-explanatory caption and title for each figure and cite each figure in the text and number them consecutively. Number tables consecutively, give concise but self-explanatory titles to each and cite them in the text. All figures will appear in color, if necessary. Tables will be formatted to fit the standard shading/layout of the Journal. It is the author's responsibility to obtain permission for the reproduction of previously published figures or tables from other sources and the source of the original figure/table should be clearly cited underneath the reproduction. An explanation of all definitions used, as well as any other potentially non-intuitive features, should be included in the legend to the figure or table.

Photographs/Images/Scans – The quality of such figures must be high enough resolution for good print reproduction and should stand reduction. The Journal uses standard arrows/identifying symbols for figures, so additional arrows, symbols, words and other identifying/descriptive features should not be placed on the figure itself, if possible, but into the Microsoft Word document instead. After acceptance, figures should be provided to the Editorial Office in digital format (300 dpi) and in JPEG, PNG, GIF, TIFF or other image format. Sourcing figures directly from a Microsoft Word document may greatly and negatively affect their quality in print.

Drawings – All line drawings should be planned to fit the Journal's page size (12 x 18 cm). Lines should be dark enough and letters should be of professional quality in order to stand reduction. Do not use bold or all-capital lettering. Do not combine line drawings and photographs into one illustration. For best results, it is advisable to execute your drawings in a vector application such as Adobe Illustrator or CorelDraw. The Editorial Office is able to accommodate a wide range of vector and bitmap formats executed on Windows or Macintosh platforms.

Diagrams/Flow Charts – All diagrams and flowcharts should be created in Microsoft Word, if possible, and be editable so that the font/formatting of the text can be changed by the Editorial Office if necessary.

Tables and Charts – All X and Y axes must be clearly labeled. Charts and tables pasted into Microsoft Word documents in un-editable "picture" formats are not acceptable and should be provided in Microsoft Excel or a similar programme. Please ensure that no charts or graphs are displayed in three dimensions. For tables, please ensure that as few cells as possible are merged and that each column and row is clearly labeled and outlined using the border function. Within a table, do not insert multiple spaces or tabs within a single cell.

Please do not:

Supply files that are optimized for screen use (e.g., GIF, BMP, PICT, WPG); these typically have a low number of pixels and limited set of colors.
Supply files that are too low in resolution.
Submit graphics that are disproportionately large for the content.

Whilst it is accepted that authors sometimes need to manipulate images for clarity, manipulation for purposes of deception or fraud will be seen as scientific ethical abuse and will be dealt with accordingly. No specific feature within an image may be enhanced, obscured, moved, removed, or introduced. Adjustments of brightness, contrast, or color balance are acceptable if and as long as they do not obscure or eliminate any information present in the original.

Figure legends

On initial submission, each legend should be placed in the text file and be incorporated into the image file beneath the figure to assist review. Legends should provide enough information so that the figure is understandable without frequent reference to the text. However, detailed experimental methods must be described in the Materials and Methods section, not in a figure legend. A method that is unique to one of several experiments may be reported in a legend only if the discussion is very brief (one or two sentences). Define all symbols used in the figure and define all abbreviations that are not used in the text.

Acknowledgements

Collate acknowledgements in a separate section at the end of the article before the references. List here those individuals who provided assistance during the research.

Data statement

To foster transparency, we require you to state the availability of your data in your submission if your data is unavailable to access or unsuitable to post. This may also be a requirement of your funding body or institution. You will have the opportunity to provide a data statement during the submission process. The statement will appear with your published article on ScienceDirect.

Math formulae

Present simple formulae in the line of normal text where possible and use the solidus (/) instead of a horizontal line for small fractional terms, e.g., X/Y. In principle, variables are to be presented in italics. Powers of "e" are often more conveniently denoted by exp. Number consecutively any equations that have to be displayed separately from the text (if referred to explicitly in the text).

Footnotes

Footnotes should be used sparingly. Number them consecutively throughout the article, using superscript Arabic numbers. Many word processors build footnotes into the text, and this feature may be used. Should this not be the case, indicate the position of footnotes in the text and present the footnotes themselves separately at the end of the article. Do not include footnotes in the reference list.

Reprints

Photocopy reproduction of published papers is not allowed.

Supplementary material

Supplementary material such as applications, images and sound clips, can be published with your article to enhance it. Submitted supplementary items are published exactly as they are received (Excel or PowerPoint files will appear as such online). Please submit your material together with the article and supply a concise, descriptive caption for each supplementary file. If you wish to make changes to supplementary material during any stage of the process, please make sure to provide an updated file. Do not annotate any corrections on a previous version. Please switch off the 'Track Changes' option in Microsoft Office files as these will appear in the published version.