Original Article

Hell J Surg. 2025 Jul-Sep;95(3):107–113
doi: 10.59869/25071

Single-Site Laparoscopic Tenckhoff Catheter Insertion: Description of a novel two-port technique using conventional equipment

Muthukumaran Rangarajan[1], Mangalakumar Veeraswamy[2], Durairaju Arun Kumar[3]

[1]MS, FRCS (Glasg), DipMIS (France), FACS (USA), Consultant Surgeon, Doctors Hospital Health System, Nassau, Bahamas
[2]MD, MRCP, FEBS, PhD, Consultant Nephrologist, Kovai Medical Centre, Coimbatore, India
[3]MD, FRCA, Consultant Anaesthesiologist, Kovai Medical Centre, Coimbatore, India

ABSTRACT

Background: Conventional laparoscopic peritoneal dialysis catheter insertion is well established. The existing reduced-port techniques of catheter insertion described in the literature have both benefits and disadvantages. Hoping to address all the shortcomings while still maintaining reduced ports, we describe a novel technique used for the successful peritoneal catheter insertion in a series of patients using two laparoscopic ports via a single site (umbilical). **Materials and Methods:** In this prospective study, we included 41 patients with end-stage renal failure requiring renal replacement therapy via peritoneal catheter in our tertiary care hospital from 2015 – 2020. Our technique involves inserting a peritoneal catheter using two laparoscopic ports (one 5-mm and one 10-mm) inserted via two small incisions within a single site (umbilicus). **Results:** Parameters like age, sex, operative time (46 minutes; range 34 – 58), hospital stay, pain score and long-term catheter survival (75-92%) were analysed. Early complications (<30 days) rate was 7% and included peritonitis, bowel perforation, bleeding, wound infection, leakage, blockage and late complications (>30 days) were 10% and included exit-site infection, tunnel infection, cuff protrusion, outflow failure, and dialysate leaks or port-site hernias were also analysed. Follow-up was 25-72 months. We compared our outcomes with the various techniques of reduced port surgery described in the existing literature. **Conclusion:** In our method, we performed adhesiolysis wherever necessary, catheter introduction under direct vision, accurate catheter placement, catheter fixation, catheter patency testing and omentopexy. This technique was also successfully applied to redo surgeries with good outcomes. Our technique accomplished PD catheter insertion without compromising the basic principles of PD catheter placement, with added benefits of less pain and superior cosmesis.

Key words: *Laparoscopy; reduced port; single site; Tenckhoff catheter; peritoneal dialysis*

INTRODUCTION

In 1968, Henry Tenckhoff developed the indwelling peritoneal catheter, which was inserted through an open surgical technique [1]. However, it was Popovich and Moncrief in 1976 that popularised peritoneal dialysis (PD) by developing the concept of a continuous ambulatory peritoneal dialysis (CAPD) [2]. In recent times, the introduction of the percutaneous and later the laparoscopic technique was a major improvement in the insertion of PD catheters [3,4]. Even though the three main techniques for PD catheter insertion are open surgical, percutane-

Corresponding author:
Dr. Muthukumaran Rangarajan, Doctors Hospital Health System
1 Collins Avenue, Nassau, Bahamas
Tel.: +1-242-302-3257, +1-242-806-2601
e-mail: rangy68@gmail.com

Submission: 07.07.2026, Acceptance: 09.09.2026

ous Seldinger and laparoscopic techniques, the ideal technique is still debated. Over the last two decades, the laparoscopic technique has become more popular, which not only allows accurate placement of the catheter but also the ability to perform adhesiolysis, catheter fixation and omentopexy. It also provides good cosmesis, less pain and shorter hospital stay compared to the open approaches [5,6]. More recently, laparoscopic reduced port techniques of PD catheter insertion have been reported [7-11]. Herewith, we describe another novel technique of a laparoscopic two-port single-site Tenckhoff catheter placement that promises superior cosmesis and less pain without compromising surgical principles and patient safety. A brief commentary on the published literature describing various modifications of reduced port surgery for PD catheter insertion is also included.

MATERIALS AND METHODS

In this study, we included 41 patients with end-stage renal failure requiring renal replacement therapy via peritoneal catheter in our tertiary care hospital from 2015 – 2020. These patients were primarily managed by a single nephrology unit headed by a consultant. We excluded patients who were unfit for general anaesthesia or those who had abdominal hernias. All the surgeries were performed by a single surgeon with a sound knowledge of laparoscopic single site/reduced port surgeries. Initial experience in this technique was obtained from the surgeon performing procedures with the gynaecology team for benign gynaecological conditions for over 10 years. The relevant paperwork, including Ethics Committee approvals, was completed and the patients were prepared for surgery.

Surgical technique

All the patients were given staphylococci eradication via nasal mupirocin application and also underwent bowel preparation the previous night. The single-site surgical technique was explained to them and the relevant consents were signed.

The patients were placed in the supine position and endotracheal intubation/general anaesthesia was induced. Prophylactic antibiotics (IV Vancomycin + Ceftriaxone) were administered in all patients as per our protocol. Pneumoperitoneum was achieved via a Veress needle, which was inserted through a 2-mm stab incision in the umbilicus. For redo surgery in the three patients, the Veress needle was placed in the upper-left quadrant of the abdomen (Palmer's point). After creating a pneumoperitoneum of 12 mmHg, a No. 11 scalpel was used to make a 1-cm incision at the cephalic end of the umbilicus to accommodate a 10-mm trocar. Another 5-mm trocar was placed via a 5-mm incision in the caudal end of the umbilicus (Figure 1). It should be noted that there is always a 3-mm skin bridge between the two trocars to prevent gas leakage. In some cases, due to an introverted or small-sized umbilicus, the two incisions may spill out of the confines of the umbilicus by 3 – 4 mm. In this technique, the 10-mm trocar for the 30-degree laparoscope was always placed in the cephalic end of the umbilicus and the 5-mm port for instruments was placed at the caudal end of the umbilicus. For optimum utilisation using this particular technique and port position, the telescope and instrument must be moved in tandem, and never independent of each other.

The patient was now placed in a Trendelenburg position and a diagnostic laparoscopy was performed with a 10-mm 30° scope. The 5-mm trocar was used to introduce instruments to achieve adhesiolysis if necessary, catheter placement, catheter fixation and omentopexy. A double-cuffed straight-tip Tenckhoff PD catheter was then introduced through a 2-mm stab incision in the midline about 4 cm caudal to the umbilicus under direct vision. The subcutaneous cuff lay just under the skin and the peritoneal cuff was placed at the entry point of the catheter into the peritoneal cavity, which was verified with the scope. After ensuring no torsion had occurred, the tip was placed in the true pelvis. The catheter was secured to the abdominal wall by a No. 1 silk thread using a cobbler needle. The distal cuff of the PD catheter should be outside the peritoneum in the preperitoneal space or between both the rectus sheaths. A 3-mm stab incision was made in the left lateral abdominal wall, taking care to

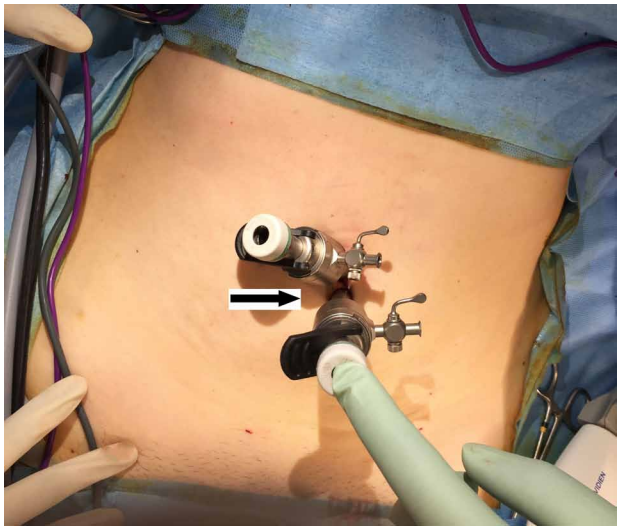

FIGURE 1. The two trocars placed within the umbilical area (arrow).

avoid damage to the inferior epigastric vessels. A blunt-tipped laparoscopic instrument was used to create the subcutaneous tunnel (Figure 2). The proximal cuff should lie in this tunnel. Next, the scope was directed to the left upper quadrant and the omentum was tethered to the anterior abdominal wall using the cobbler needle (Figure 3). Among the 41 patients, only two females required adhesiolysis because of a bowel adhesion from previous Caesarean section.

In the three redo patients with the catheter blockage:

i) the catheter was freed from the small bowel (Figure 4)
ii) the catheter was dissected out from the omentum (Figure 5)

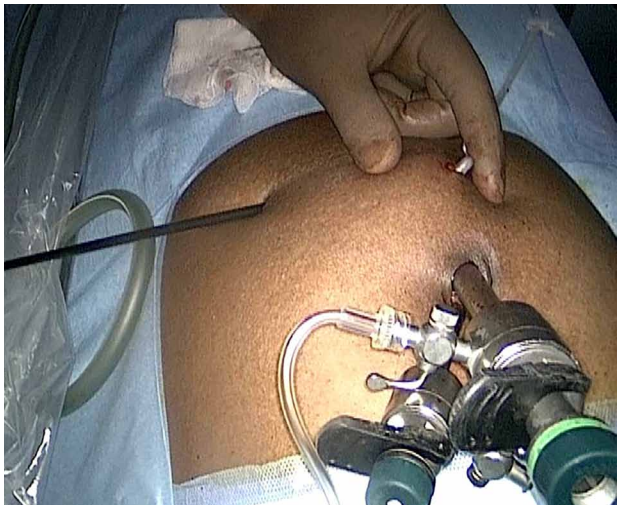

FIGURE 2. A blunt-tipped laparoscopic instrument creating a subcutaneous tunnel.

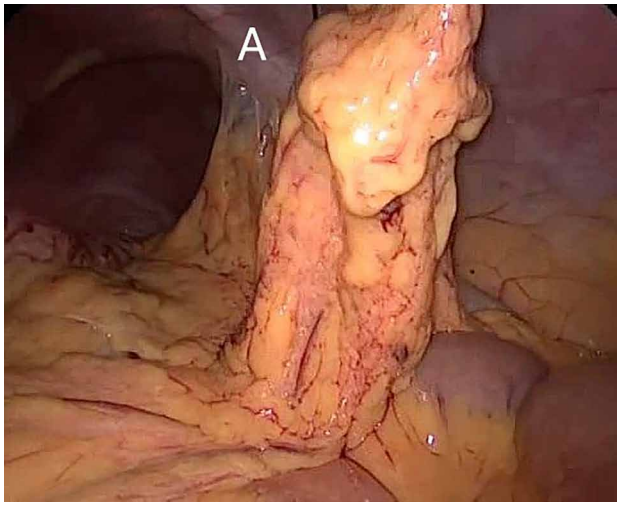

FIGURE 3. Omentum is tethered to the anterior abdominal wall (A – left costal margin), far away from the catheter tip.

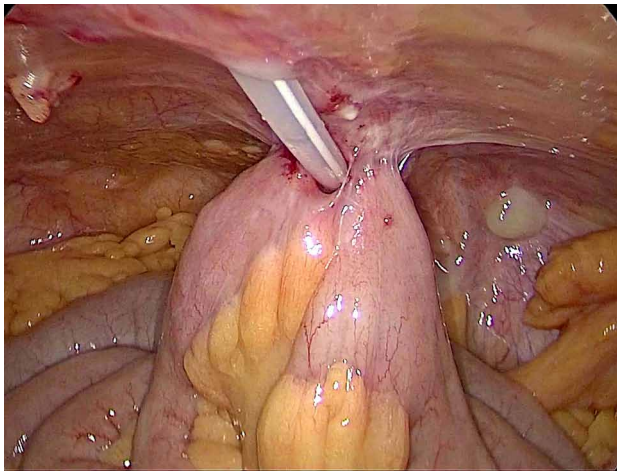

FIGURE 4. Small bowel adhesions being dissected from the catheter.

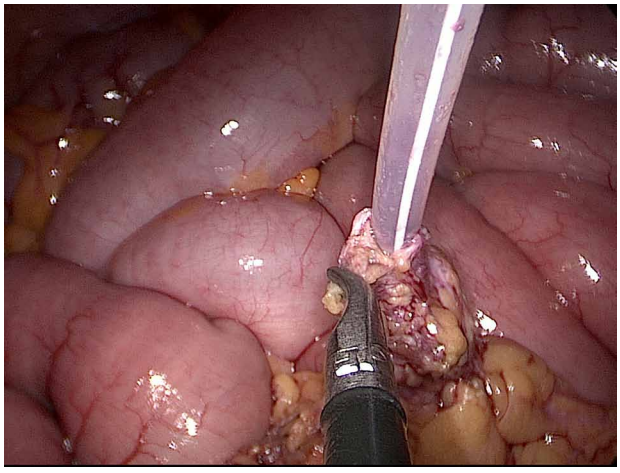

FIGURE 5. Omentum being cleared from the catheter tip.

iii) the catheter was then freed from the appendix epiploicae (Figure 6) and returned to the true pelvis.

In the one patient with catheter migration:

i) The catheter tip was relocated to the true pelvis and fixed to the abdominal wall with a No.1.0 silk.

The catheter patency was then tested with saline and the pneumoperitoneum was released, with the camera still in position to check the location of the catheter during desufflation. The trocars were removed and the rectus sheaths were closed with absorbable sutures. The two wounds were closed with skin glue (Figure 7). The application of the dialysis catheter two weeks after placement was defined as "early usage" and after two weeks as "late usage." We prescribed mild laxatives to all our patients to avoid constipation and thereby potential catheter blockage.

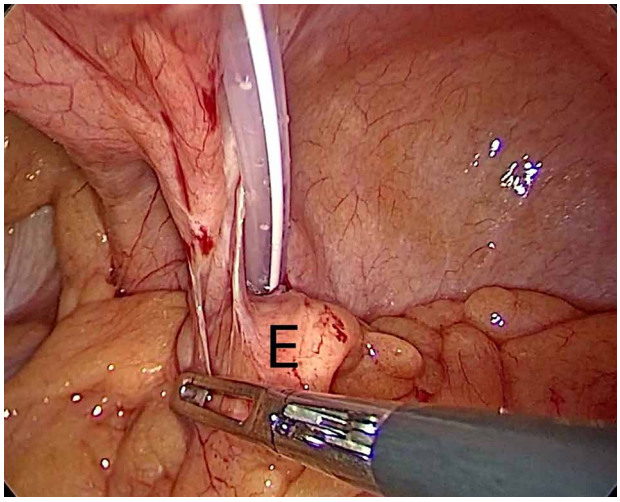

FIGURE 6. Catheter tip was freed from the appendix epiploicae (E).

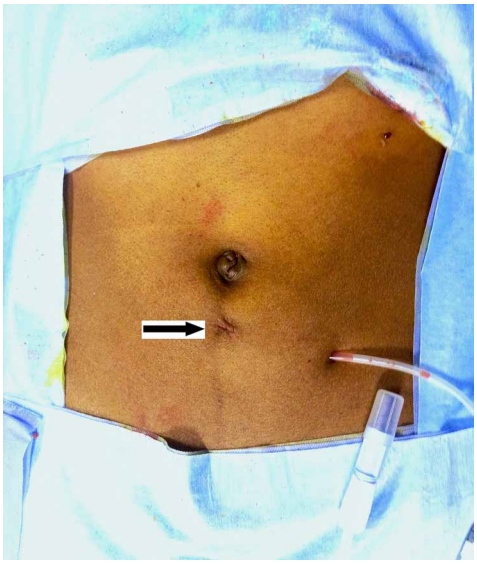

FIGURE 7. After procedure – incision sites within the umbilicus are barely visible; arrow points to the catheter tethered to the abdominal wall 2 inches inferior to the umbilicus.

RESULTS

In this prospective study, we analysed the data of the 41 patients that underwent insertion of a straight Tenckhoff peritoneal catheter from 2015 – 2020 using the novel two-port single site laparoscopic technique. We included 26 male patients (63%) and 15 female patients (37%). The average age was 56.5 years (range: 32 – 81 years) and average body mass index was 28.5 Kg/m^2 (range 23.2 – 33.5). The mean operative time was 46 minutes (range 34 – 58). There were no conversions to either the conventional multi-port or open approaches.

Pain assessment was done using **Numeric Rating Scale (NRS 11)**, where '0' indicates no pain, '5' denotes moderate pain and '10' indicates worst possible pain (Table 1). Pain was assessed during their hospital stay; one patient needed narcotics (oral hydromorphone 2.5mg thrice daily) while the others were managed with intravenous acetaminophen 4 g daily and celecoxib 400 mg twice daily. The mean follow-up period was 48.5 months (range: 25 – 72 months). Hospital stay was 24 hours in 38 patients and 48 hours in three patients. Start of dialysis for all patients after CAPD placement was two weeks, except for one female (five days) who needed an urgent start with low volume. Long-term catheter survival in our study was at 1, 2, 3, 4 and 5 years was 92%, 92%, 90%, 79% and 75%, respectively. Renal transplants were performed in 40% of patients 4-6 years after CAPD placement.

Early (<30 days) complications like peritonitis, bowel perforation, bleeding, wound infection, leakage, catheter blockage and late (>30 days) complications like exit-site infection, tunnel infection, cuff protrusion, outflow failure, and dialysate leaks or port-site hernias were analysed (Table 2). Three patients (7%) had early postoperative complications: two patients (5%) who had exit site infection, which was adequately treated with dressings and oral antibiotics for 10 days. One female patient had a dialysate leak from the exit site that was confirmed with a glucose test strip. This could be attributed to the urgent-start dialysis she underwent five days after CAPD placement. She was managed by a temporary suspension of dialysis and reducing the dialysate volume.

In our study, four patients (10%) presented with late complications (Table 2). They all required re-intervention and were performed using the same two-port single-site technique. There was one patient with a migrated catheter, the reason being the catheter was not anchored to the abdominal wall during the primary surgery. During the second procedure, the catheter tip was found to be engulfed by small bowel loops. The tip was then relocated to the true pelvis and fixed to the abdominal wall with a No. 1.0 silk. We had three patients with a blocked catheter:

TABLE 1. Numerical Rating Pain Scale.

Pain Score	0-3	4-6	7-9	10
Number of Patients (%)	31(76%)	9(22%)	1(2.4%)	0(0%)

TABLE 2. Postoperative Outcomes.

Early Complications: Number of Patients (%)	Late Complications: Number of Patients (%)
Dialysate leaks – 1 (2.4%)	Outflow failure (blocked catheter) – 3 (7%)
Exit site infection – 2 (5%)	Catheter migration – 1 (2.4%)
Peritonitis; Bowel perforation; Cuff protrusion; Blockage; Catheter migration; Bleeding – 0 (0%)	Exit-site infection; Dialysate leaks; Hernia; Catheter removal – 0 (0%)

one was due to sigmoid colon appendix epiploicae and the other two were due to omentum.

DISCUSSION

Based on the current evidence, it is safe to state that laparoscopic catheter placement is superior to the open method in terms of accurate placement, complication rate (especially peritonitis), catheter survival and pain [12-14]. Now that laparoscopy is well established, we set our sights on reduced-port PD catheter insertion, based on the experience gained with single-site surgery in other specialties. It must be appreciated that PD insertion using reduced number of ports translates into reduced port-related complications. Studies have shown that port-site complications include leakage (4-12%), abdominal wall haematoma or haemorrhage (5%) and port-site hernias (7%) [15-17]. Moreover, these complications contribute to almost 20% of the total mechanical complications that could potentially lead to catheter loss. Obviously, pain is also less with reduced-port surgery. Based on these facts, it is therefore pertinent to explore the option of a reduced-port or single-site surgery for PD insertion. The term 'reduced port' surgery denotes the utilisation of less than three ports, which is the minimum requirement for a standard laparoscopy. Serendipitously, a literature survey revealed no dearth of techniques and modifications of reduced-port laparoscopy for PD insertion since 2004. Our particular technique of PD insertion has not been previously reported.

Traditionally, the six cardinal principles of PD catheter insertion are described:

1. Adhesiolysis if necessary
2. Catheter introduction under direct vision to prevent bowel injury
3. Accurate catheter placement to prevent blockage
4. Catheter fixation to prevent migration
5. Catheter patency testing
6. Omentectomy or Omentopexy to prevent catheter blockage

Regardless of the technique of insertion, these 'six simple rules' must be adhered to. It is logical to conclude that any reduced port technique that adequately fulfils all these criteria would be ideal to emulate. We also reviewed published literature describing the various modifications of reduced-port surgery for PD catheter insertion and compared them with ours.

Harissis et al reported a one-port technique in 13 consecutive patients [18]. All their catheters were fixed in the abdominal cavity with no additional ports, but no omentopexy was described. Kao et al in their 2014 paper describe their technique of a single port PD insertion [19]. While this is certainly an ingenious approach, in our opinion, carries these drawbacks: omentopexy was not performed, the catheter tip position could not be visualised during desufflation, and redo procedures were not described – all of which were achieved using our technique.

Bıçakcı et al published an interesting paper, one of a very few comparing single port laparoscopic and open surgical access in children [20]. The catheter was not fixed in their method, though they used an optic bronchoscopy forceps to exteriorize the omentum and excised it extracorporeally. Ashegh et al reported a large series of 79 patients using a one-port laparoscopic PD catheter insertion in 2008 [21]. However, in their study the authors needed two extra ports to perform adhesiolysis. They fail to mention how omentopexy was performed with a single trocar. Yan et al describe a one-port technique but did not fix the catheter and did not perform omentopexy [22]. In our modification, even though we only use the two trocars through a single site, all the recommended steps of PD insertion can be performed with no difficulty – catheter introduction under direct vision to prevent bowel injury, adhesiolysis if necessary, accurate catheter placement to prevent blockage, catheter fixation to prevent migration and omentopexy to prevent blockage.

None of the reduced port techniques we reviewed describe their technique in redo surgeries. Our novel technique was used safely for redo procedures as well, with good outcomes. In the one patient who had the catheter trapped in the small bowel, the catheter was dislodged and replaced in the true pelvis. The patient who had his catheter blocked by the omentum was managed by disentangling and performing omentopexy. One patient whose catheter was obstructed by the appendix

epiploicae of the sigmoid colon was managed by fixing the appendix epiploicae to the lateral abdominal wall with a cobbler needle.

Ladd and Cao stressed on the importance of omentopexy in PD catheter insertion [23,24]. Omentectomy was performed in all patients in their study, though catheter survival rates were similar in both groups. We also believe omentopexy is enough to prevent complications due to catheter blocks by the omentum. In our series, omentopexy was not performed in the very first patient, who subsequently developed a catheter block. Thereafter, we started routinely adding an omentopexy for all patients resulting in zero incidence of blockage. More interestingly however, Cao et al also fix the sigmoid colon mesentery to the lateral abdominal wall to prevent it from blocking the catheter tip [24]. This was of special interest to us because we had one patient where the appendix epiploicae of the sigmoid colon obstructed the catheter outflow. This patient was treated successfully using our modified single-site technique. Ko et al also published a two-port technique, where one port is situated below the umbilicus and the other cleverly placed at the site of the PD catheter exit [25]. They performed adhesiolysis via an extra 3-mm port. However, they did not perform omentopexy or redo procedures with this technique. Even though our technique also involves two ports that are both located within the umbilicus, we could perform omentopexy and re-do procedures. It also allows the patient to have no visible scar.

Regarding the postoperative early and late complications, we compared our results with similar published reduced port techniques. We defined early and late complications using the 30-day mark, whereas other studies have used the six-week mark or six-month mark.

Pan et al reported a large study focusing on the outcomes of 263 patients that underwent a single-port laparoscopic placement [26]. Catheter occlusion was the most common early complications (<6 months) that occurred in 1.5% of patients. In our study, we had no leakage within four weeks. Late complications (> 6 months): catheter occlusion (1.9%), cuff extrusion (0.8%), catheter leakage (1.1%), catheter migration (1.1%), infection (2.3%) and hernia (1.5%). Late complications in our study were catheter block in 7% and catheter migration in 2.4% of patients. Catheter survival rate at 1, 2, 3, 4 and 5 years was 96%, 94%, 90%, 85% and 82%, respectively. Long-term catheter survival in our study was at 1, 2, 3, 4 and 5 years was 92%, 92%, 90%, 79% and 75% respectively.

Another paper by Milliken et al described a single-port laparoscopic insertion of peritoneal dialysis catheters along with partial omentectomy in children [27]. In this study, 45% catheters were used within four hours. Early complications included a minor leak that resolved within 24 h, one exit-site infection, one blockage due to a fibrin clot and one blockage after 2 weeks due to adhesions (not due to omentum). In our study, 0% of patients had blockage, 2.4% had early catheter leak and 5% had infection as early complications.

Liu et al have described a unique technique using a flexible endoscope to place and fix PD in pigs [28]. Here, a flexible endoscopic is used for extraperitoneal tunneling, which allows for minimally invasive single-incision PD catheter placement and fixation with endoscopic clips. It remains to be seen the reproducibility and cost-effectiveness of this technique, while human trials are awaited.

CONCLUSION

In conclusion, our new technique allows for 'no visible scar' surgery with minimal invasion yet accomplishing all the goals of adequate peritoneal catheter insertion. It may be effective in redo procedures as well. Our technique of two-port laparoscopic surgery via a single site for PD seems to be safe, reproducible, effective and cosmetically acceptable without compromising the relevant basic surgical principles. We hope that more surgeons will adopt this technique leading to larger studies that further validate the usefulness of this novel approach. Limitations of this study include a small, single-center, single-surgeon series, absence of a control group and possible learning curve effects. Future randomised trials comparing multiport laparoscopy versus single-site laparoscopy could be beneficial to determine a superior technique.

Approval by Ethics Committee: *Yes*

Conflict of Interest: *None declared*

Informed Consent: *Informed consent was obtained from all individual participants included*

REFERENCES

1. Tenckhoff H, Curtis FK. Experience with maintenance peritoneal dialysis in the home. Trans Am Soc Artif Intern Organs. 1970;16: 90–5.
2. Nolph KD. Remembering Robert Popovich, PhD. Perit Dial Int. 2012 Nov-Dec;32(6): 583–4.
3. Adamson AS, Kelleher JP, Snell ME, Hulme B. Laparoscopic placement of CAPD catheters: a review of one hundred procedures. Nephrol Dial Transplant. 1992;7(8):855–7.
4. Savader SJ, Geschwind JF, Lund GB, Scheel PJ. Percutaneous radiologic placement of peritoneal dialysis catheters: long-term results. J Vasc Interv Radiol. J Vasc Interv Radiol. 2000 Sep;11(8):965-70.
5. Soontrapornchai P, Simapatanapong T. Comparison of

open and laparoscopic secure placement of peritoneal dialysis catheters. Surg Endosc. 2005 Jan;19(1):137-9.
6. Cox TC, Blair LJ, Huntington CR, Prasad T, Kercher KW, Heniford BT, et al. Laparoscopic versus open peritoneal dialysis catheter placement. Surg Endosc. 2016 Mar;30(3):899-905.
7. García-Cruz E, Vera-Rivera M, Corral Molina JM, Mallafré-Sala JM, Alcaraz A. Laparoscopic placement of peritoneal dialysis catheter: description and results of a two-port technique. Nefrologia 2010;30(3):354-9.
8. Mir N. Two Port Laparoscopic Placement of Peritoneal Dialysis Catheter: Effective Technique. W J Lap Surg. 2012;5(3):146-9.
9. Losanoff JE, Basson MD, Gruber SA. One-port laparoscopic peritoneal dialysis catheter placement. Am J Surg. 2007 Aug;194(2):271-2.
10. Dalgic A, Ersoy E, Anderson ME, Lewis J, Engin A, D'Alessandro AM. A novel minimally invasive technique for insertion of peritoneal dialysis catheter. Surg Laparosc Endosc Percutan Tech. 2002 Aug;12(4):252-4.
11. Al-Hashemy AM, Seleem MI, Al-Ahmary AM, Bin-Mahfooz AA. A two-port laparoscopic placement of peritoneal dialysis catheter: A Preliminary Report. Saudi J Kidney Dis Transpl. 2004 Apr-Jun;15(2):144-8.
12. Chen Y, Shao Y, Xu J. The Survival and Complication Rates of Laparoscopic Versus Open Catheter Placement in Peritoneal Dialysis Patients: A Meta-Analysis. Surg Laparosc Endosc Percutan Tech. 2015 Oct;25(5):440-3.
13. Hagen SM, Lafranca JA, Steyerberg EW, Ijzermans JNM, Dor FJ. Laparoscopic versus open peritoneal dialysis catheter insertion: a meta-analysis. PLoS One [Internet]. 2013;8(2):e56351. Available from: https://pubmed.ncbi.nlm.nih.gov/23457554/
14. Jwo SC, Chen KS, Lee CC, Chen HY. Prospective randomized study for comparison of open surgery with laparoscopic-assisted placement of Tenckhoff peritoneal dialysis catheter–a single center experience and literature review. J Surg Res. 2010 Mar;159(1):489-96.
15. Strippoli GFM, Tong A, Johnson D, Schena FP, Craig JC. Catheter-related interventions to prevent peritonitis in peritoneal dialysis: a systematic review of randomized, controlled trials. J Am Soc Nephrol. 2004 Oct;15(10):2735-46.
16. Piraino B, Bailie GR, Bernardini J et al. ISPD Ad Hoc Advisory Committee. Peritoneal dialysis-related infections recommendations: 2005 update. Perit Dial Int. 2005 Mar-Apr;25(2):107-31.
17. Peppelenbosch A, van Kuijk WHM, Bouvy ND, van der Sande FM, Tordoir JHM. Peritoneal dialysis catheter placement technique and complications. NDT Plus. 2008 Oct;1(Suppl 4):iv23-iv28.
18. Harissis HV, Katsios CS, Koliousi EL, Ikonomou MG, Siamopoulos KC, Fatouros M, et al. A new simplified one port laparoscopic technique of peritoneal dialysis catheter placement with intra-abdominal fixation. Am J Surg. 2006 Jul;192(1):125-9.
19. Kao, CY, Chuang, JH, Lee, SY. A new simplified one-port laparoscopic technique for peritoneal dialysis catheter placement. Perit Dial Int. 2014 Jan-Feb;34(1):109–113.
20. Bıçakcı Ü, Genç G, Tander B, Günaydın M, Demirel D, Özkaya O, et al. Single port laparoscopic and open surgical accesses of chronic peritoneal dialysis in children: A single center experience over 12 years. J Minim Access Surg. 2016 Apr-Jun;12(2):162-6.
21. Ashegh H, Rezaii J, Esfandiari K, Tavakoli H, Abouzari M, Rashidi A. One-port laparoscopic technique for placement of Tenckhoff peritoneal dialysis catheters: report of 79 procedures. Perit Dial Int. 2008 Nov-Dec;28(6):622-5
22. Yan X, Zhu W, Jiang CM, Huang HF, Zhang M, Guo HQ. Clinical application of one-port laparoscopic placement of peritoneal dialysis catheters. Scand J Urol Nephrol. 2010 Nov;44(5):341-4
23. Ladd AP, Breckler FD, Novotny NM. Impact of primary omentectomy on longevity of peritoneal dialysis catheters in children. Am J Surg. 2011 Mar;201(3):401-5.
24. Cao W, Tu C, Jia T, Liu C, Zhang L, Zhao B, et al. Prophylactic laparoscopic omentopexy: a new technique for peritoneal dialysis catheter placement. Ren Fail. 2019 Mar;41(1):113–7.
25. Ko J, Ra W, Bae T, Lee T, Kim HH, Han HS. Two-port laparoscopic placement of a peritoneal dialysis catheter with abdominal wall fixation. Surg Today 2009;39(4):356–8.
26. Pan A, Poi MJ, Matos J, Jiang JS, Kfoury E, Echeverria A, et al. Long-term outcomes of single-port laparoscopic placement of peritoneal dialysis catheter. Vasc Endovascular Surg. 2016 Jul;50(5):343-8.
27. Milliken I, Fitzpatrick M, Subramaniam R. Single-port laparoscopic insertion of peritoneal dialysis catheters in children. J Pediatr Urol. 2006 Aug;2(4):308-11.
28. Liu YY, Diana M, Halvax P, Cho S, Légner A, Alzaga A, et al. Flexible endoscopic single-incision extraperitoneal implant and fixation of peritoneal dialysis catheter: proof of concept in the porcine model. Surg Endosc. 2015 Aug;29(8):2402-6.