Review

Hell J Surg. 2025 Jul-Sep;95(3):114–126
doi: 10.59869/25072

Indocyanine Green Fluorescence Imaging in Colorectal Surgery: Applications, Limitations, and Future Perspectives

Elissavet Anestiadou, Efstathios Kotidis, Orestis Ioannidis, Angeliki Cheva, Christiana Chatzianestiadou, Savvas Symeonidis, Stefanos Bitsianis, Thomai Gamali, Manousos-George-Pramateftakis, Ioannis Mantzoros, Vasileios Foutsitzis, Nikolaos Ouzounidis, Stamatios Angelopoulos

Fourth Department of Surgery, School of Medicine, Faculty of Health Sciences, Aristotle University of Thessaloniki, "G. Papanikolaou" General Hospital, Thessaloniki, Greece

ABSTRACT

Background: Indocyanine green (ICG) fluorescence imaging provides real-time perfusion assessment and anatomical guidance during colorectal surgery. Its most established application is anastomotic perfusion assessment, although its effect on anastomotic leakage remains inconsistent across randomised trials. **Aims:** To review the clinical applications, technical limitations, and future perspectives of ICG fluorescence imaging in colorectal surgery, with particular emphasis on randomised evidence concerning anastomotic leakage. **Methods:** A focused PubMed/MEDLINE search identified English-language publications available through July 2026. Reference lists were also examined. Priority was given to randomised trials, prospective studies, systematic reviews, and publications addressing technical and clinical applications. **Results:** ICG fluorescence imaging supports assessment of bowel and reconstructive-flap perfusion, ureteral visualisation, lymphatic mapping, lesion localisation, and detection of selected metastatic deposits. Randomised trials show mixed effects on anastomotic leakage, with potential benefit varying according to surgical setting and anastomotic location. Major limitations include subjective interpretation, heterogeneous administration and imaging protocols, device-dependent signals, and the absence of validated quantitative thresholds. **Conclusion:** ICG fluorescence imaging is a useful adjunct in colorectal surgery, but satisfactory fluorescence alone does not establish anastomotic safety or exclude the need for a diverting stoma in selected patients. Standardised protocols, quantitative measurements, and indication-specific validation are needed to improve clinical decision-making.

Key words: *Indocyanine green; fluorescence imaging; colorectal surgery; anastomotic leak; image-guided surgery*

Corresponding author:
Elissavet Anestiadou
Fourth Department of Surgery, School of Medicine,
Faculty of Health Sciences, Aristotle University of Thessaloniki
"G. Papanikolaou" General Hospital
Exochi, 57010 Thessaloniki, Greece
Tel.: +30 698 048 1017, e-mail: elissavetxatz@gmail.com
ORCID: 0000-0001-5650-7319

Submission: 28.07.2026, Acceptance: 15.10.2026

INTRODUCTION

Minimally invasive colorectal surgery has improved postoperative recovery and perioperative outcomes while progressively reducing the surgeon's reliance on direct palpation and unrestricted visual exposure of the surgical field. This transition has increased the need for technologies capable of providing physiological and anatomical information that cannot be obtained reliably under white-

light imaging alone [1]. Near-infrared fluorescence imaging with indocyanine green (ICG) addresses part of this need by offering real-time visualisation of tissue perfusion, lymphatic drainage, selected anatomical structures, and tumour-associated fluorescence without exposure to ionizing radiation [1,2].

Colorectal cancer screening contributes to cancer prevention through the detection and removal of precancerous lesions and facilitates diagnosis at an earlier stage. Healthcare professionals have an important role in identifying eligible individuals, explaining available screening options, and ensuring appropriate follow-up, including colonoscopy after a positive stool-based test [3]. Screening and intraoperative fluorescence imaging address different stages of the colorectal care pathway: screening supports prevention and early diagnosis, whereas ICG provides guidance during surgical treatment.

The most established application in colorectal surgery is fluorescence angiography for assessment of bowel perfusion before and after anastomosis. Anastomotic leakage remains one of the most consequential complications of colorectal resection, with an important effect on reoperation, permanent stoma formation, length of stay, quality of life, oncological outcome, and healthcare costs [4,5]. Perfusion is a strong determinant of anastomotic healing, and also, one of the few determinants that can be modified intraoperatively. Previous perfusion evaluation measures, including conventional assessment based on bowel colour, pulsatile mesenteric flow, marginal arterial bleeding, and the surgeon's overall impression, are inherently subjective and have limited predictive accuracy [6].

ICG is a water-soluble tricarbocyanine dye that binds with plasma proteins after intravenous administration and emits fluorescence in the near-infrared spectrum. Its short plasma half-life allows for repeated administration intraoperatively, while near-infrared light penetrates several millimeters into tissue and enables fluorescence visualisation through a limited layer of fat or connective tissue [1,7]. Such properties have also extended the use of indocyanine green to other indications such as identification of the ureter following intraureteral injection, lymphatic mapping, sentinel-node research, endoscopic localisation of colorectal lesions, detection of selected peritoneal or hepatic deposits, and the light-guided dissection technique.

Early observational studies and pooled analyses suggested a substantial reduction in anastomotic leakage after ICG fluorescence angiography [8-13]. However, recent randomised trials have reported less uniform results [14-19]. This discrepancy has shifted the clinical interest from whether ICG fluorescence can adequately estimate perfusion to when its application alters surgical decisions and leads to clinically important outcomes. This narrative review will explore the present application of ICG fluorescence imaging in the field of colorectal surgery, with particular focus on understanding the latest randomised data, technical limitations, and needs for standardisation and quantification. The principal clinical applications of ICG fluorescence imaging in colorectal surgery are summarised in Table 1. The routes and timing of ICG administration for the principal applications are summarised in Figure 1.

LITERATURE SEARCH STRATEGY

A focused literature search was performed in PubMed/MEDLINE for English-language publications available through July 2026. Search terms included combinations of "indocyanine green," "near-infrared fluorescence," "fluorescence angiography," "colorectal surgery," "anastomotic leakage," "bowel perfusion," "ureter," "lymphatic mapping," "sentinel lymph node," "tumour localisation," "peritoneal metastases," and "liver metastases." Reference lists of relevant reviews and major clinical studies were examined to identify additional publications, according to the snowball referencing method. Priority was given to randomised trials, prospective studies, systematic reviews, consensus-oriented publications, and original studies that described a technical or clinical application. Because the purpose was a broad clinical synthesis rather than estimation of a pooled treatment effect, narrative study selection and interpretation were performed.

COMPLICATIONS AFTER COLORECTAL SURGERY

Anastomotic Leakage

Anastomotic leakage (AL) represents failure of wall continuity at the site of a colorectal anastomosis, allowing communication between the intra- and extraluminal compartments. The International Study Group of Rectal Cancer proposed a clinically useful grading system: grade A leakage requires no active therapeutic intervention, grade B requires intervention without relaparotomy, and grade C requires reoperation [20]. Incidence is reported to be influenced by the level of the anastomosis, the definitions employed, and the level of postoperative surveillance; the lowest colorectal and coloanal anastomoses have the highest risk.

The clinical presentation ranges from an asymptomatic radiological finding to pelvic sepsis, diffuse peritonitis, multiorgan failure, and death. Diagnosis may occur after discharge, thus, studies confining the study period to the index admission can underestimate the true incidence [21]. Management depends on severity, anastomosis

TABLE 1. Principal applications of indocyanine green fluorescence imaging in colorectal surgery.

Application	Route/timing	Intended information	Main supporting evidence	Current limitation
Anastomotic perfusion	Intravenous; intraoperative	Arterial inflow and regional bowel enhancement	Multiple randomized trials and meta-analyses; benefit varies by surgical setting [12-19,36]	Subjective interpretation; no universal threshold
Pedicled omentum and reconstructive flaps	Intravenous; after mobilisation and before inset	Distal pedicle or flap enhancement	Small comparative observational studies and feasibility series [37,38]	Small, predominantly non-randomized series
Ileal pouch perfusion	Intravenous; before and after pouch construction or vascular ligation	Effect of lengthening maneuvers on pouch perfusion	Small observational and feasibility studies [39]	No validated time or intensity threshold
Ureteral visualisation	Retrograde intraureteral instillation	Repeated visualisation of ureteral course	Predominantly feasibility studies and observational series [41,42]	Requires cystoscopy; limited comparative outcome data
Lymphatic mapping	Submucosal or peritumoral injection	Lymphatic channels and fluorescent nodes	Feasibility and diagnostic-accuracy studies; systematic reviews [43-47]	Variable sensitivity; cannot replace standard lymphadenectomy
Lesion localisation	Endoscopic submucosal injection before surgery	Localisation of small/non-palpable lesions	Observational studies and technical series [48-50]	Time-dependent loss and injection-related spillage
Peritoneal metastasis detection	Intravenous, protocol-dependent	Additional superficial suspicious deposits	Small pilot and feasibility studies [51,52]	Non-specific uptake and limited penetration
Liver metastasis detection	Intravenous, usually preoperative	Superficial lesions and fluorescent tumour rim	Observational diagnostic studies and feasibility series [53-55]	Limited depth; background liver fluorescence
Transanal dissection guidance	Peritumoral or tissue-plane injection	Orientation and dissection-plane support	Technical reports and video descriptions [56]	Mainly technical evidence; operator-dependent

Note: Evidence categories describe the predominant study designs supporting each application and do not represent a formal GRADE assessment. The availability of randomised evidence does not imply uniform clinical benefit, and technical feasibility alone does not establish improved patient outcomes.

site, degree of contamination, and presence of a stoma. Antibiotics and image-guided drainage are generally adequate for a localised leak and collection, whereas generalised peritonitis or uncontrolled sepsis typically requires relaparotomy for source control.

Numerous causes have been associated with AL. Patient-related factors include malnutrition, obesity, smoking, diabetes, vascular disease, immunosuppression, and impaired functional reserve. Disease- and treatment-related factors include obstruction, sepsis, prior radiotherapy, advanced malignancy, and emergency surgery. Operative parameters include tension and inadequate perfusion at the anastomotic site, technical failure, multiple staple firings, blood loss, prolonged operating time, and a very low anastomosis [22]. No intraoperative imaging modality will be able to circumvent these interactions. In this regard, fluorescence angiography ought to be used as a perfusion-based risk assessment technique rather than an all-encompassing test of anastomotic integrity.

Anastomotic Bleeding

Postoperative anastomotic bleeding is often minor and self-limited, but persistent or substantial bleeding may require resuscitation and endoscopic treatment. Operative intervention is reserved for uncontrolled bleeding or cases unsuitable for endoscopic management; the approach depends on bleeding severity, haemodynamic status, and persistence [23,24]. ICG fluorescence assesses perfusion rather than haemostasis, and satisfactory enhancement does not exclude staple-line bleeding.

Anastomotic Stricture

Benign anastomotic stricture may develop following ischaemia, leakage, or pelvic inflammation. Endoscopic balloon dilatation is generally the initial treatment, with alternative endoscopic techniques or surgery considered for refractory cases [25]. Evidence that intraoperative ICG perfusion assessment prevents subsequent stricture remains limited.

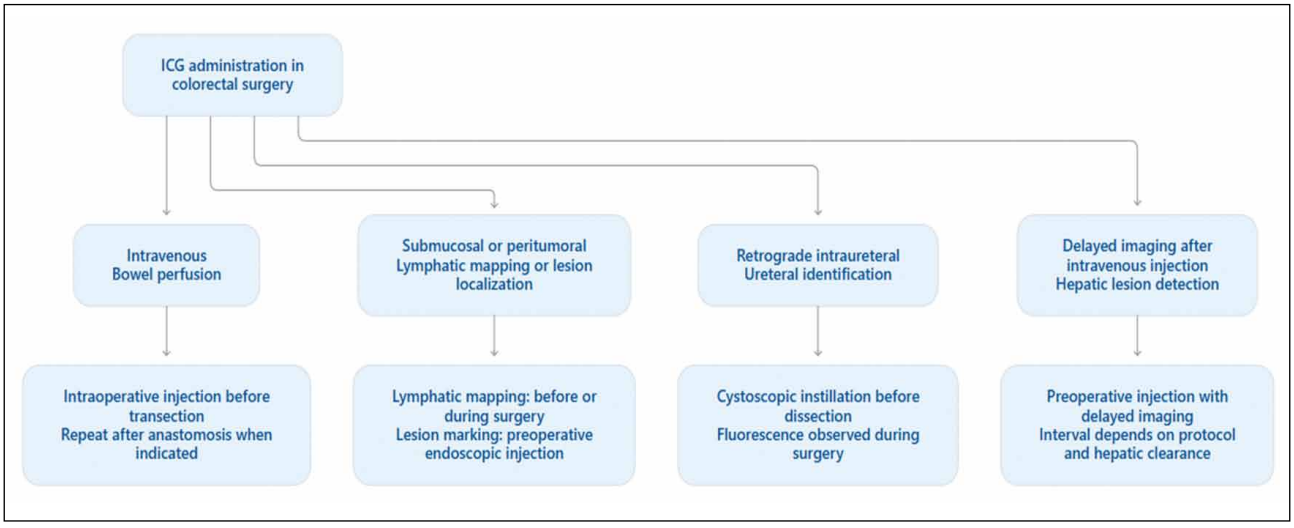

FIGURE 1. Routes and timing of indocyanine green administration for major colorectal applications. Intravenous ICG permits intraoperative assessment of bowel perfusion before transection and, when indicated, after anastomosis formation. Submucosal or peritumoral injection is used for lymphatic mapping or endoscopic lesion marking, with timing determined by the intended application. Retrograde intraureteral instillation enables ureteral visualisation during dissection. Hepatic lesion imaging uses preoperative intravenous administration followed by delayed intraoperative imaging to allow clearance from normal liver tissue. Dose, injection-to-imaging interval, and repeat administration vary between protocols; this schematic summarizes general approaches rather than a standardized regimen [1,2,42-45,48-50,53-55].

Surgical Site Infection

Surgical site infection (SSI) is among the most frequent complications after colorectal surgery and includes superficial incisional, deep incisional, and organ-space infections. It causes pain and wound-related morbidity, increases healthcare costs, and is associated with prolonged hospitalisation and readmission. Severe infections, particularly organ-space infections, may progress to sepsis and death [26]. In a prospective single-centre study of 133 patients undergoing elective colorectal cancer surgery, SSI occurred in 21.8% of patients. Higher rates were observed among older patients and those with obesity, diabetes, higher ASA class, or chronic steroid use [27].

Anastomotic leakage may cause intra-abdominal or pelvic infection, although organ-space SSI can also occur without anastomotic failure. Prevention requires a multimodal approach, including appropriate antimicrobial prophylaxis, skin preparation, maintenance of normothermia, glycaemic control, and combined mechanical bowel preparation and oral antibiotics for elective colorectal resection [26]. ICG fluorescence angiography provides information about bowel perfusion but does not assess bacterial contamination or mechanical anastomotic integrity. Satisfactory fluorescence therefore cannot exclude subsequent leakage or infection [1].

Butyrylcholinesterase (BChE), a liver-synthesised enzyme influenced by inflammation, nutritional status, and hepatic function, has been investigated as a potential marker of postoperative infectious complications. In a prospective single-center study of 402 patients undergoing colorectal surgery, lower BChE levels on postoperative days one and three were independently associated with SSI, but not with sepsis [28]. These findings suggest a possible role in postoperative risk assessment, although external validation and clinically useful thresholds are still needed. BChE remains an investigational adjunct to clinical assessment rather than an established predictor of anastomotic leakage.

Pathophysiology of Anastomotic Leakage

The process of anastomotic healing consists of a series of inflammatory, proliferative and remodelling phases. In the early days after surgery, collagen degradation surpasses collagen synthesis, while the structural strength of the anastomosis mainly relies on sutures or staples. Moreover, local hypoxia can interfere with the bacterial killing ability of oxidative mechanisms, the function of fibroblasts, angiogenesis, and collagen maturation, resulting in delayed tissue repair and increased susceptibility to infection [22,29].

Perfusion should not be regarded as a binary phenomenon. A bowel segment may receive sufficient arterial inflow to appear macroscopically viable while still exhibiting impaired microvascular distribution or venous drainage.

Systemic hypotension, vasopressor exposure, hypothermia, anaemia, tissue oedema, mesenteric traction, and excessive skeletonisation may further influence both the observed fluorescence pattern and the biological capacity for healing [6,22]. Nevertheless, perfusion represents only one component of anastomotic integrity. Mechanical tension, technical defects, distal obstruction, and local contamination remain equally important contributors to leakage. Contemporary understanding also recognises the interaction between local microbial activity, the inflammatory response, and patient-related susceptibility [30]. These overlapping mechanisms suggest that an apparently satisfactory fluorescence assessment cannot completely exclude subsequent anastomotic leakage [1,6,22].

ASSESSMENT OF COLORECTAL ANASTOMOTIC PERFUSION

The conventional assessment of bowel viability is based on a composite of serosal colour, peristalsis, bleeding from the transection margin, palpable or visible arterial pulsation, and overall surgeon impression. These findings are easily accessible but are influenced by ambient light, hypotension, vasoconstriction, mesenteric fat, pneumoperitoneum, and surgeon experience. Surgeons have shown variable performance when attempting to predict leakage based on clinical assessment alone [6].

A series of adjuncts have been proposed to assess colonic perfusion intraoperatively. Doppler ultrasonography assesses flow in larger vessels but provides limited information about distributed tissue perfusion. Laser Doppler flowmetry and laser speckle contrast imaging can characterise microvascular flow but may be sensitive to motion and distance. Tissue oximetry, visible-light spectroscopy, and hyperspectral imaging provide physiological information without necessarily requiring an injected fluorophore, although equipment availability and interpretation are still obstacles [31-33]. In addition, fluorescein with UV light has largely been superseded by ICG for visualisation of the biliary tree, as near-infrared visualisation has superior tissue penetration and is more readily adapted to current laparoscopic and robotic platforms [7,31,32].

ICG fluorescence angiography provides a practical compromise between physiological information and operative usability. The technique is rapid, repeatable, and produces an intuitive image of the distribution of dye. Its main limitation is that routine interpretation remains qualitative [1,34,35]. The fluorescence intensity is a function of not only perfusion but also of ICG dose, injection rate, cardiac output, distance and angle of the laparoscope, illumination, tissue thickness, system gain, and the time interval from injection. Therefore, a strongly visualised signal is not an absolute or device-independent measure of perfusion [1,34].

BASIC PRINCIPLES OF FLUORESCENCE IMAGING

Indocyanine Green

For decades, ICG has been used clinically in the evaluation of hepatic function, cardiac output measurement, and ophthalmic angiography. After intravenous administration, it binds rapidly to plasma proteins, remains predominantly in the intravascular space, and is cleared by the liver into bile without relevant renal excretion [7]. Its absorption and emission maxima are in the near-infrared range, approximately 780 and 820 nm, respectively. Tissue autofluorescence is relatively low in this spectrum, providing a favourable signal-to-background ratio.

The reported intravenous dose for assessment of bowel perfusion varies considerably in the literature. Fixed doses of 2.5-10 mg and weight-based regimens are both reported, with many protocols assessing fluorescence before resection, after construction of the anastomosis, or at both time points. Repeated ICG administration is allowed because of rapid plasma clearance, although residual background fluorescence and cumulative dose should be considered. ICG is generally well tolerated, but severe hypersensitivity reactions, including anaphylaxis, have been rarely reported and require immediate treatment. There is a need to check for any prior reaction to ICG or its derivatives, and to administer it with the anaesthetic team ready for any resuscitation effort [1,7,34].

Technical Equipment

A fluorescence imaging system requires an excitation light source, an optical filter that separates emitted fluorescence from reflected excitation light, a camera sensitive to near-infrared wavelengths, and a processor that displays the signal. Synchronous laparoscopic and robotic platforms permit switching between white-light, near-infrared, and overlay modes, while open systems are also available [1,7]. Changes in camera distance and angle will greatly affect intensity measurement. Quantitative procedures need to clearly state the type of system, type of imaging, distance, field stability, timing, and systemic factors involved. Without standardisation, thresholds obtained from one system are not transferrable to other systems [34].

Basic Principles of Fluorescence

When a fluorophore absorbs light at an appropriate wavelength, electrons move to a higher-energy state. As they return to baseline, energy is emitted as light of a

longer wavelength. The difference between excitation and emission wavelengths permits optical filtering and selective display of fluorescence. Signal intensity depends on fluorophore concentration, illumination, tissue absorption and scattering, detector sensitivity, and the geometry of image acquisition [1,7].

The near-infrared radiation passes through the tissue more effectively than visible light; however, it remains a surface-based method, and intraoperative factors such as heavy mesenteric fat, blood, tissue swelling, as well as an additional tissue layer may cause signal attenuation. It should be noted that the fluorescence imaging does not create images of the actual oxygenation or metabolism of cells but shows the pattern of blood containing ICG [1,7,34].

Principles of Fluorescence Angiography

Following intravenous administration, ICG appears first in arterial structures and subsequently within the capillary and venous phases. In bowel assessment, the surgeon observes the time to fluorescence, the direction and uniformity of enhancement, the position of the perfusion boundary, and the relationship of this boundary to the planned transection line. A poorly perfused segment may show delayed, weak, patchy, or absent enhancement, so the imaging sequence should be obtained before dividing a potentially questionable segment whenever possible [1,34]. After anastomosis, administration of a second dose can facilitate evaluation of the completed anastomosis, although interpretation may be complicated by background fluorescence from the first dose. If the fluorescence boundary lies proximal to the proposed transection, further resection to clearly perfused tissue can be considered. This decision must also account for tension, mesenteric reach, oncological margins, and the feasibility of reconstruction [1,34].

CLINICAL APPLICATIONS OF INDOCYANINE GREEN IN COLORECTAL SURGERY

Assessment of Anastomotic Perfusion

Initial clinical series demonstrated the feasibility of ICG fluorescence angiography and reported changes in the planned transection line in a meaningful minority of procedures [8-10]. The multicentee PILLAR II study reported a low leakage rate after left-sided colorectal resection and helped establish the technique in minimally invasive practice [11]. Subsequent observational studies and meta-analyses generally suggested lower AL rates with ICG fluorescence guidance, particularly in left-sided and rectal resections.

In contrast, the results obtained from randomised trials are inconsistent. In a multicentre study involving 240 participants, De Nardi et al. indicated that although there was alteration of resection levels by ICG injection in some of the participants, it did not bring about any statistically significant decrease in AL [14]. In addition, the single-center FLAG trial reported an overall effect that was reflected mainly in lower anastomoses [15]. The multicentre PILLAR III trial randomised 347 patients undergoing low anterior resection with an anastomosis within 10 cm of the anal verge. AL rates were similar with ICG and conventional assessment (9.0% versus 9.6%; P = 0.37). However, the trial was terminated early because of slow recruitment and did not reach its planned sample size, limiting the interpretation of its neutral findings [36]. Moreover, the EssentiAL trial, involving minimally invasive rectal cancer surgery, reported a reduction in AL from 11.8% in controls to 7.6% in the ICG group, representing an absolute difference of 4.2 percentage points [16]. Conversely, two large trials subsequently challenged routine, non-selective use. The phase III AVOID trial included 931 minimally invasive colorectal resections and found no significant reduction in clinically significant AL overall [17]. The ICG-COLORAL trial included 1,136 patients undergoing laparoscopic colorectal resection while excluding low anterior resection. AL occurred in 5.8% of the fluorescence group and 7.9% of the control group, with the difference not reaching statistical significance. A larger numerical effect was observed in left-sided procedures, whereas right-sided operations showed little difference [18]. In the European IntAct trial including rectal resections for oncological purposes, clinical AL occurred in approximately 10% of the ICG group and 15% of controls, but the primary comparison was not statistically significant and the observed effect appeared greater for less severe leaks than for leaks requiring major reintervention [19]. In conclusion, these studies do not imply the inefficacy of fluorescence visualisation. On the contrary, they demonstrate that while the physiological data provided by ICG are valuable, their influence does not result in the same degree of benefit in all cases of colorectal surgery. The risk of leakage is initially lower after most of the right-sided operations, providing little space for a visualising procedure to make an observable difference. The benefit is more likely to be achieved in those situations where the blood flow is uncertain and the consequences of its deficiency are serious, as in the case of low pelvic or selected left-sided anastomoses. Randomised trials still provide data on the relative decrease in AL [12,13].

An important interpretive challenge is the "change-of-plan" group, which includes intrinsically higher-risk patients whose transection line is revised because ICG fluorescence appears inadequate. AL within this sub-

group should not be interpreted as evidence that revision caused harm or that fluorescence failed; the counterfactual outcome without revision is unknown. Conversely, a low overall AL rate after fluorescence cannot prove causality in an uncontrolled cohort.

At present, ICG fluorescence angiography should complement and not replace intraoperative assessment of anastomosic tension, technical completeness, air-leak testing when appropriate, and the selective use of fecal diversion. Routine use is reasonable where equipment and expertise are available, but the strongest clinical rationale is for higher-risk left-sided and rectal reconstructions or when conventional assessment is uncertain. Quantitative outcomes of these randomised trials are summarised in Table 2; differences in surgical populations and leakage definitions should be considered when comparing their findings.

Additional Perfusion Applications

The same setting of near-infrared light can be utilised for different applications during colorectal procedures. The suggested approach is based on the pharmacokinetics of ICG, depending on the way it is administered. Intravenous administration of ICG corresponds to the blood and hepatobiliary transport, submucosa or tumour injection allows for its local accumulation and lymph transport, and intraureteral administration enables visualization of the ureteral cavity. It should be mentioned that these approaches are not interchangeable in technical terms and require certain protocols and interpretations. Garoufalia and Wexner also provide information about other perfusion-related applications of clinical importance besides traditional anastomosis evaluation [2]. During pedicled omentoplasty for chronic pelvic sepsis, fluorescence can identify distal omental segments that appear viable under white light but present compromised flow after mobilisation. In a comparative cohort, fluorescence-guided omentoplasty was associated with a lower rate of pelviperineal non-healing than conventional assessment (22% versus 42%), although the non-randomised design prevents a causal conclusion [37]. Furthermore, ICG fluorescence has also been investigated during gracilis muscle interposition and rectal advancement-flap procedures for complex perineal fistulas. In these procedures, viability of the distal flap is central to healing. Software-assisted analysis of gracilis perfusion has generated candidate objective indicators,

TABLE 2. Quantitative results of randomized trials evaluating ICG fluorescence angiography for prevention of anastomotic leakage.

Study	Surgical setting	Study population	AL with ICG	AL in controls	Reported effect estimate (95% CI)	P value
De Nardi et al., 2020 [14]	Laparoscopic left-sided colon and rectal resection	240 analysed	6/118 (5.1%)	11/122 (9.0%)	Not reported in the abstract	0.20
FLAG, 2020 [15]	Stapled colorectal anastomoses	377 analysed	17/187 (9.1%)	31/190 (16.3%)	Not reported in the abstract	0.04
PILLAR III, 2021 [36]	Low anterior resection with anastomosis within 10 cm of the anal verge	347 randomised: 178 ICG; 169 control	9.0%	9.6%	Adjusted OR 0.845 (0.375–1.905)	0.37 for group comparison; 0.34 for adjusted analysis
EssentiAL, 2023 [16]	Minimally invasive rectal cancer surgery	839 analysed	32/422 (7.6%)	49/417 (11.8%)	RR 0.645 (0.422–0.987)	0.041
AVOID, 2024 [17]	Minimally invasive colorectal surgery	931 analyzed	32/463 (6.9%)	42/468 (9.0%)	RR 0.77 (0.50–1.20)	0.24
ICG-COLORAL, 2025 [18]	Laparoscopic colorectal resection, excluding low anterior resection	1,136 analysed	33/567 (5.8%)	45/569 (7.9%)	OR 0.73 (0.48–1.13)	0.16
IntAct, 2025 [19]	Rectal cancer surgery	698 analysed; 766 randomised	36/343 (10.5%)	54/355 (15.2%)	Adjusted OR 0.667 (0.419–1.060)	0.087

AL, anastomotic leakage; ICG, indocyanine green; RR, relative risk; OR, odds ratio; CI, confidence interval. FLAG and EssentiAL report all-grade leakage, whereas AVOID and IntAct report clinically relevant leakage (grades B–C) within 90 days. Population sizes and effect estimates follow the respective study reports. PILLAR III was terminated early because of slow recruitment and did not achieve its planned sample size. Differences in surgical populations, leakage definitions, follow-up, and statistical analyses limit direct comparisons. Event counts are included where verified; PILLAR III rates are presented as reported.

while a small advancement-flap series reported that fluorescence findings frequently prompted revision of the proposed flap [2,38]. However, one should acknowledge that these findings are hypothesis-generating because the cohorts are small and lack controls.

Evaluation of ileal pouch-anal anastomosis (IPAA) is yet another area where perfusion and reach are in direct competition. The techniques employed during this procedure could involve the disruption of vascular arcades, thereby maintaining reach while risking the loss of inflow or venous return. It is possible to perform ICG fluorescence angiography both preoperatively and postoperatively in patients undergoing IPAA creation and vascular disruption. It was reported that the median time to onset of pouch fluorescence was 20 seconds pre-operatively and 25 seconds postoperatively; the latter showed delayed enhancement [39]. Collectively, these applications support a broader principle: fluorescence may be most useful when tissue has been mobilised on a pedicle and conventional inspection cannot reliably assess the distal microcirculation.

Ureteral Visualisation

Iatrogenic ureteral injury is an uncommon but serious complication in colorectal surgery. Risk increases in reoperative pelvic surgery, locally advanced malignancy, inflammatory disease, prior radiotherapy, obesity, and distorted anatomy. To limit this risk, preoperative placement of conventional prophylactic ureteral stents may assist identification by palpation or visualisation but does not consistently prevent injury and can add procedural time and urinary complications [40].

Because intravenously administered ICG is not excreted by the kidneys, ureteral fluorescence generally requires cystoscopy and retrograde intraureteral instillation. Small series have shown prolonged and clear visualisation during complex robotic colorectal operations [41,42]. Fluorescence with ICG enables recurrent identification without persistent dissection of the ureters, but the method still necessitates knowledge of anatomy. Cystoscopy requirements, risks associated with possible instrumentation, inconsistent application of the procedure, and lack of comparative studies confirming lower injury rates hinder regular use of ICG to identify ureters because renally excreted fluorophores offer a more efficient solution.

Lymphatic Mapping and Sentinel Lymph-Node Detection

Submucosal or peritumoral ICG injection can delineate lymphatic drainage and fluorescent nodes. The technique has been used to map drainage patterns, identify unexpected lymphatic basins, and guide the extent of mesocolic or lateral pelvic lymph-node dissection [43-45]. In colon cancer, fluorescence may reveal nodes outside the expected field basin and can assist ex vivo identification of small nodes in the specimen.

The sentinel-node concept is more difficult in colorectal cancer than in breast cancer or melanoma. Complex and tumour-altered lymphatic drainage, skip metastases, injection technique, and limited tissue penetration can reduce fluorescence accuracy. A meta-analysis reported encouraging sensitivity for node mapping but insufficient reliability to omit standard oncological lymphadenectomy [46]. More recent studies continue to emphasise methodological heterogeneity and limited evidence for oncological benefit [47]. Therefore, ICG lymphography may currently serve as an adjunct for navigation and research, not a replacement for complete mesocolic or total mesorectal excision according to oncological principles.

Endoscopic Marking of Colorectal Lesions

Accurate localisation of small or non-palpable lesions is essential during minimally invasive surgery. Conventional carbon-based tattooing is durable but may cause inflammatory staining, dye spillage, or difficulty distinguishing the exact operative target. To address these limitations, ICG can be injected endoscopically into the submucosa and visualised intraoperatively with near-infrared imaging [48,49].

The principal limitation of this technique is time-dependent signal loss. ICG marking is best suited to surgery performed within a defined interval after colonoscopy and marking, although reported visibility varies with concentration and injection technique. Recent clinical experience supports feasibility, including combination with lymphatic mapping [50]. Standardised injection in all quadrants of the lesion, avoidance of intraperitoneal spillage, and documentation of the relationship between the tattoo and the lesion remain necessary.

Detection of Peritoneal Metastases

After intravenous administration, ICG may accumulate in or around some tumour deposits through abnormal vascular permeability and impaired clearance. Pilot studies in colorectal peritoneal carcinomatosis demonstrated that near-infrared inspection can reveal lesions not readily visible under white light [51,52]. This particular use is most important during staging or debulking surgery when small deposits could influence the peritoneal cancer index and extent of debulking. But there is no consensus on the

sensitivity and specificity of this technique. Inflammatory reactions, fibrotic changes, previous treatments, mucinous morphology, depth of deposits, and nonspecific retention may lead to false results. Near-infrared light is not able to penetrate into deeply seated deposits. Therefore, ICG fluorescence should guide palpation or exploration and not alone decide on resectability.

Detection of Colorectal Liver Metastases

Tumours can disturb local biliary excretion and produce a fluorescent rim around metastases, particularly after administration one or more days before surgery. Intraoperative studies have shown that ICG fluorescence may detect small superficial colorectal liver metastases that are overlooked by inspection and, in some cases, by intraoperative ultrasonography [53-55]. However, efficacy of this technique is limited to lesions close to the hepatic surface because of restricted tissue penetration. In addition, benign or treatment-related abnormalities can fluoresce, and background liver signal depends on timing and hepatic function. To sum up, intraoperative ultrasonography remains indispensable for deep lesions and vascular relationships, while fluorescence is best used as a complementary surface survey and margin-orientation tool.

Fluorescence Guidance During Transanal Total Mesorectal Excision

Transanal total mesorectal excision was developed to address difficult distal pelvic dissection, but correct orientation during dissection in the unfamiliar bottom-up view can be challenging. Peritumoral or mesorectal ICG injection has been described as an adjunct for delineating tissue planes and facilitating rendezvous between abdominal and transanal teams [56]. Nevertheless, relevant evidence is mostly technical and observational. In addition, since transanal total mesorectal excision has oncological issues, fluorescence alone cannot substitute for proper training and quality assurance.

Educational Applications

Fluorescence imaging provides a visual demonstration of perfusion that can be reviewed by the operating team. In a study of surgical beginners, ICG angiography improved the ability to assess bowel perfusion and influenced intraoperative decision-making [57]. It may therefore help trainees connect mesenteric division and tissue handling with the resulting perfusion pattern.

Education must also address misinterpretation, since surgical trainees may overvalue a bright image, assume that fluorescence excludes leakage, or fail to recognize technical factors that alter signal intensity. Structured teaching should integrate fluorescence findings with anatomy, systemic physiology, anastomotic technique, and postoperative risk.

Limitations of Intraoperative Indocyanine Green

The principal limitation of ICG fluorescence imaging is the absence of a universally accepted definition of an adequate perfusion pattern. Most surgeons interpret fluorescence subjectively, and substantial interobserver variation has been documented [35]. Intensity in itself is an unreliable index since it depends on dose, dilution, time of administration, camera set-up, tissue depth, environmental variables, and proprietary image enhancement techniques. While time-related indices like the fluorescence slope, time to peak, and intensity ratios might be more meaningful, their cut-offs have not been validated yet.

Protocol inconsistency is quite high. Different studies vary in dose (fixed or weight-dependent), timing of dose relative to transection, number of doses, distance of imaging, criteria for a positive test, and the steps taken following an abnormal finding. In addition, the haemodynamic parameters are frequently inadequately reported. A recent systematic review of quantitative fluorescence tests found considerable differences in acquisition and analysis techniques, with a very few using real-time analysis [34].

It should be also taken in to consideration that ICG fluorescence assesses perfusion at the time of imaging. Thus, it is not able to detect a later thrombotic event, excessive postoperative tension, staple-line disruption, pelvic infection, or impaired healing from systemic disease. The technique may also create false reassurance and it is highlighted that a surgeon should not preserve a technically compromised or tensioned anastomosis solely because fluorescence appears satisfactory.

Adverse reactions after ICG injection are rare but potentially severe. ICG administration adds cost, and access to compatible equipment varies between institutions. Intraureteral and peritumoral applications introduce separate procedural and regulatory considerations. Finally, much of the broader application literature consists of small cohorts and feasibility studies, making clinical effectiveness and cost-effectiveness uncertain.

FUTURE PERSPECTIVES

Quantitative perfusion assessment requires a distinction between absolute fluorescence intensity and temporal or normalised measurements. Absolute intensity is strongly influenced by the imaging platform, camera

distance and angle, illumination, system settings, and ICG dose, making values difficult to compare across devices or acquisition protocols. Time-based parameters, such as time-to-fluorescence and time-to-peak, and normalised measures, such as intensity ratios, may facilitate comparison, but remain sensitive to acquisition methods and physiological conditions. The fluorescence slope combines temporal and intensity information and therefore also requires calibration and a clearly defined calculation method [34,58]. Although automated analysis and AI may help characterize perfusion patterns, accurate classification alone does not establish clinical usefulness [59]. The key requirement is a prospectively validated threshold, transferable across platforms or calibrated for a specific system, that guides an actionable surgical decision. Validation should establish whether threshold-guided management reduces clinically relevant anastomotic leakage compared with conventional assessment.

Deep learning is also being explored in the histopathological assessment of colorectal cancer. Studies have shown that these algorithms can distinguish tumour from non-neoplastic tissue and predict microsatellite instability from routine hematoxylin-and-eosin images [60,61]. These findings suggest a possible role in assisting pathologists with tissue classification and selecting cases for further molecular testing. However, performance may vary with staining methods, scanners, and patient populations, and prospective validation is needed before wider clinical use. Although separate from ICG fluorescence imaging, this research provides another example of how automated image analysis may support colorectal cancer care.

Recent evidence syntheses published after the completion of the major contemporary trials sharpen this risk-adapted interpretation. Mc Entee et al. found that ICG fluorescence frequently changes the planned transection point and is associated with lower AL rates, while also emphasizing that patients requiring a fluorescence-guided change are an intrinsically higher-risk subgroup [62]. Updated randomised-trial meta-analyses published in 2026, incorporating up to ten trials, reported reductions in overall or clinically significant AL mainly concentrated in left-sided and rectal resections, with no significant benefit after right-sided procedures [63,64]. Similarly, the 2025 SAGES evidence synthesis also reported lower colorectal AL and substantially more intraoperative changes in the transection point, but judged evidence for several other gastrointestinal applications to be limited or inconclusive [65]. These pooled findings strengthen the rationale for selective use of ICG while remaining compatible with the neutral primary findings of several individual trials.

Data supporting outcomes other than anastomotic examination and AL prevention are increasing but are still in early stage. One such study is a prospective study conducted in one center in 2026 involving 113 patients undergoing laparoscopic sigmoid and rectal cancer surgery. No statistically significant difference was observed in the AL incidence rate, but there were no anastomotic strictures after fluorescence examination as opposed to 11.4% in the control group [66]. Cross-specialty evidence also illustrates the wider potential of the platform. A 2026 systematic review of 17 studies in minimally invasive hernia surgery described feasible use for bowel and abdominal-wall perfusion, vascular and anatomical delineation, and lymphatic mapping, but the evidence consisted mainly of small observational reports with heterogeneous protocols [67]. Such findings support broader physiological and navigational applications of ICG while reinforcing the need for indication-specific validation.

Further research would have to refine the indications for fluorescence. Data indicate that the operative field and individual risks influence the effect that can be achieved. A single protocol for right colectomy, low anterior resection, redo pelvis surgery, and acute ischemic bowel disease would not work well. An individualised approach taking into account patient characteristics, anastomosis location, haemodynamic conditions, and quantitative imaging would yield better results than a blanket protocol. In addition, novel renal excreted fluorophores would allow for better visualisation of ureters, targeting tumours, and deeper penetration. Specificity could be improved with molecularly-targeted imaging agents directed at tumour receptors.

Last but not least, establishment of reporting standards is necessary. Studies should specify the device, dose, timing, number of injections, imaging distance, haemodynamic state, interpretation method, frequency and type of change in intraoperative plan, anastomotic level, diversion, and standardised AL grade.

CONCLUSIONS

ICG fluorescence imaging is a valuable tool in colorectal surgery. While most mature application is anastomotic perfusion assessment, numerous contemporary randomised trials show that clinical benefit is context-dependent rather than universal. The strongest rationale appears to be in left-sided and rectal reconstruction and in cases where conventional assessment is not adequate. Ureteral visualisation, lymphatic mapping, lesion localisation, and detection of selected metastatic deposits are promising but supported mainly by lower-level evidence.

In each and every instance, ICG fluorescence should be used as a supplement rather than a substitute for good

operative technique. The current shortcomings of ICG imaging lie more in the process of its interpretation than in the actual production of the image itself. In order to use fluorescence as an objective decision aid, standardised procedures and quantitative criteria must be defined.

Acknowledgements: *None.*

Artificial Intelligence Statement: *No generative artificial intelligence (AI) tools were used in the preparation, writing, editing, or scientific interpretation of this manuscript. All content was developed and critically reviewed by the authors.*

Funding: *This research received no external funding.*

Conflict of Interest: *The authors declare no conflict of interest.*

REFERENCES

1. Keller DS, Ishizawa T, Cohen R, Chand M. Indocyanine green fluorescence imaging in colorectal surgery: Overview, applications, and future directions. Lancet Gastroenterol Hepatol. 2017 Oct;2(10):757-66.
2. Garoufalia Z, Wexner SD. Indocyanine green fluorescence-guided surgery in colorectal surgery. J Clin Med. 2023 Jan;12(2):494.
3. US Preventive Services Task Force, Davidson KW, Barry MJ, Mangione CM, Cabana M, Caughey AB, Davis EM, et al. Screening for colorectal cancer: US Preventive Services Task Force recommendation statement. JAMA. 2021 May;325(19):1965-77.
4. Brown SR, Mathew R, Keding A, Marshall HC, Brown JM, Jayne DG. The impact of postoperative complications on long-term quality of life after curative colorectal cancer surgery. Ann Surg. 2014 May;259(5):916-23.
5. Hammond J, Lim S, Wan Y, Gao X, Patkar A. The burden of gastrointestinal anastomotic leaks: an evaluation of clinical and economic outcomes. J Gastrointest Surg. 2014 Jun;18(6):1176-85.
6. Karliczek A, Harlaar NJ, Zeebregts CJ, Wiggers T, Baas PC, van Dam GM. Surgeons lack predictive accuracy for anastomotic leakage in gastrointestinal surgery. Int J Colorectal Dis. 2009 May;24(5):569-76.
7. Alander JT, Kaartinen I, Laakso A, Patila T, Spillmann T, Tuchin VV, et al. A review of indocyanine green fluorescent imaging in surgery. Int J Biomed Imaging [Internet]. 2012; 2012:940585. Available from: https://onlinelibrary.wiley.com/doi/epdf/10.1155/2012/940585
8. Kudszus S, Roesel C, Schachtrupp A, Hoer JJ. Intraoperative laser fluorescence angiography in colorectal surgery: a noninvasive analysis to reduce the rate of anastomotic leakage. Langenbecks Arch Surg. 2010 Nov;395(8):1025-30.
9. Boni L, David G, Dionigi G, Rausei S, Cassinotti E, Fingerhut A. Indocyanine green-enhanced fluorescence to assess bowel perfusion during laparoscopic colorectal resection. Surg Endosc. 2016 Jul;30(7):2736-42.
10. Jafari MD, Lee KH, Halabi WJ, Mills SD, Carmichael JC, Stamos MJ, et al. The use of indocyanine green fluorescence to assess anastomotic perfusion during robotic-assisted laparoscopic rectal surgery. Surg Endosc 2013 Feb;27:3003-8.
11. Jafari MD, Wexner SD, Martz JE, McLemore EC, Margolin DA, Sherwinter DA, et al. Perfusion assessment in laparoscopic left-sided/anterior resection: a multi-institutional study. J Am Coll Surg 2015 Jan;220(1):82-92.e1.
12. Lucarini A, Guida AM, Orville M, Panis Y. Indocyanine green fluorescence angiography could reduce the risk of anastomotic leakage in rectal cancer surgery: A systematic review and meta-analysis of randomized controlled trials. Colorectal Dis. 2024 Mar;26(3):408-16.
13. Afridi A, Zulfiqar A, Sajjad F, Shahid I, Habib H, Saleem Y, et al. Efficacy and safety of indocyanine green fluorescence imaging in colorectal cancer: a systematic review and meta-analysis of randomized controlled trials. Int J Colorectal Dis. 2025 Sep;40(1):193.
14. De Nardi P, Elmore U, Maggi G, Maggiore R, Boni L, Cassinotti E, et al. Intraoperative angiography with indocyanine green to assess anastomosis perfusion in patients undergoing laparoscopic colorectal resection: Results of a multicenter randomized controlled trial. Surg Endosc. 2020 Jan;34(1):53-60.
15. Alekseev M, Rybakov E, Shelygin Y, Chernyshov S, Zarodnyuk I. A study investigating the perfusion of colorectal anastomoses using fluorescence angiography: results of the FLAG randomized trial. Colorectal Dis. 2020 Sep;22(9):1147-53.
16. Watanabe J, Takemasa I, Kotake M, Noura S, Kimura K, Suwa H, et al. Blood perfusion assessment by indocyanine green fluorescence imaging for minimally invasive rectal cancer surgery (EssentiAL trial): A randomized clinical trial. Ann Surg. 2023 Oct;278(4):e688-94.
17. Faber RA, Meijer RPJ, Droogh DHM, Jongbloed JJ, Bijlstra OD, Boersma F, et al. Indocyanine green near-infrared fluorescence bowel perfusion assessment to prevent anastomotic leakage in minimally invasive colorectal surgery (AVOID): a multicentre, randomised, controlled, phase 3 trial. Lancet Gastroenterol Hepatol. 2024 Oct;9(10):924-34
18. Rinne JKA, Huhta H, Pinta T, Turunen A, Mattila A, Tahkola K, et al. Indocyanine green fluorescence imaging in prevention of colorectal anastomotic leakage: A randomized clinical trial. JAMA Surg. 2025 May;160(5):486-93.
19. Jayne D, Croft J, Corrigan N, Quirke P, Cahill RA, Ainsworth G, et al. Intraoperative fluorescence angiography with indocyanine green to prevent anastomotic leak in rectal cancer surgery (IntAct): an unblinded randomised controlled trial. Lancet Gastroenterol Hepatol. 2025 Sep;10(9):806-17.
20. Rahbari NN, Weitz J, Hohenberger W, Heald RJ, Moran B, Ulrich A, et al. Definition and grading of anastomotic leakage following anterior resection of the rectum: A proposal by the International Study Group of Rectal Cancer. Surgery. 2010 Mar;147(3):339-51.
21. Hyman N, Manchester TL, Osler T, Burns B, Cataldo PA. Anastomotic leaks after intestinal anastomosis: it is later than you think. Ann Surg. 2007 Feb;245(2):254-8.
22. McDermott FD, Heeney A, Kelly ME, Steele RJ, Carlson GL, Winter DC. Systematic review of preoperative, intraoperative and postoperative risk factors for colorectal

anastomotic leaks. Br J Surg. 2015 Apr;102(5):462-79.
23. Perez RO, Sousa A, Bresciani C, Proscurshim I, Coser R, Kiss D, et al. Endoscopic management of postoperative stapled colorectal anastomosis hemorrhage. Tech Coloproctol. 2007 Mar;11(1):64-6.
24. Martinez-Serrano MA, Pares D, Pera M, Pascual M, Courtier R, Egea MJ, et al. Management of lower gastrointestinal bleeding after colorectal resection and stapled anastomosis. Tech Coloproctol. 2009 Mar;13(1):49-53.
25. Ridtitid W, Siripun A, Rerknimitr R. Stricture at colorectal anastomosis: to dilate or to incise. Endosc Int Open [Internet]. 2018; 6:E340-1. Available from: https://pmc.ncbi.nlm.nih.gov/articles/PMC5844386/
26. Shogan BD, Vogel JD, Davis BR, Keller DS, Ayscue JM, Goldstein LE, et al. The American Society of Colon and Rectal Surgeons Clinical Practice Guidelines for Preventing Surgical Site Infection. Dis Colon Rectum. 2024 Nov;67(11):1368-82.
27. Panos G, Mulita F, Akinosoglou K, Liolis E, Kaplanis C, Tchabashvili L, et al. Risk of surgical site infections after colorectal surgery and the most frequent pathogens isolated: a prospective single-centre observational study. Med Glas (Zenica). 2021 Aug;18(2):438-43.
28. Verras GI, Mulita F. Butyrylcholinesterase levels correlate with surgical site infection risk and severity after colorectal surgery: A prospective single-center study. Front Surg [Internet]. 2024 Aug;11:1379410. Available from: https://pubmed.ncbi.nlm.nih.gov/39229253/
29. Morgan RB, Shogan BD. The science of anastomotic healing. Semin Colon Rectal Surg [Internet]. 2022; 33:100879. Available from: https://www.sciencedirect.com/science/article/abs/pii/S1043148922000203?via%3Dihub
30. Shogan BD, Belogortseva N, Luong PM, Zaborin A, Lax S, Bethel C, et al. Collagen degradation and MMP9 activation by Enterococcus faecalis contribute to intestinal anastomotic leak. Sci Transl Med [Internet] 2015 May; 7 (286):286ra68. Available from: https://pubmed.ncbi.nlm.nih.gov/25947163/
31. Urbanavicius L, Pattyn P, Van de Putte D, Venskutonis D. How to assess intestinal viability during surgery: a review of techniques. World J Gastrointest Surg. 2011 May;3(5):59-69.
32. Bryski MG, Frenzel Sulyok LG, Kaplan L, Singhal S, Keating JJ. Techniques for intraoperative evaluation of bowel viability in mesenteric ischemia: A review. Am J Surg. 2020 Aug;220(2):309-15.
33. Jansen-Winkeln B, Germann I, Kohler H, Mehdorn M, Maktabi M, Sucher R, et al. Comparison of hyperspectral imaging and fluorescence angiography for the determination of the transection margin in colorectal resections: A comparative study. Int J Colorectal Dis. 2021 Feb;36(2):283-91.
34. McEntee PD, Singaravelu A, McCarrick CA, Murphy E, Boland PA, Cahill RA. Quantification of indocyanine green fluorescence angiography in colorectal surgery: a systematic review of the literature. Surg Endosc. 2025 Apr;39(4):2677-91.
35. Soares AS, Clancy NT, Bano S, Raza I, Diana M, Lovat LB, et al. Interobserver variability in the assessment of fluorescence angiography in the colon. Surg Innov. 2023 Feb;30(1):45-9.
36. Jafari MD, Pigazzi A, McLemore EC, Mutch MG, Haas E, Rasheid SH, et al. Perfusion Assessment in Left-Sided/Low Anterior Resection (PILLAR III): A Randomized, Controlled, Parallel, Multicenter Study Assessing Perfusion Outcomes With PINPOINT Near-Infrared Fluorescence Imaging in Low Anterior Resection. Dis Colon Rectum. 2021 Aug;64(8):995-1002.
37. Slooter MD, Eshuis WJ, Cuesta MA, Gisbertz SS, van Berge Henegouwen MI, Bemelman WA, et al. Optimizing omentoplasty for management of chronic pelvic sepsis by intra-operative fluorescence angiography: a comparative cohort study. Colorectal Dis 2020; 22:2252-61.
38. Lobbes LA, Hoveling RJM, Schmidt LR, Berns S, Weixler B. Objective perfusion assessment in gracilis muscle interposition: a novel software-based approach to indocyanine green-derived near-infrared fluorescence in reconstructive surgery. Life (Basel). 2022 Feb;12(2):278.
39. Slooter MD, van der Does de Willebois EML, Joosten JJ, Reijntjes MA, Buskens CJ, Tanis PJ, et al. Fluorescence perfusion assessment of vascular ligation during ileal pouch-anal anastomosis. Tech Coloproctol. 2023 Apr;27(4):281-90.
40. Halabi WJ, Jafari MD, Nguyen VQ, Carmichael JC, Mills S, Pigazzi A, et al. Ureteral injuries in colorectal surgery: an analysis of trends, outcomes, and risk factors over a 10-year period in the United States. Dis Colon Rectum. 2014 Feb;57(2):179-86.
41. Mandovra P, Kalikar V, Patankar RV. Real-time visualization of ureters using indocyanine green during laparoscopic surgeries: can we make surgery safer? Surg Innov. 2019 Aug;26(4):464-8.
42. White LA, Joseph JP, Yang DY, Kelley SR, Mathis KL, Behm K, et al. Intraureteral indocyanine green augments ureteral identification and avoidance during complex robotic-assisted colorectal surgery. Colorectal Dis. 2021 Mar;23(3):718-23.
43. Ushijima H, Kawamura J, Ueda K, Yane Y, Yoshioka Y, Daito K, et al. Visualization of lymphatic flow in laparoscopic colon cancer surgery using indocyanine green fluorescence imaging. Sci Rep [Internet] 2020;10:14274. Available from: https://www.nature.com/articles/s41598-020-71215-3?utm_source=researchgate.net&utm_medium=article
44. Handgraaf HJM, Boogerd LSF, Verbeek FPR, Tummers QRJG, Hardwick JCH, Baeten CIM, et al. Intraoperative fluorescence imaging to localize tumors and sentinel lymph nodes in rectal cancer. Minim Invasive Ther Allied Technol. 2016;25(1):48-53.
45. Nishigori N, Koyama F, Nakagawa T, Nakamura S, Ueda T, Inoue T, et al. Visualization of lymph/blood flow in laparoscopic colorectal cancer surgery by ICG fluorescence imaging. Ann Surg Oncol. 2016 Feb:23(Suppl 2):S266-74.
46. Emile SH, Elfeki H, Shalaby M, Sakr A, Sileri P, Laurberg S, et al. Sensitivity and specificity of indocyanine green near-infrared fluorescence imaging in detection of metastatic lymph nodes in colorectal cancer: systematic review and meta-analysis. J Surg Oncol. 2017 Nov;116(6):730-40.
47. Litchinko A, Meyer J, Buhler L, Ris F, Adamina M. Fluorescence indocyanine green for sentinel-lymph-node mapping in colorectal cancer: a systematic review. Langenbecks Arch Surg. 2025 Jul;410(1):202.

48. Lee SJ, Sohn DK, Han KS, Kim BC, Hong CW, Park SC, et al. Preoperative tattooing using indocyanine green in laparoscopic colorectal surgery. Annals of Coloproctology 2018;34(4):206-11.
49. Nagata J, Fukunaga Y, Akiyoshi T, Konishi T, Fujimoto Y, Nagayama S, et al. Colonic marking with near-infrared, light-emitting, diode-activated indocyanine green for laparoscopic colorectal surgery. Dis Colon Rectum. 2016 Feb;59(2):e14-8
50. Varanese M, Arcieri S, Lauro A, Panetta C, Eberspacher C, Palma R, et al. Indocyanine green tattooing during colonoscopy as a guide to laparoscopic colorectal cancer surgery: a literature review. Surg Innov 2024; 31(1):103-10.
51. Liberale G, Vankerckhove S, Gomez Caldon M, Ahmed B, Moreau M, El Nakadi I, et al. Fluorescence imaging after indocyanine green injection for detection of peritoneal metastases in patients undergoing cytoreductive surgery for peritoneal carcinomatosis from colorectal cancer: a pilot study. Ann Surg. 2016 Dec;264(6):1110-5.
52. Barabino G, Klein JP, Porcheron J, Grichine A, Coll JL, Cottier M. Intraoperative near-infrared fluorescence imaging using indocyanine green in colorectal carcinomatosis surgery: proof of concept. Eur J Surg Oncol 2016 Dec;42(12):1931-7.
53. Ishizawa T, Fukushima N, Shibahara J, Masuda K, Tamura S, Aoki T, et al. Real-time identification of liver cancers by using indocyanine green fluorescent imaging. Cancer 2009 Jun;115(11):2491-504.
54. Peloso A, Franchi E, Canepa MC, Barbieri L, Briani L, Ferrario J, et al. Combined use of intraoperative ultrasound and indocyanine green fluorescence imaging to detect liver metastases from colorectal cancer. HPB (Oxford). 2013 Dec;15(12):928-34.
55. van der Vorst JR, Schaafsma BE, Hutteman M, Verbeek FPR, Liefers GJ, Hartgrink HH, et al. Near-infrared fluorescence-guided resection of colorectal liver metastases. Cancer. 2013 Sep;119(18):3411-8.
56. Dapri G, Cahill R, Bourgeois P, Liberale G, Gomez Galdon M, Cadiere GB. Peritumoural injection of indocyanine green fluorescence during transanal total mesorectal excision to identify the plane of dissection: a video vignette. Colorectal Dis. 2017 Jun;19(6):599-600
57. Kim DH, Son GM, Kwon MS, Baek SH, Park BS, Kim HS. Educational benefits of intraoperative indocyanine green angiography for surgical beginners during laparoscopic colorectal surgery. J Minim Invasive Surg [Internet]. 2018 Mar; 21(1):25-30. Available from: https://www.e-jmis.org/journal/view.html?doi=10.7602/jmis.2018.21.1.25
58. Son GM, Kwon MS, Kim Y, Kim J, Kim SH, Lee JW. Quantitative analysis of colon perfusion pattern using indocyanine green angiography in laparoscopic colorectal surgery. Surg Endosc. 2019 May;33(5):1640-9
59. Park SH, Park HM, Baek KR, Ahn HM, Lee IY, Son GM. Artificial intelligence based real-time microcirculation analysis system for laparoscopic colorectal surgery. World J Gastroenterol. 2020 Nov;26(44):6945-62.
60. Kather JN, Pearson AT, Halama N, Jäger D, Krause J, Loosen SH, et al. Deep learning can predict microsatellite instability directly from histology in gastrointestinal cancer. Nat Med. 2019 Jul;25(7):1054-56.
61. Echle A, Grabsch HI, Quirke P, van den Brandt PA, West NP, Hutchins GGA, et al. Clinical-grade detection of microsatellite instability in colorectal tumors by deep learning. Gastroenterology. 2020 Oct;159(4):1406-1416.e11.
62. Mc Entee PD, Singaravelu A, Boland PA, Moynihan A, Creavin B, Cahill RA. Impact of indocyanine green fluorescence angiography on surgeon action and anastomotic leak in colorectal resections: a systematic review and meta-analysis. Surg Endosc. 2025 Mar;39(3):1473-89.
63. Maroli A, Paoluzzi Tomada E, Foppa C, Carvello M, Ris F, Hompes R, et al. Indocyanine green fluorescence to prevent anastomotic leak in colorectal surgery: an updated systematic review and meta-analysis on randomized controlled trials. Surg Endosc. 2026 Mar;40(3):1815-27.
64. Boalot A, Yau J, Hasan M, Wang X, Younes A, Hannah M, et al. Use of intraoperative ICG fluorescence angiography to reduce anastomotic leak in left-sided colorectal resections: a systematic review and meta-analysis of RCTs. Colorectal Dis [Internet]. 2026 Feb;28(2):e70378. Available from: https://onlinelibrary.wiley.com/doi/10.1111/codi.70378
65. Kapsampelis P, Calabrese EC, Kumar SS, Shehata D, Bansal V, Carsky K, et al. SAGES 2025 systematic review and meta-analysis for fluorescence image-guided gastrointestinal surgery using indocyanine green. Surg Endosc. 2025 Dec;39(12):7860-904.
66. Semeniv S, Pedziwiatr M, Rymarowicz J, Szpakowska A, Jurczak M, Putowski M, et al. Indocyanine green fluorescence angiography in laparoscopic sigmoid and rectal cancer surgery: no reduction in anastomotic leakage but a lower incidence of anastomotic strictures: a prospective single-center study. Front Surg [Internet] 2026;13:1822071. Available from: https://www.frontiersin.org/journals/surgery/articles/10.3389/fsurg.2026.1822071/full
67. Pavlidis L, Geropoulos G, Kechagias KS, Psarras K, Patel V, Reza L, et al. Near-infrared fluorescence with indocyanine green for minimally invasive hernia surgery: a systematic review and evidence synthesis. World J Clin Cases [Internet]. 2026 May;14(14):118964. Available from: https://www.wjgnet.com/2307-8960/full/v14/i14/118964