Case Report

Hell J Surg. 2025 Jul-Sep;95(3):157–161
doi: 10.59869/25077

Appendiceal Endometriosis Presenting as Acute Appendicitis: Successful Management with Laparoscopic Appendectomy

Panayiotis Antoniou[1], Giorgos Skouroumouni[1], Athanasios Bounovas[1], Maria Emmanouela Kopaka[2], Nikolaos Nikitakis[1]

[1]*Second Department of General Surgery, Sismanoglion General Hospital, Athens, Greece*
[2]*Department of Pathology, Sismanoglion General Hospital, Athens, Greece*

ABSTRACT

Appendiceal endometriosis is a rare form of endometriosis that may mimic acute appendicitis, thereby posing a diagnostic challenge in surgical practice. Preoperative differentiation between these entities remains difficult due to the nonspecific nature of the condition in terms of clinical presentation and imaging findings. Herein, we report a case of a young woman who presented with right iliac fossa pain and nausea. Laboratory investigations and imaging findings on ultrasound and computed tomography were suggestive of acute appendicitis. The patient underwent laparoscopic appendectomy, and histopathological examination revealed appendiceal endometriosis. This case demonstrates the inherent limitations of preoperative diagnosis and highlights that surgical management is generally guided by clinical suspicion of acute appendicitis rather than by aetiological identification. The important role of laparoscopy in both diagnosis and management was addressed. Particular emphasis is given to diagnostic considerations, intraoperative assessment, and implications for general surgeons managing women of reproductive age with suspected acute appendicitis.

Key words: *Appendiceal endometriosis; acute appendicitis; laparoscopic appendectomy; case report*

INTRODUCTION

Endometriosis is an estrogen-dependent condition characterised by the presence of endometrial glands and stroma outside the uterine cavity and myometrium. The estimated prevalence is approximately 8-10% among women of reproductive age. Endometriosis can occur at several anatomical sites, including pelvic sites, which involve the ovaries, oviducts, and recto-uterine ligaments. Less frequently, it may occur at extra-pelvic sites, including the gastrointestinal (GI) or urinary tract, chest cavity, and soft tissues [1].

Gastrointestinal involvement is relatively uncommon, and appendiceal endometriosis (AE) represents a rare manifestation of the disease. It may occur in women with previously diagnosed endometriosis as well as in those without a known gynaecological history. From a general surgical perspective, the clinical significance of this entity lies not in altering acute operative management, but in its postoperative recognition and the subsequent consideration of underlying endometriosis, particularly in women of reproductive age. This case report aims to highlight the diagnostic limitations and to discuss the clinical implications for general surgeons who will manage similar presentations. Written informed consent was obtained from the patient. This report was conducted in

Corresponding author:
Panayiotis Antoniou
Sismanogliou 1, Marousi, Athens, Greece 15126
Tel.: +30 6944 561 029, e-mail: panayiotis.antoniou@outlook.com

Submission: 06.06.2026, Acceptance: 01.11.2026

accordance with the Declaration of Helsinki, and ethical approval was provided by the scientific council of the Institute. This case report was prepared in accordance with the CARE Guidelines.

CASE REPORT

A 39-year-old female patient (G0P0) presented to the A&E department complaining of right lower quadrant pain accompanied by nausea. The onset of pain was 24 hours earlier without any correlation with her menstrual cycle. She was on day 21 of her menstrual cycle, which was regular, and the patient did not report cyclic pelvic pain or any other gynaecological symptoms. The medical and gynaecological history was unremarkable, and no previous surgeries were reported. The patient was afebrile and haemodynamically stable. Physical examination revealed right lower quadrant pain, accompanied by rebound tenderness, with positive McBurney's sign. Laboratory results showed an elevated white blood cell count of 19000/μL with an increased neutrophil count of 83% and C-reactive protein at 28 (normal range: <6 mg/dL). Beta-human chorionic gonadotropin testing was negative. Abdominal ultrasound scan revealed fluid accumulation in the right lower quadrant area accompanied by a dilated tubular structure. Contrast-enhanced abdominal CT scan demonstrated a mildly dilated intrapelvic appendix (6.67 mm) with focal swelling at the tip, extending parallel to the right parametrium. A small adjacent fluid collection and fat stranding were also reported (Figure 1).

Taking all of the above into account, laparoscopic exploration was performed. The intraoperative findings were consistent with those described on the CT scan, revealing a mildly dilated and edematous appendix mainly at the tip with a small amount of fluid. No macroscopic features suggestive of endometriosis were observed in the appendix. Furthermore, a systematic laparoscopic inspection of the abdominal and pelvic cavities was performed to identify any additional macroscopic endometriotic lesions. However, no such lesions were identified. Laparoscopic appendectomy was carried out successfully. The postoperative period was uneventful, and the patient was discharged 48 hours after the operation. Gynaecological assessment was then performed to determine the extent of endometriosis, however no other endometriotic lesions were identified. Histopathological report demonstrated an appendix measuring 4.1x0.6 cm in diameter, and at the tip, multiple foci of endometrial tissue were revealed (ER, CD10: compatible immunophenotype). On the serosal surface, focal fibrinopurulent exudates were observed, with accompanying changes of mesothelial/histiocytic hyperplasia [WT-1 (+), CD68 (+)] (Figure 2). The patient was advised to undergo further outpatient gynaecological evaluation for the management of endometriosis.

DISCUSSION

Appendiceal endometriosis is a rare but important differential diagnosis within the spectrum of appendiceal pathology. In clinical practice, it most commonly presents with signs and symptoms indistinguishable from acute appendicitis, leading to surgical management based on a presumptive diagnosis rather than aetiological certainty. Consequently, the definitive diagnosis is typically established only after histopathological examination of the resected appendix. This diagnostic uncertainty, however, does not influence initial operative decision-making, as the standard surgical approach remains appendectomy in the setting of suspected acute appendicitis.

Carl von Rokitansky was the first to describe appendiceal endometriosis (AE) in 1860. AE is rare, especially in women with an unremarkable gynaecological history. The estimated prevalence in the general population is 0.4% and can reach up to 1.7% in patients with a known history of endometriosis [2,3]. Patients with AE may be asymptomatic or present with symptoms similar to those of acute appendicitis such as lower abdominal pain, anorexia, nausea, and vomiting. AE may cause cyclic right lower quadrant pain associated with menstruation, melena or lower GI tract bleeding and, in severe cases, cecal intussusception or perforation. Based on the current literature, the prevalence of appendiceal endometriosis among women undergoing surgery



FIGURE 1. Computed tomography scan findings. Contrast-enhanced CT scan demonstrating a mildly dilated intrapelvic appendix (6.67 mm in diameter) with focal swelling of the tip (arrow). The appendix extends parallel to the right parametrium and is associated with a small adjacent fluid collection and surrounding fat stranding.

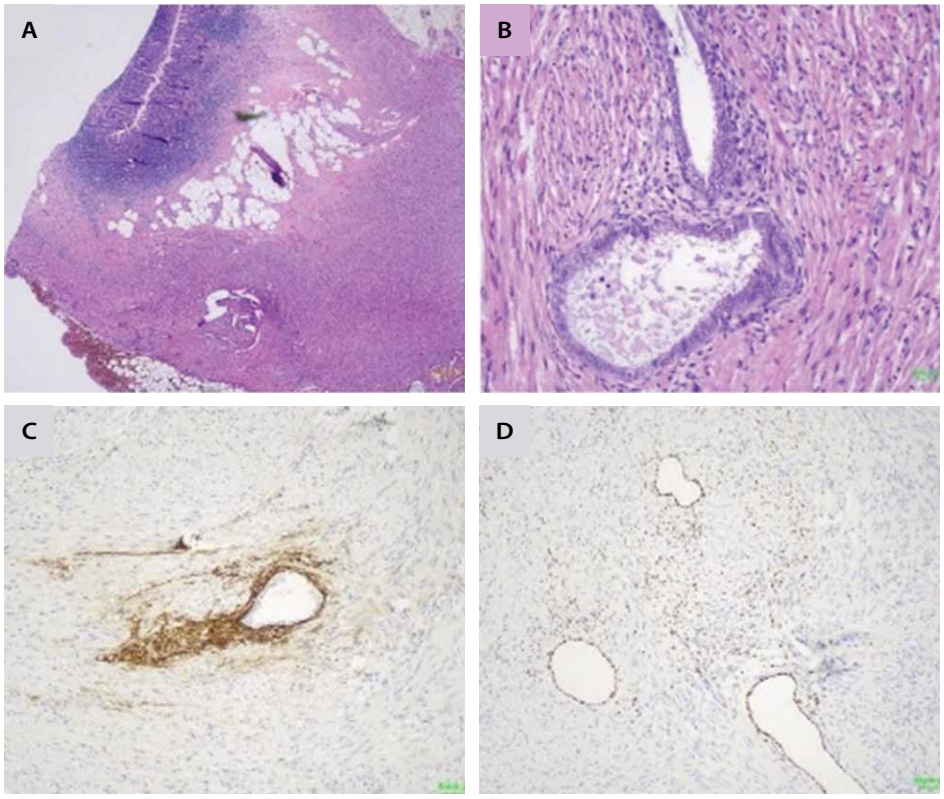

FIGURE 2: Appendiceal endometriosis involving the muscular wall. (A) Low-power view of the appendiceal wall demonstrating a nodular focus of endometriosis within the muscularis propria, composed of endometrial glands and stroma associated with surrounding fibrosis and mild inflammatory infiltrate (H&E, ×20). (B) Higher magnification showing endometrial-type glands lined by a single layer of columnar epithelial cells without cytologic atypia, surrounded by characteristic endometrial stroma (H&E, ×200). (C) Immunohistochemical staining for CD10 highlights the stromal component with diffuse cytoplasmic positivity, confirming endometrial stromal differentiation (CD10, ×100). (D) Immunohistochemical staining for estrogen receptor (ER) demonstrates nuclear positivity in both glandular epithelial and stromal cells, supporting endometrial origin (ER, ×100).

who present with a clinical picture resembling acute appendicitis is 2.67% [1].

The pathogenesis of appendiceal endometriosis remains incompletely understood and is likely multifactorial. Sampson's theory of retrograde menstruation, which proposes the reflux and implantation of viable endometrial tissue through the fallopian tubes, remains the most widely accepted mechanism for endometriosis development and may explain appendiceal involvement through pelvic dissemination. Histopathological findings demonstrating endometriotic implants predominantly within the muscularis propria and subserosal layers of the appendix support the possibility of ectopic transplantation. However, the presence of appendiceal endometriosis in patients without concurrent ovarian or pelvic disease challenges retrograde menstruation as the sole pathogenic mechanism. Alternative pathways, including coelomic metaplasia and lymphatic or haematogenous dissemination have therefore been proposed. These mechanisms may contribute to the occurrence of isolated appendiceal endometriosis and explain its heterogeneous clinical presentation [1, 4].

Ectopic endometrial tissue within the appendix responds to cyclical hormonal stimulation, causing haemorrhage, chronic inflammation, fibrosis, and luminal obstruction. These mechanisms account for the wide spectrum of symptomatology, ranging from nonspecific abdominal symptoms to a classic presentation of acute appendicitis. AE may involve either the tip or the body of the appendix, without affecting the presentation. In contrast, the depth of appendiceal wall involvement may influence the clinical manifestations. In the majority of reported cases, endometriotic lesions are located within the muscular or seromuscular layers. When the mucosa or submucosa is involved, patients are more likely to present with symptoms resembling inflammatory, ischaemic, or infectious enteritis or colitis [5].

The clinical presentation and laboratory findings of AE are similar to those of acute appendicitis, as previously described. In this case, the absence of gynaecological

symptoms and the lack of known history of endometriosis further limited preoperative recognition. In addition, the patient's pain was not associated with her menstrual cycle, a characteristic commonly observed in endometriosis-related pathology, further reducing the clinical suspicion that the pain was attributable to endometriosis. This reflects a key diagnostic challenge, as clinical assessment alone is insufficient for reliable identification of AE in the acute setting. Patients can be categorised into four categories: (a) asymptomatic with incidental diagnosis, (b) presenting with acute appendicitis, characterised by right lower quadrant pain and potential complications such as perforation, (c) appendiceal invagination characterised by intussusception and "currant jelly" stools, and (d) atypical symptoms such as abdominal colic, nausea, vomiting, melena, constipation, and fever [5].

Imaging modalities are routinely used in the evaluation of suspected acute appendicitis; however, in the context of appendiceal endometriosis, their diagnostic value is limited [6]. Radiological findings are typically nonspecific and largely indistinguishable from uncomplicated appendiceal inflammation, most commonly demonstrating mild appendiceal enlargement, mural thickening, periappendiceal fat stranding, or minimal fluid collection. Although these features support a diagnosis of appendicitis, they do not provide reliable indicators of ectopic endometrial tissue involvement. Both ultrasound and cross-sectional imaging lack specific criteria for identifying appendiceal endometriosis, and reported findings overlap with those of routine inflammatory appendiceal disease. Consequently, imaging alone is insufficient for preoperative differentiation, and a definitive diagnosis cannot be established on radiological grounds [3,7].

From a surgical perspective, the management of suspected appendiceal pathology is primarily guided by clinical assessment and imaging findings consistent with acute appendicitis, rather than aetiological certainty. In this context, uncertainty regarding rare underlying causes such as appendiceal endometriosis does not typically modify the operative decision-making pathway. Laparoscopy plays a central role in this setting, offering both diagnostic and therapeutic advantages by enabling direct visualisation of the appendix and the entire peritoneal cavity, as well as facilitating definitive appendectomy with low morbidity. The author's opinion is that, although in the present case no additional endometriotic lesions were identified, a systematic intraoperative assessment may be considered in women of reproductive age, particularly when intra-abdominal findings raise suspicion of endometriosis or when there is a relevant gynaecological history. In selected cases, intraoperative gynaecological consultation or evaluation may further assist in guiding comprehensive management. Importantly, given the inability to reliably differentiate appendiceal endometriosis from routine appendicitis preoperatively, laparoscopic appendectomy is commonly employed when clinical and radiological findings support a diagnosis of acute appendicitis [1,8,9].

CONCLUSION

The current literature suggests that AE is a relevant differential diagnosis in women of reproductive age presenting with acute abdominal pain and is usually identified incidentally following appendectomy for suspected appendicitis. As can be inferred from the above, preoperative diagnosis of AE is challenging in the acute setting due to similarities in clinical presentation and imaging findings with acute appendicitis. This is even more challenging when the woman has an unremarkable gynaecological history. Standard management pathways for suspected appendicitis should therefore be followed, as the possibility of AE does not alter the surgical management. Laparoscopic appendectomy followed by histopathological examination remains the definitive diagnostic and therapeutic approach. Postoperative recognition of AE and subsequent gynaecological evaluation are of vital importance.

Conflict of Interest Statement: *The authors declare no conflicts of interest.*

Funding statement: *The authors received no financial support for the research, authorship, and/or publication of this article.*

Author Contributions: *Conception: Bounovas Athanasios conceived the original idea and performed the patients' operation. Design: Skouroumouni Giorgos, Antoniou Panayiotis; Literature search: Skouroumouni Giorgos, Antoniou Panayiotis; Manuscript preparation: Skouroumouni Giorgos, Antoniou Panayiotis; Manuscript editing: Skouroumouni Giorgos, Antoniou Panayiotis; Manuscript review: All Authors; Supervision: All authors; Final approval of manuscript: All Authors.*

Ethical Approval: *Ethical approval to report this case was obtained from the ethical committee of the scientific council of Sismanoglion General Hospital of Athens (approval number/ID: 6849).*

Consent form: *Written informed consent was obtained from the individual for the publication of personal information.*

Declaration of conflicting interest: *The authors declared no potential conflicts of interest with respect to the research, authorship, and/or publication of this article.*

Data Availability statement: *Data available upon request from the corresponding author.*

REFERENCES

1. Allahqoli L, Mazidimoradi A, Momenimovahed Z, Günther V, Ackermann J, Salehiniya H, et al. Appendiceal Endometriosis: A Comprehensive Review of the Literature. Diagnostics (Basel). 2023 May 23;13(11):1827.
2. Mabrouk M, Raimondo D, Mastronardi M, Raimondo I, Del Forno S, Arena A, et al. Endometriosis of the Appendix: When to Predict and How to Manage—A Multivariate Analysis of 1935 Endometriosis Cases. J Minim Invasive Gynecol. 2020 Jan;27(1):100-6.
3. Bolcatto A, Erina M, Mandojana FI, Bruera N, Doniquian AM, Viscido GR. Acute appendicitis due to appendiceal endometriosis: Two case report and literature review. Int J Surg Case Rep [Internet]. 2025 Jan [cited 2026 Oct 15];126:110743. Available from: https://www.ovid.com/jnls/ijscr/fulltext/10.1016/j.ijscr.2024.110743~acute-appendicitis-due-to-appendiceal-endometriosis-two-case
4. Emre A, Akbulut S, Yilmaz M, Bozdag Z. An unusual cause of acute appendicitis: appendiceal endometriosis. Int J Surg Case Rep. 2013;4(1):54-7.
5. Zondervan KT, Becker CM, Missmer SA. Endometriosis. N Engl J Med. 2020 Mar;382(13):1244-56.
6. Laskou S, Papavramidis TS, Cheva A, Michalopoulos N, Koulouris C, Kesisoglou I, et al. Acute appendicitis caused by endometriosis: A case report. J Med Case Rep. 2011 Apr;5:144.
7. Kemal Memisoglu, Bora Karip, Metin Mestan, Ender Onur. The value of preoperative diagnostic tests in acute appendicitis, retrospective analysis of 196 patients. World J Emerg Surg [Internet]. 2010 Feb [cited 2026 Oct 15];5(5). Available from: https://link.springer.com/article/10.1186/1749-7922-5-5
8. Aragone L, Pasquini MT, Scasso Rebzda V, Talarico MS, Mihura M. Appendiceal endometriosis: case report of a rare differential diagnosis of acute appendicitis. Int J Surg Case Rep. 2023 Apr [cited 2025 Oct 15];105:107993. Available from: https://www.ovid.com/jnls/ijscr/fulltext/10.1016/j.ijscr.2023.107993~appendiceal-endometriosis-case-report-of-a-rare-differential