Case Report

Hell J Surg. 2025 Jul-Sep;95(3):162–165
doi: 10.59869/25078

Lipofuscin Pigmentation of the Gallbladder: A Rare Case Report and Literature Review

Dimitra Smerdi[1], Panagiotis Stratigos[1], Mpoltetsou Eumorfia[2], Panagiotis-Akindynos Petrozellis[1], Sotiris Megalemos[1], Katsaounis Dionusios[1], Rallis Georgios[1]

[1] *Surgical Department, "Elpis" General Hospital of Athens, Athens, Greece*
[2] *Pathology Department, "Elpis" General Hospital of Athens, Athens, Greece*

ABSTRACT

Pseudomelanosis is an umbrella term for a commonly encountered condition of the lower, but certainly rare in the upper, gastrointestinal tract. Plenty of other situations are associated with its incidence and medication usage as well. Most of the case reports in the literature refer to pseudomelanosis of the stomach, duodenum, and, uncommonly, oesophagus. In this paper, we present a rare case of gallbladder lipofuscin pseudomelanosis in a 25-year-old woman undergoing cholecystectomy. The aim of this study is to demonstrate a histopathological entity that has been rarely reported previously, highlighting the importance of avoiding misdiagnosis. The pathogenesis of the pseudomelanosis requires yet further investigation, as well as correlation with existing pathology findings.

Key words: *Gallbladder pseudomelanosis; histochemistry; lipofuscin pigmentation of the gallbladder; dark-colored gallbladder*

Pseudomelanosis of the gastrointestinal (GI) tract is an uncommon condition that is associated with certain predisposition factors; thus, it is mostly encountered as an incidental finding during gastrointestinal endoscopy for diagnostic and therapeutic purposes [1]. This discovery presents as pigmented black dots that cover the mucosa of the gastrointestinal tract, mimicking melanin accumulation [2]. This phenomenon is mainly observed in the lower GI tract and less commonly reported in the upper GI tract [3].

Pseudomelanosis is an umbrella term; microscopically, it is primarily caused by haemosiderin, lipofuscin, and iron or iron sulfide deposition in the mucosa, usually in the epithelial cells or histiocytes [4,5]. Various conditions are associated with pseudomelanosis, such as hypertension, diabetes mellitus, kidney impairment, and certain medications [2,5].

Pigment deposition within the gallbladder has been reported through the years, usually expressed as "melanosis" or a "dark-colored gallbladder"; thus, these cases commonly are not histopathologically proven. Some of these cases may report lipofuscin, haemosiderin, or iron accumulation, but well-documented cases describing definite lipofuscin pigmentation are rare.

In the current English-language literature, pseudomelanosis is mainly identified in gastric and duodenal endoscopy [6] and following histopathological examination, with the gallbladder not being so commonly reported. Its gross appearance as a black-colored gallbladder may cause clinical dilemmas and lead to misdiagnosis.

Herein, we present a rare case of gallbladder pseudomelanosis due to lipofuscin deposition, identified during routine biliary surgery.

Corresponding author:
Dimitra Smerdi
Imittou 129, Athens, 11 633, Athens, Greece
Tel.: +30 6978 137487, e-mail: demi.smerdi@gmail.com

Submission: 18.06.2026, Acceptance: 27.09.2026

CASE REPORT

Preoperative Assessment

A 25-year-old woman with no significant medical history and recurrent upper abdominal pain, mainly post-prandial, along with several episodes of biliary colic presented to our outpatient clinic. Her laboratory investigation was normal, while abdominal ultrasonography revealed a gallbladder without inflammatory features, along with gallstones and a thickened wall. The symptoms were compatible with chronic gallstone cholecystitis, and the patient was scheduled for laparoscopic cholecystectomy.

Surgical Management

During the operation, while inspecting the surgical site, the gallbladder was noted to be dark-colored, with a thickened and sclerotic wall. During the subserosal cholecystectomy, while dissecting the gallbladder from the liver bed in retrograde fashion, a preoperatively unrecognised replaced right hepatic artery that arose from the superior mesenteric artery was inadvertently torn, leading to severe haemorrhage and haemodynamic instability. The cholecystectomy was converted to an open procedure. Then, common bile duct injury occurred due to the massive haemorrhage. The common bile duct injury was not identified intraoperatively, the haemorrhage was controlled, and the cholecystectomy was completed.

Postoperative Course

The common bile duct injury led to the formation of a high-volume bilio-cutaneous fistula postoperatively. The postoperative computed tomography (CT) angiography confirmed a replaced right hepatic artery, a Michels type III anatomical variant (Figure 1). The patient was then referred for definite management at a tertiary hepatobiliary center.

Histopathological Examination

Regarding the histopathological examination, the gallbladder was dark-colored, with thickened walls. Microscopic examination revealed black staining within the mucosa's histiocytes that could be melanin or other pigments, such as haemosiderin, iron sulfide, or lipofuscin. The Fontana-Masson stain was negative, as was Perl's Prussian Blue. In contrast, the periodic acid–Schiff (PAS) stain was positive, indicating that lipofuscin was the cause of the pigmentation (Figure 2).

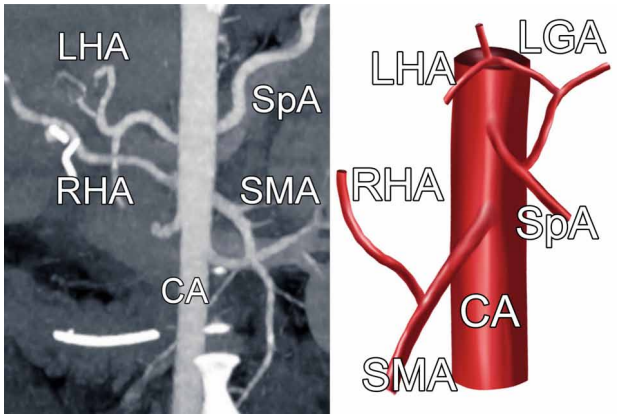

FIGURE 1. Computed Tomography Angiography showing the replaced RHA arising from the SMA and 3D illustration showing the previously discussed anatomic variant of the RHA. CA celiac aorta, LHA left hepatic artery, RHA right hepatic artery, SMA superior mesenteric artery, SpA splenic artery.

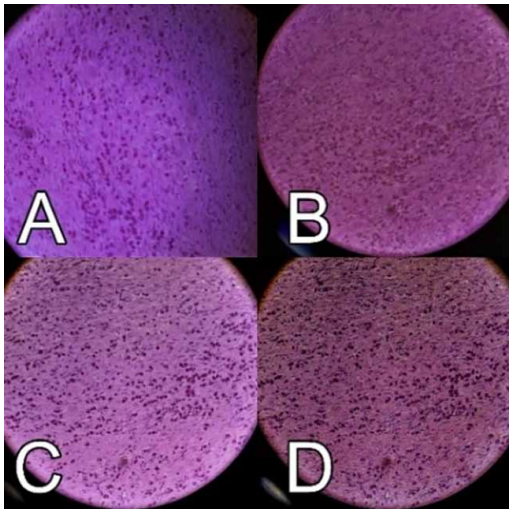

FIGURE 2. Microscopic findings of gallbladder pseudomelanosis A), B) microscopic examination of gallbladder without PAS stain, showing black stain in the mucosa that could be melanin or other stains C), D) microscopic examination of gallbladder after PAS stain, proving that the black dots are not from melanin pigmentation; it's lipofuscin, as Fontana-Masson and Perl's wre negative.

DISCUSSION

Lipofuscin pigmentation of the gallbladder is a rare histopathological finding. Pseudomelanosis is a descriptive term, rarely encountered in the upper gastrointestinal tract, and it is the result of iron or haemosiderin accretion in the mucosa, which is visualised endoscopically as black or dark brown dots [7,8].

Histologically, this endoscopic image is associated with macrophage's pigment deposition in the lamina propria of the mucosa, which can be haemosiderin, lipofuscin,

and iron sulfide [9]. In the present case, the negative Perl's stain and Fontana-Masson stain, in combination with the positive PAS stain, indicate that the accumulated substance is lipofuscin. Other previously reported cases with no histologically proven melanosis may also bear lipofuscin pigmentation. However, the conducted literature research only led to the identification of a prior report from 1980 that cannot be obtained. As a result, we should acknowledge that this is an exceptionally rare case report of this pathological entity. Moreover, the very detailed, well-documented histopathological examination confirms the aforementioned diagnosis.

The pathogenesis behind pseudomelanosis due to lipofuscin pigmentation is correlated with lipofuscin formation. Lipofuscin, also referred to as the "wear-and-tear pigment", is primarily formed due to oxidative stress and age-related cellular alterations [10]. Its accumulation is linearly associated with lysosomal instability and eventual cellular apoptosis [11]. In our case, chronic inflammation of the gallbladder may have led to lipofuscin pigmentation and potent macrophage activation due to the chronic oxidative stress.

Pseudomelanosis of the lower gastrointestinal tract, also known as melanosis coli, is a common endoscopic finding, mainly encountered during endoscopic procedures, that is primarily correlated with chronic constipation and laxative usage [3]. In general, pseudomelanosis has been associated with many conditions, such as diabetes mellitus, chronic kidney disease, hypertension, and a history of gastrointestinal bleeding [1,12]. Additionally, the utilization of certain medications, including iron supplements, hydralazine, beta-blockers, and thiazide diuretics, seems to also play a role in pseudomelanosis occurrence [1,8,9].

Furthermore, Agrawal et al. (2017) mentioned a possible connection between hyperplastic polyps of the colon and pseudomelanosis [8]; thus, despite the fact that this relation cannot be ruled out, more investigation is needed in this area, and more research should be conducted. In our case, the coincidence of the pseudomelanosis with a replaced right hepatic artery was incidental and should be taken into account as such.

Despite pseudomelanosis due to lipofuscin pigmentation of the gallbladder being a completely benign histopathological entity, it can result in surgical dilemmas. Intraoperatively, this appearance could mimic gangrenous cholecystitis, a possible local carcinoma, a haemorrhagic infarction of the gallbladder, or even a porcelain gallbladder. Given that pseudomelanosis of the gallbladder is rarely reported, the surgeon may convert a laparoscopic operation to an open one due to misinterpretation of the intraoperative findings. In our case, however, the conversion was necessitated by vascular haemorrhage and not the color of the gallbladder. Nevertheless, we should note that, in other cases, the rare gross appearance of the pseudomelanosis may lead to surgical dilemmas and unnecessary conversions.

As gallbladder pseudomelanosis is an existing histopathological entity, surgeons should consider it in any case of a dark-colored gallbladder and not convert the operation relying solely on this finding. Additionally, pathologists and surgeons should build a strong collaboration in identifying such cases. More cases like this should be reported in order to raise awareness of this phenomenon, and more research needs to be conducted in the future to possibly correlate it with chronic ongoing oxidative stress of the gallbladder.

PATIENT PERSPECTIVE

The patient tolerated these procedures well, and despite her prolonged clinical course, is currently in good clinical condition.

CONCLUSION

Lipofuscin pigmentation of the gallbladder is a rare form of pseudomelanosis and is typically an incidental finding on microscopic examination. It is mainly presented as a thickened-wall, dark-colored gallbladder, with black mucosa dots on macroscopic examination. While it has minimal clinical significance, its gross appearance may lead to intraoperative misdiagnosis and expose the patient to surgical risks.

Informed Consent: *In accordance with the Declaration of Helsinki, the patient provided written informed consent for publication of the case report and the accompanying images.*

Conflict of Interest: *The authors declare no conflict of interest.*

REFERENCES

1. Samies J, Shah RN, Pramick M, Unzueta A. Gastric pseudomelanosis: An uncommon finding. Case Rep Gastrointest Med [Internet]. 2022;2022:6290510. Available from: https://pmc.ncbi.nlm.nih.gov/articles/PMC9356900/
2. Lopez G, D'Ercole M, Ferrero S, Croci GA. Duodenal pseudomelanosis: A literature review. Diagnostics (Basel). 2021 Oct;11(11):1974.
3. Kevin PC, Xuchen Z. Pseudomelanosis of the stomach and duodenum. J Clin Gastroenterol Treat [Internet]. 2018;4(2). Available from: https://clinmedjournals.org/articles/jcgt/journal-of-clinical-gastroenterology-and-treatment-jcgt-4-057.php?jid=jcgt

4. Yang N, Ruan M, Jin S. Melanosis coli: A comprehensive review. Gastroenterol Hepatol. 2020 May;43(5):266-72.
5. Kim SY, Choung RS, Kwon BS, Hyun JJ, Jung SW, Koo JS, et al. Small bowel pseudomelanosis associated with oral iron therapy. J Korean Med Sci. 2013 Jul;28(7):1103-6.
6. Tang SJ, Zhang S, Grunes DE. Gastric and duodenal pseudomelanosis: a new insight into its pathogenesis. VideoGIE. 2019 Aug;4(10):467-8.
7. John S, Mehta N, Kaul V, Murthy UK. First reported case of pseudomelanosis gastri. Am J Gastroenterol. 2006;101:1383.
8. Agrawal A, Jain D, Arguello V, Sher D. Hyperplastic polyps and gastroduodenal pseudomelanosis. Case Rep Gastrointest Med [Internet]. 2017 Nov;2017:4270248. Available from: https://pmc.ncbi.nlm.nih.gov/articles/PMC5705894/
9. Wael Mohamed M, Althahabi R, Abubaker F, Sharif O. An incidental finding of gastric and duodenal pseudomelanosis: A case report. Case Rep Gastroenterol. 2022 Apr;16(1):264-9.
10. Katz ML, Robison WG Jr. What is lipofuscin? Defining characteristics and differentiation from other autofluorescent lysosomal storage bodies. Arch Gerontol Geriatr. 2002 May-Jun;34(3):169-84. doi:10.1016/s0167-4943(02)00005-5
11. Brunk UT, Terman A. Lipofuscin: Mechanisms of age-related accumulation and influence on cell function. Free Radic Biol Med. 2002 Sep;33(5):611-9.
12. Giusto DJS. Pseudomelanosis duodeni: Associated with multiple clinical conditions and unpredictable iron stainability - a case series. Endoscopy. 2008 Feb;40(2):165-7.